



MSCZO-605

M.Sc. III Semester

LABORATORY EXERCISE & PRACTICAL ZOOLOGY



**DEPARTMENT OF ZOOLOGY
SCHOOL OF SCIENCES
UTTARAKHAND OPEN UNIVERSITY**

**LABORATORY EXERCISE & PRACTICAL ZOOLOGY
(MSCZO-605)**



**DEPARTMENT OF ZOOLOGY
SCHOOL OF SCIENCES
UTTARAKHAND OPEN UNIVERSITY**

Phone No. 05946-261122, 261123

Toll free No. 18001804025

Fax No. 05946-264232, E. mail info@uou.ac.in

<http://uou.ac.in>

MEMBERS OF THE BOARD OF STUDIES AND PROGRAMME COORDINATOR

Dr. Neera Kapoor

Professor & Head

Department of Zoology,

School of Sciences

IGNOU Maidan Garhi, New Delhi

Dr. S. P. S. Bisht

Professor & Head

Department of Zoology

DSB Campus

Kumaon University Nainital

Dr. A. K. Dobriyal

Professor & Head

Department of Zoology

BGR Campus Pauri

HNB Srinagar Garhwal

Dr. S. S. Kunjwal

Assistant Professor

Department of Zoology

School of Sciences, Uttarakhand Open

University Haldwani, Nainital

Dr. Mukta Joshi

Assistant Professor

Department of Zoology

School of Sciences, UOU, Haldwani, Nainital

PROGRAMME COORDINATOR**Dr. Pravesh Kumar Sehgal**

Associate Professor

Department of Zoology

School of Sciences, UOU, Haldwani, Nainital

UNIT EDITOR AND WRITERS

EDITOR

Prof .Hem C. Tiwari

Retd .principal

H.N.B.Govt PG College ,Khatima

Dr.Manveer Singh Kandari .(Unit No: 1 & 2)

Assistant Professor

Department of Zoology

P.S.B Govt. Degree College, Lambgaon

Tehri Garhwa

Dr. Pravesh Kumar Sehgal. (Unit .4)

Associate Professor

Department of Zoology

School of Sciences, UOU, Haldwani, Nainital

Dr. Sunil Bhandari. (Unit. 5,7 & 8)

Department of Zoology Govt P. G. College,

Gopeshwar, Chamoli.**Unit. 5,7 & 8**

Miss, Poornima Nailwal. (Unit .6)

Department of Zoology, School of Sciences,

Uttarakhand Open University

Dr. Mukta Joshi .(Unit . 3)

Assistant Professor

Department of Zoology

Uttarakhand Open University

Nainital, Uttarakhand

Course Title and Code : LABORATORY EXERCISE & PRACTICAL ZOOLOGY

ISBN :

Copyright : Uttarakhand Open University

Edition : 2022

Published By : Uttarakhand Open University, Haldwani,
Nainital- 263139

COURSE V: LABORATORY EXERCISE & PRACTICAL ZOOLOGY

Course code: MSCZO- 605

Credit:

Unit Number	Block and Unit title	Page Number
	Block I: Vertebrates	
Unit : 1	Microtome of vertebrate tissues	1-42
Unit : 2	Study of the skeleton of Frog	43-130
Unit : 3	Study of permanent slides of Protochordates and chordates	131-179
Unit : 4	Study of the museum specimens of Protochordata and of the different classes of vertebrates.	180-243
	Block II: Biostatistics and Microbiology	
Unit : 5	Exercices on Developmental Biology of Blastula, Gastrula and different stages of chick embryo and Endocrine glands	244-312
Unit : 6	Instrumentation	313-330
Unit : 7	Biostatistics Exercise	331-347
Unit:8	Microbiology Experiments	348-367

UNIT 1 MICROTOME OF VERTEBRATE TISSUES

1.1 Objectives

1.2 Introduction

1.3 Material and method

1.4 Observation

1.5 Results/ Exercise

1.1 OBJECTIVES

After reading this unit, you will be able to:

- Define Microtome and its clinical significance or application of microtome.
- Describe methods or steps involve in section preparing
- Explain the aims of fixation
- Explain the principle of fixation.
- Explain the properties and factors affecting fixation
- Explain types of fixation.
- Explain Fixatives, their types and tissue trimming.
- Explain embedding method.
- Describe different kinds of microtome and section cutting.
- Describe the staining method of a section.
- Writing the result/observation of study or section that was prepared by microtome.

1.2 INTRODUCTION:

A microtome (from the Greek *mikros*, meaning "small", and *temnein*, meaning "to cut") is a cutting instrument used to produce extremely thin slices of plant and animal tissue known as sections. The preparation of section and study of section prepared by microtome is known as microtomy. Important in histopathology, microtomes are used in microscopy, allowing for the preparation of tissue sample for observation under light microscope or under electron microscope to detect various types of histopathological conditions viz, Cancer, abnormal haemopoiesis inside bone marrow, Condition of connective tissues and liquid connective tissue etc.

Microtomes use steel, glass or diamond blades depending upon the tissue being sliced and the required thickness of the sections being cut. Steel blades are used to make histological sections of animal or plant tissues for all types of light microscopy and. Glass blades are used to slice sections for light microscopy and to slice very thin sections for electron microscopy. Industrial grade diamond knives are used to slice hard materials such as bone, teeth and tough plant matter for both light microscopy and for electron microscopy. Diamond blades are also used for slicing thin sections for electron microscopy.

Microtomy is a method for the preparation of thin sections for materials such as bones, minerals and teeth, and an alternative to electro polishing and ion milling. Microtome sections can be made thin enough to section a human hair across its breadth ,with section thickness between 50.00 nm and 100.00µm according to need of histopathologist.

In the beginnings of light microscope development, sections from plants and animals were manually prepared using razor blades. It was found that to observe the structure of the specimen under observation it was important to make clean reproducible cuts on the order of 100 µm, through which light can be transmitted. This allowed for the observation of samples using light microscopes in a transmission mode.

One of the first devices for the preparation of such cuts was invented in 1770 by George Adams, Jr. (1750–1795) and further developed by Alexander Cummings. This device was operated by hand, and the sample hold in a cylinder and sections made from the top of the sample using a hand crank. In 1835, Andrew Prichard developed a table based model which allowed for the vibration to be isolated by affixing the device to the table, separating the operator from the knife.

In 1865, Wilhelm His, a Swiss anatomist, invented the microtome, a mechanical device used to slice thin tissue sections for microscopic examination. He was the author of *Anatomie menschlicher Embryonen*, 3 vol. (1880–85; “Human Embryonic Anatomy”), considered the first accurate and exhaustive study of the development of the human embryo. Nowadays advanced types of microtomes have been invented for histopathological works. are used in microscopy, allowing for the preparation of tissue sample for observation under light microscope or under electron microscope to detect various types of histopathological conditions viz, Cancer, abnormal haemopoiesis inside bone marrow, Condition of connective tissues and liquid connective tissue etc. It is very important tool in Histochemical and Immuno-histochemical the study.

1.3 MATERIAL AND METHODS:

Microtomy involves following sequential steps and Requirement of material is given in each steps:

1.3.1 HISTOLOGICAL PROCESSING:

Histological processing begins with the collection of tissue samples to be studied. In plant histology, pieces of tissues are removed directly from the plant body, whereas in animal histology there are two options: (i) get a sample of an organ or tissue, using biopsy technique from the living animal. In case doubt of cancer by using Fine Needle aspiration Cytology (FNAC) technique ^[1], it is a type of biopsy (figure no-1) in other cases where FNAC biopsy is not possible then punch biopsy technique is used, This biopsy uses a special device to punch a hole in the skin to remove all or most of a lesion deep in the skin. You may need stitches. Many other types biopsies are used for specific purposes.

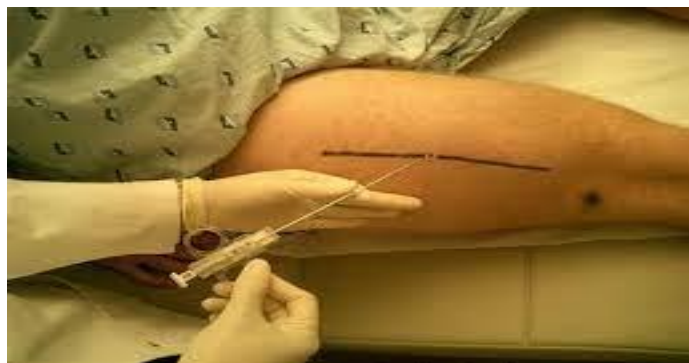

Fig.1.1 biopsy by FNAC (fine needle aspiration of cell)

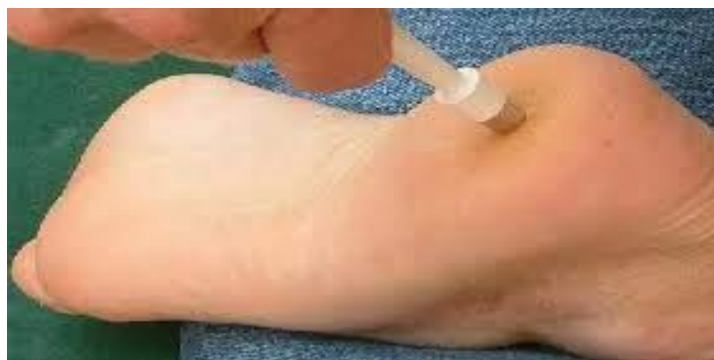

Figure-1.2: Punch Biopsy

Many other types biopsies are used for specific purposes, Image-guided biopsy, Surgical (excision) biopsy, Shave biopsy/punch biopsy, Endoscopic biopsy, Laparoscopic biopsy Bone marrow aspiration and biopsy, Liquid biopsy.

(ii) Necropsy from a dead animal, and then start the histological processing. In any case, samples (or the whole body) are first fixed with solutions known as fixatives and then sample is collected by using specific technique. They keep the features of tissular molecules and structures. After collection of sample and fixation of samples by suitable chemical in glassware (glass jar, beaker etc.) as in figure :3, the information about the sample such as date and time of sample taking, age, weight, name of patient, sex must be written in a slip and stick on container. And maintain a patient register. See in tables given below.

Sample Copy receiving register

Date: 1-07-2022

Acc	Name	Age	Sex	Reg. No.	Type of specimen	Remarks and Diagnosis
01/2022	Mr Akash Singh	37yrs	Male	2234	Lymph node	
02/2022	Smt. Manisha Devi	40 yrs.	Female	22049	Fallopian tube	

1.3.2 FIXATION:

All tissues obtained from living or dead organisms undergo a degradation process. The degradation may be intrinsic, known as autolysis or autodigestion, which is driven by the activity of lytic tissular enzymes. At the same time, an extrinsic degradation process, called putrefaction, is started by microorganisms, mostly bacteria. Moreover, the methodology of the histological processing to study particular features of the tissue may degrade or destroy tissular structures. Fixation preserves morphological and molecular

features of the tissue as similar as possible as they were in the living organism. In other words, fixation decreases both molecular and structural changes in the tissues that may happen during the lab processing. It is like taking a picture of the living tissue, keeping it invariable during the histological processing, and observing this picture with the microscope. A correct interpretation of the features of a tissue depends on a proper fixation. For example, a patient may be wrongly diagnosed as a consequence of a bad fixation that produced alterations of the tissular or cellular structures in the biopsy.

Fixation kills cells and should inhibit cell autolysis, protect tissues against microorganisms, insolubilize molecules that can be lost, as well as prevent retractions or swelling of the tissues that may change the tissue morphology. In addition, fixation must prepare the tissue for performing specific histological techniques, if it is necessary, and keep the tissue features unaltered during the lab processing, such as embedding and staining. Each type have advantages and disadvantages. Chemical fixatives are the most commonly used in the histology labs for light and electron microscopy studies.

There is no universal fixative, neither only one fixation method. Furthermore, several fixatives can be sequentially used in the same fixation process. The selection of the fixative and fixation method depends on the features of the tissue that need to be preserved. For instance, if enzymatic activity must be preserved, fixation should not destroy the catalytic center of the enzyme, but other features of the tissue, like cell morphology, might be modified. The majority of fixatives do not preserve lipids, but these molecules remain in the tissue if solvent solutions are avoided. However, the study of tissue ultra structure involves organic solvents during the embedding in resins, therefore, a fixative that keeps lipids in the tissue is necessary if we want to observe cell membranes. Most fixatives do not preserve carbohydrates, but these molecules remain in the tissue because they are usually attached to proteins. Sometimes, some fixatives can modify molecular components of the tissue so that they are more easily stained by dyes. In any case, there are some features to be considered before the selection of a fixative, and these features are as follows:

DIFFUSION RATE: Fixation has to be quick and the diffusion of fixatives through tissues is a limiting factor. How fast the fixative diffuses through the tissues determines the size of the sample to be processed. So that, the lower diffusion rate, the smaller the

sample. Furthermore, it also affects the total fixation time: higher diffusion means shorter fixation time.

FIXATION RATE: This feature is not a consequence of the fixative diffusion rate, but depends on the chemical nature of the fixative, and influences how long the fixation should last. Keep in mind that this is a chemical fixation.

HARDENING: Tissues are usually hardened by fixatives, which depends on the type of fixative and fixation time.

Osmosis and pH: During fixation, it is important to prevent volume changes in the tissues and cells. These changes may be produced by differences in osmolarity or pH between the tissue and the fixative. Therefore, it is recommended to equal the tissular and fixative osmolarities. It can be accomplished with simple molecules that do not affect the chemical fixation. For instance, 0.9 % NaCl can be used in fixatives for land animals. It is also important to use buffered fixatives with pH similar to that of the tissues.

TEMPERATURE: Fixation at higher temperatures than the animal body temperature, or room temperature for plants, decreases the time of fixation. However, it may produce tissue alterations.

MORDANTS: Some tissular structures are difficult to stain because of their low affinity for dyes. The affinity can be increased by some treatments before the staining. Some fixatives, besides fixation, can chemically modify the tissues and increases the affinity for some dyes. This type of tissue modification is known as mordant effect.

ARTIFACTS: An artifact is whatever alteration introduced in the tissue during the histological process. Fixation is probably the histological process step with more influence in the final quality of tissues. Unlike staining or a bad quality paraffin embedding, fixation is irreversible. Depending on the fixative and fixation method, fixation may produce tissular alterations like swelling, retraction, crystallization of substances, and migration and extraction of molecules. These changes may be because of wrong use or selection of fixative. It is important to realize that what we are observing is an artifact by fixation so that it is not described as a tissular feature. Fixatives may produce retractions of the tissue, which can be tested by monitoring the dimensions of the tissue sample with regular time

Interval before and after the fixation. However, retractions, or swellings, may not affect all tissues of the sample in the same way. There are several methods for fixating tissues that are selected according to the type of fixative, the structure to be fixed, and what we want to observe. Fixation methods can be grouped in two types: physical and chemical methods. Each type has advantages and disadvantages. Chemical fixatives are the most commonly used in the histology labs for light and electron microscopy studies.

(A) PHYSICAL METHODS: Physical fixation is accomplished by either a very quick freezing or by heating the samples at high temperatures. These procedures are used when chemical fixation affects the tissular structures we are interested in, when a very quick fixation is required, or when the techniques or the tissues need physical fixation.

(i) Quick freezing: it is widely used method for preservation of molecular features of tissue. Freezing must be very quick to prevent the formation of large crystals of ice that can penetrate inside the tissue and make changes in tissue. Thus, it is convenient to process sample sizes not larger than 2.00 mm. so that homogeneous freezing can take place, through all the tissue thickness, including the inner parts. A quick freezing is done by dip the samples in isopentane (-170 °C) cooled in liquid nitrogen (-196 °C), or by placing the sample in a metal sheet, which is partially immersed (not the sample) in liquid nitrogen, in dry ice and acetone (-70 °C), or even in liquid helium (-268 °C). If it is possible, before freezing, the samples should be treated and protected by a cryoprotectant substance for minimizing cellular damages. Some ingredients in cryoprotectants solution called ice blockers, which are helping directly to block ice growth. Some examples are polyglycerol, polyvinyl alcohol, X-1000 and Z-1000. Ice blockers are used only in vitrification solutions.

Lyophilization, or freeze-drying, and cryosubstitution are techniques that remove the water (the ice) from frozen samples by sublimation, that is the solid water is converted in gaseous water without going through the liquid water intermediate state. These techniques prevent chemical reactions happening in liquid aqueous environment, allowing a long-lasting Preservation of the tissue. Cryo substitution consists in the slow exchange of ice for a fixative solution. Thus, fixation is done in tissues that did not get degraded because they were frozen.

Heat fixation is not common in histopathology because it heat can damage the tissues. Heat coagulates the proteins and dissolves lipids. However, it is a good fixative method for microorganisms because their morphology is preserved (Gram staining. etc.) and helps in the identification. Nowadays, heating fixation is combined with chemical fixation, for example, samples are immersed in a chemical fixative and micro waved at 50-55 °C. This temperature does not produce artifacts, increases the fixation rate, and decreases the fixation time from hours or days to minutes. Microwave is a good heater because temperature rises quite homogeneously and immediately through the tissue sample. Heating water baths are not recommended because they generates heat gradient between the outer to the inner parts of the tissue sample. It is thought that the increase in the fixation speed by microwave fixation is a consequence of the heat and not of the microwaves. Sometimes microwaves used in later steps of the histological processing, particularly during staining.

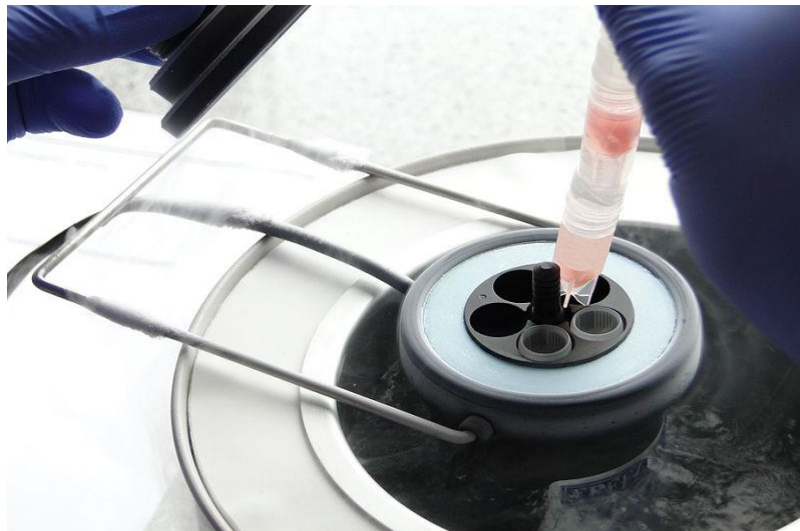

Figure: 1.3 cryopreservation

(B)CHEMICAL METHODS: Chemical methods use aqueous solutions containing fixative substances that form link between tissular molecules and it results in the immobilization of the tissular compounds and prevents degradation of the tissue sample. The higher and lower concentration of chemical fixatives affects tissues both chemically and physically. Retraction, distension, and hardening are common physical effects. There are two common methods for chemical fixation: immersion and perfusion. In any case, the fixative should get to all the regions of the sample as soon as possible.

(i) Immersion: in this method, tissue samples are dip into the fixative solution. It is also used for blood smears or for fixing sections obtained from unfixed frozen samples. Some precautions should be kept in mind when fixing by immersion:

- (a) The thickness of piece of tissue sample should not be larger than 0.50 cm. to allow the fixative enters the deepest part of the sample before the cells start to get deteriorated. The speed of the fixative for reaching the inner parts of the tissue sample depends on the type of fixative and the physical properties of the tissue to be fixed. The size of the sample should be selected according to the speed of the fixative penetration. Samples not larger than 0.20 cm are recommended for slow diffusion fixatives. Tissue features need also to be considered. For example, fixation penetration is faster in loose tissues or samples with large spaces for diffusion.
- (b) The volume of the fixative is recommended to be 10 to 25 times larger than the volume of the sample.
- (c) Osmolarity of the sample and the fixative solution need to be as similar as possible.
- (d) The pH of the fixative solution should be close to the physiological pH, satisfactory fixation occurs between pH 6 and 8. Outside this range, alteration in structure of cell may take place of the sample mean the concentration of fixative should be appropriate.
- (e) For a similar type of sample, fixation time depends on fixative features: diffusion and fixation speed (intensity and speed of making link between proteins or how quick protein clotting take place). The fixation time must not be less or more for a proper fixation, because it may cause artifacts in the tissue sample. A gentle agitation of the sample during fixation is suggested for increasing the surface fixative renewing, which reduces the fixation Time. The common fixative time is 22-24 hrs. For most of the fixatives. If we use formaldehyde for fixation, time may last for 6-7 days.

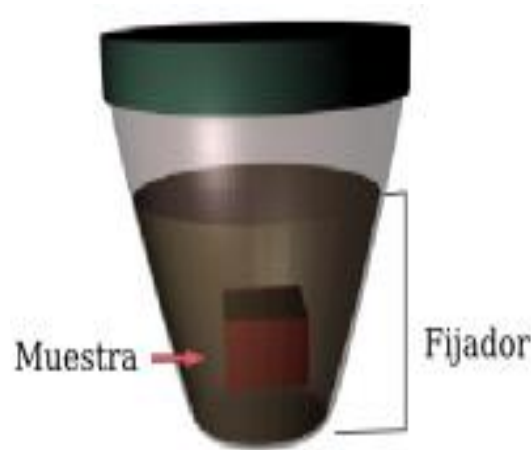


Fig.1.4 Fixation by immersion.

(ii)Perfusion: This method is not always possible, like in many biopsies or in plants. In perfusion fixation, the fixative solution is introduced through the blood vascular system and come to enter all the cells of the tissue via the capillary network (Figure 2). If histopathologist wants to fix a whole animal fixative solution must enters through the left ventricle of the heart. Then, the fixative solution is by a peristaltic Pump through the vascular branches of the arteries coming out from this ventricle. If histopathologist wants the fixative in the lungs, the fixative solution is administrated through the right ventricle of heart. By perfusion, a single organ can be fixed, if fixative solution enters by the aorta that reaches the whole organs (Figure-3). Fixation by perfusion of an organ. By perfusion, the fixative solution reaches every cell of the organ via the vascular system. A peristaltic pump introduce the fixative through the major artery that supplies the organ. All the blood vessels that do not conduct blood toward the organ are closed but the vein net remains opened. Fixation by perfusion is more effective than fixation by immersion because the fixative solution gets in contact with all cells of the perfused the organ very quickly. In this way, the penetration speed of the fixative is not a limiting feature.

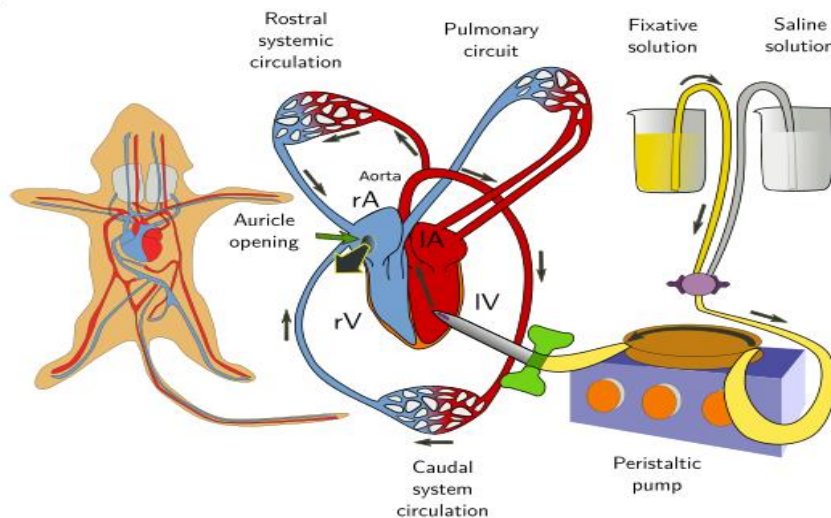


Fig1.5 a fixation of entire animal by perfusion

By perfusion, the fixative solution reaches every cell of the organ via the vascular system. A peristaltic pump introduces the fixative through the major artery that supplies the organ. All the blood vessels that do not conduct blood toward the organ are closed but the vein net remains opened. Fixation by perfusion is more effective than fixation by immersion because the fixative solution gets in contact with all cells of the perfused organ very quickly. In this way, the penetration speed of the fixative is not a limiting feature.

Before the introduction of the fixative in the vascular system, the blood should be removed with an oxygenated saline solution (0.09 %). Otherwise, the fixative may fix blood, coagulate it and thrombosis take place. This may obstruct some parts of the vascular circuit that prevents the fixative solution entering some parts of the sample/organ. As in the fixation by immersion, the pH and osmolarity of the fixative solution, and the fixation time, must be set properly. If a histologist wants to fix an organ then to keep in mind is the pressure of the fixative solution when entering the sample or organ, which should be similar to the blood pressure in the living animal. The fixation pressure can be selected by using peristaltic pumps, and by gravity (rising or decreasing the height of the fixative container from the animal). This is important, because a low pressure may prevent the

Fixative solution to reach every capillary duct of the sample, but a high pressure may break blood vessels and the tissular structure and causes anxiety to animal/patient.

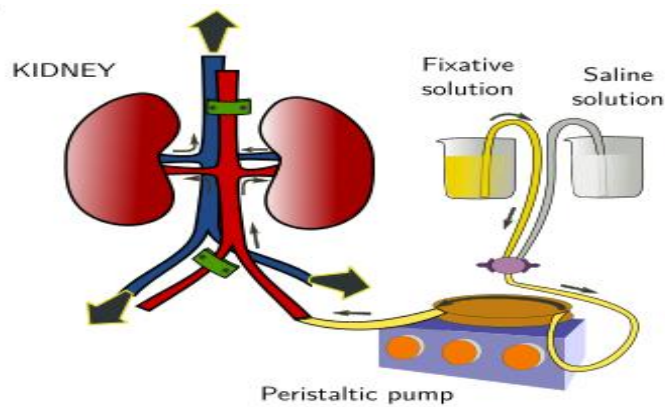


Fig.1.6 Fixation by perfusion of an organ. By perfusion, the fixative solution reaches every cell of the organ via the vascular system. Peristaltic pumps introduce the fixative through the major artery that supplies the organ. All the blood vessels that do not conduct blood toward the organ are closed but the vein net remains opened.

1.3.3 FIXATIVES:

It is a process by which the cells or tissues are fixed in chemical and partly physical state so that they can withstand subsequent treatment with various reagents, with minimal change of morphology and no decomposition.

(A) Principle of fixation: Fixation results in denaturation and coagulation of proteins in the tissues. The fixatives have a property of forming cross bridges between proteins of tissue, thereby forming a gel, keeping everything in their in vivo relation to each other.

(B)Types of fixative: There are many fixatives described in the histological techniques books. In this page, the most common fixatives used in histology labs will be mentioned. These have being proved as the most suitable solutions for a better preservation of the tissue features. Chemical fixatives are the most frequently used, either as a single component or as solutions containing several fixative substances. On the basis of the mechanism of fixation, fixatives can be classified in two types:

(i) Coagulant and cross-linking fixative: Coagulant fixatives remove water from tissues, leading to coagulation and denaturalization of proteins, mostly in the extracellular matrix. Cross-linking fixatives form chemical bonds between molecules of the tissue. Alcoholic based fixatives are coagulants, such as Bouin's and Carnoy's fluids, whereas

formaldehyde and glutaraldehyde are cross-linking fixatives. Sometimes, a mix of the two types of fixatives is used.

(ii) Additive and non-additive. Additive fixatives combine with molecules of the tissue so that the fixative or some of its components, become part of the tissue, and it is present in the following steps of the histological processing. They are mainly cross-linking fixatives and some clotting fixatives (coagulating fixative). Non-additive fixatives, once performed the fixation, are removed from the tissue in later steps of the tissue processing. Alcohol and acetic acid are examples of non-additive fixatives. **Warning!** Most fixative solutions are toxic by inhalation or skin contact, and some of them are carcinogenic. It is important to follow the general and specific safety guidelines given in laboratory manual.

On the basis of constituents fixative are two types: Mono component (single component) and combined or mix fixatives.

(i) Single or Mono-Component Fixatives:

(a) Ethyl alcohol (ethanol), Methanol and Acetone: Ethanol, methanol (methyl alcohol) and acetone do fixation by dehydration and coagulation of proteins, mostly cytoplasmic proteins. The lipids are separated from tissues, but carbohydrates are not affected. Methanol is a better fixative than ethanol because it does not make tissue hardened, and is better preserved. In general, they are good fixatives for small size samples, and preserve proteins, like enzymes, glycoproteins (antibodies) glycogen and some pigments. Thick and thin blood smears and frozen tissue sections from unfixed samples are usually fixed with these fixatives. Since they do both dehydration and fixation at the same time, they can be used for preserving the samples for a long period time before embedding. However, their disadvantage is, they normally produce hardening and retraction in the tissues, which is more evident in larger samples, and lack mordant effect. Acetone is also a

Faster procedure as. It can sometimes be less damaging to epitopes than alcohols, leading to a better histological preservation of the cell.

(b) Picric acid: picric acid, also called 2,4,6-trinitrophenol, pale yellow, odourless crystalline solid that has been used as a military explosive, as a yellow dye, and as an antiseptic. The fixation by picric acid is mediated by the coagulation of proteins produced by the picrate salts. When the fixation time is set properly, picric acid is a good fixative for

preserving the cellular structure, as well as glycogen and lipids. It has mordant effect, which improves the staining in many post-embedding general staining methods. It is a good practice to wash thoroughly the samples to remove the picric acid before paraffin embedding because picric acid makes difficult the infiltration of paraffin. Bouin's fluid is a widely used fixative containing picric acid. Normally, 3.10 % to 14.50% of a saturated solution of picric acid is combined with other fixatives. Picric acid, also called 2,4,6-trinitrophenol, pale yellow, odourless crystalline solid that has been used as a military explosive, as a yellow dye, and as an antiseptic.

(c) Formaldehyde: It is a widely used fixative because it provides a very good structural preservation for tissues, preserved tissues during long periods of time, with small tissue retractions, is compatible with most techniques and histological staining procedures, including immunostaining and molecular biological techniques and *in situ* hybridization of mRNA with DNA especially in reverse transcription study. Formaldehyde bonds to functional groups of proteins and renders hemiacetal groups. This makes most enzymes non-functional, preventing the degradation of tissues by hydrolase enzymes. Formaldehyde bonds to several types of groups like amino, sulphhydryl, guanidyl, and aliphatic hydroxyl groups. The reaction produces hydroxymethyl compounds, which react with other groups, either located in the same or in a different protein, to form methylene linkages. Formaldehyde is a well-preserved for lipids, which is improved by the addition of calcium to the fixative solution because calcium inhibits the solubility of phospholipids, and it does not react with carbohydrates.

The paraformaldehyde fixation time is 24 to 50 h, although it can last for 1 or 2 weeks. If the tissue is intended for immunohistochemistry, a 12 to 24 h fixation at 4 °C is recommended. Long-lasting fixations harden the tissue and may cause nucleic acid instability. The fixative can be partially removed from the tissue by long washes. Formaldehyde is commonly used in buffered and isotonic solutions at a concentration of 4.0-5.0 %. Formaldehyde is usually prepared from the solid compound paraformaldehyde. Examples of fixatives with formaldehyde: buffered formaldehyde, Bouin, FAA (formaldehyde, acetic acid, alcohol) , PLP [paraformaldehyde, lysine, (ortho and meta periodic acid)].

(d) Osmium tetroxide: Osmium tetroxide was one of the first fixatives in histology, used since 1865. In water solution, it does not penetrate deep in tissue blocks, and samples larger than 0.5 to 1 mm are not recommended. Osmium tetroxide can be used in solution and as a

gaseous fixative because it is a volatile molecule. It does not produce artifacts, but renders fragile samples. Chemically, it forms bridges between unsaturated fatty acid of membranous lipids. Thus, cell membranes become insoluble, dark and electron dense (that is, electron can cross them). Osmium tetroxide is commonly used for electron microscopic studies *viz*: TEM and SEM (transmission electron microscopy & Scanning electron microscopy) because cell membranes are well-preserved and dark, so that they become easily observable. At all types of light microscopy, it is useful for studying unsaturated lipid deposits, myelin tracts, and it is needed for silver impregnation procedures like Golgi apparatus impregnation method. Osmium tetra oxide is rarely combined with dyes because it is a strong oxidizing agent and prevents binding of anionic dyes to the tissue. Currently, osmium tetroxide is mostly used after formaldehyde and glutaraldehyde fixation, and before dehydration and embedding for electron microscopy (TEM and SEM).

(e) Glutaraldehyde: Glutaraldehyde is a widely used fixative. When it is in solution, glutaraldehyde forms dimers and trimers. Aldehyde groups located inside the polymerized molecule react with the amino acids amino groups, linking proteins by making molecular bridges. The outer aldehyde groups, however, remain unbound, and should be blocked to prevent false positives, for example when adding proteins like immunoglobulins during immunohistochemistry, or to prevent reactions with aldehyde groups during PAS histochemistry (Periodic acid–Schiff). Therefore, it is a good practice to wash out glutaraldehyde free groups, usually done with a pre-treatment in 1 % sodium borohydride. The penetration speed of glutaraldehyde is slow, so that fixation by perfusion is recommended. 0.50 % to 3.50 % of glutaraldehyde is widely used. It can preserve the ultrastructure of tissues much better than other fixatives, and that is why it is a preferred fixative for electron microscopy studies (TEM and SEM). However, it is not recommended for paraffin embedding because sections become more difficult to obtain. The low diffusion rate may cause tissular retractions. Glutaraldehyde is used with isosmotic buffered solutions, usually combined with formaldehyde. Many types of aldehydes have been used as fixatives in histology, but they are no longer included in the more common histological procedures. For example, chloride hydrate was used for the fixation of the nervous system, acrolein (very toxic) for electron microscopy (TEM and SEM), and glyoxal as a general fixative.

(ii) Combined or Mix Fixatives:

Nowadays, most fixation procedures include several fixatives, either together in solution or one by one in successive fixation steps. In this way, the advantages of each fixative can be applied to the same sample, and some disadvantages can be balanced. There are many fixation procedures, both in their components, the proportion of each of them, and in the way they are used, depending on the sample and on what we want to observe. Together with the fixative compounds, there are other components in the fixative solution for adjusting other features like osmolarity and pH. For example, most fixatives are dissolved in buffered isosmotic solutions with a neutral pH so that tissue structures are not much affected. Other substances are also added with different purposes. Thus, ethylene glycol allows freezing the sample and get frozen sections, preventing the protein diffusion as well.

The followings are some of the most common fixative mixtures. They show a combination of properties suitable for the observation of a large variety of tissues and staining procedures.

(a) Bouin's fluid: Bouin's is a solution of picric acid, formaldehyde and acetic acid, frequently used for samples paraffin embedding. The sections can be processed for a wide number of staining techniques. It is very useful for soft and embryonic tissues. It preserves well the nuclei of nucleolus and glycogen. If the fixation is by immersion, fixation time does not need to exceed 45.00-48.00hrs. After that, samples can be kept in 70° ethyl alcohol for a long period of time. However, it is not recommended, for nephric tissue or mitochondrial fixation. Before paraffin embedding, it is advisable that remove the picric

acid from the sample by long washes in 70°ethyl alcohol, because picric acid blocks the paraffin diffusion, which can delay or interfere with a good embedding and spoils staining.

(b) Clark solution: Clarke solution contains ethanol and acetic acid at a 3:1 proportion. It was one of the first fixatives used, good for paraffin embedding.

(c) Carnoy's solution: Carnoy's solution contains ethanol 100°, chloroform, and acetic acid. Carnoy's solution is an ideal fixative for glycogen, simple carbohydrates, and fibrous

proteins. It also provides a good fixation of nucleic acids (DNA and RNA) and ribosomes, although the nuclear structure is distorted in some extent. The Nissl's granules of cytone and dendrites of nerve fiber are clearly visible after fixation with Carnoy's solution. However, in some cases it may produce tissue retractions.

(d)Glutaradehyde Osmium tetraoxide: These fixatives may not be used at the same time, but consecutively. Samples of tissue for electron microscopy (TEM and SEM) are initially fixed with a solution containing glutaraldehyde (1.0 – 4.0 %) and paraformaldehyde (2 - 4 %), and later by osmium tetra oxide (1.0 %). This combination is good for almost all tissue structures, particularly membranes. It is important because the procedure for electron microscopy usually involves dehydration in organic solvents and polymerization of resins at 60 °C, during which cellular structures must be preserved.

(e)Zinc chloride and zinc sulphate: Zinc chloride was used long ago as a single fixative, but it later became a component of several fixative solutions. Currently, zinc salts are combined with paraformaldehyde. Zinc chloride helps fixation and preserves tissular antigens for immunohistochemical techniques by minimizing the antigen masking effect of paraformaldehyde. Mercury salts, which were used in the first fixative solutions, have been replaced by zinc salts. Fixatives containing zinc salts are not prepared in phosphate buffer, as it is common for other fixative substances. Furthermore, after fixation, zinc has to be removed from sample with thorough washes in distilled water.

(f)Acetic acid: Acetic acid does not perform a direct fixation, but a change of the colloidal state of proteins. Acetic acid is used at a concentration of 1 - 5 %. It is a very good fixative for nucleic acids and nucleoproteins. As drawbacks, acetic acid destroys mitochondria and

Does not fix well membranes and cytoplasm. It is commonly combined with other fixatives like in Bouin (formaldehyde + acetic acid + picric acid) and FAA (formaldehyde + acetic acid + ethanol). In some fixative solutions, it is used to counteract the artifacts that may cause ethanol or picric acid. Advantage and disadvantages of different types of fixative is given in table

	Fixative	Effect	Advantages	Disadvantage
Single component or cross linker fixative	Formaldehyde	Cross link proteins through free amino group	Preserve cellular morphology and ideal for already fluorescence proteins	Antigen might be cross linked
	Glutaraldehyde	Effect is similar that of formaldehyde	Advantage is similar that of formaldehyde	Antigens might be crosslinked and gives off a high level of fluorescence.
Organic Solvents	Methanol	Dehydrogenation and protein precipitation.	Cellular structures is well preserved and is a faster procedure.	strong negative effect on epitopes, is not suitable for fluorescent proteins. Soluble compounds and lipid components are lost.
	Acetone	Similar to methanol	Epitopes are well preserved and is a faster procedure.	Not appropriate for fluorescent proteins. Soluble compounds and lipids are lost

1.3.3 DEHYDRATION, TRIMMING AND EMBEDDING:

(A)Dehydration: After fixing the sample tissue, next step is dehydration. The hard tissues should be decalcified by using suitable acids. Dehydration is the process of removing water from fixed tissue. Some common dehydration agents are ethyl alcohol, methyl alcohol, butyl and isopropyl alcohol.

Alcohol Method: it is applicable for ethyl, methyl, butyl and isopropyl alcohol. The tissues are passed through a series of progressively more concentrated alcohol baths. Concentration of first alcohol bath depends on the fixative and size and type of the tissue, e.g. soft and delicate tissue needs lower concentration of alcohol and small interval between two strengths of alcohol. Usually 70-75% alcohol is used as the first solution and 100% as the last solution. After about 40 minutes tissues have passed through the first change of alcohol, it is discarded and all the other changes are brought one step lower. Absolute alcohol at the end is always fresh.

Use of copper sulphate(CuSO_4 in final alcohol: A layer of anhydrous CuSO_4 is placed at the bottom of a dehydrating container and is covered with 2-3 filter paper of appropriate size to prevent staining of the tissue. Anhydrous CuSO_4 removes water from alcohol as it in turn removes it from tissues.

(B)Trimming. After dehydration the next step is trimming. Trimming is cutting a fixed tissue or organ to create a flat surface with correct orientation. You can do this yourself with training and a few basic supplies (cutting board, forceps, and single edge razor blade). Trimming of Cerebro spinal fluid (CSF) connective tissues and bone marrow should not be done.

(C)Embedding: After trimming the embedding should be done. Embedding is the process in which the tissues or the specimens are enclosed in a mass of the embedding medium using a mould. Since the tissue blocks are very thin in thickness they need a supporting medium in which the tissue blocks are embedded. This supporting medium is called embedding medium. The choice of embedding media depends upon type of microscope and type of tissue, eg. hard tissue like bone are subjected to decalcification but soft tissue like liver biopsy Paraffin wax with a higher melting point (56 to 62°C) is used for embedding. The molten wax is filtered inside the oven through a coarse filter paper into another container. This will protect the knife edge.

(i) Paraffin media and its additives: Various substances can be added to paraffin wax in order to modify its consistency and melting point to improve the efficiency during microscopy. Additives increase the hardness of blocks. This helps in cutting thinner sections at higher temperature. Stickiness of the medium is increased so better ribbons can be obtained. However if larger quantities of additives are added, undesirable side effects may be seen. Commonly used additives:

- **Ceresin** – It is hard white substance derived from mineral ozokerite. Its melting point is between 61 to 70° C. The addition of 0.3-0.5% is sufficient to reduce the crystalline structure of paraffin wax.
- **Bees' wax** - It is yellow substance with melting point of 64°C. This also reduces the crystalline structure of the paraffin wax and improves the ribbon quality.
- **Bayberry wax** - It is a vegetable wax and present in the peel of bayberry. It is extracted from the peel of the fruit. Its melting point is 45° C.

(ii) Other Types of Embedding Media:

- **Carbowax:** It is a water soluble wax. Therefore tissues are directly transferred to water soluble wax after fixation and washing.
- **Methacrylate:** It is easily miscible with alcohol and gives a clear and hard block when polymerised. Polymerization takes place in the presence of a catalyst. Any trace of water causes uneven polymerization and formation of bubbles in the block around the tissue. z **Epoxy Resin (Araldite):** Epoxy polymers of araldite is used in higher resolution work and to see greater details. Epoxy resins are used for electron microscopy. Epoxy polymers of araldite differ from methacrylate in that they are crosslinked causing the cured solid block of araldite to be insoluble in any solvent. Longer filtration is required because the viscosity of resin is greater than methacrylate. For electron microscopy araldite is obtained as casting resin CY212, a hardener DDSA and an amine accelerator, DMP (ditrimethylamino methyl phenol). Blocks are suitably cured before sectioning for 48 to 60 hours at 60°C. z **Agar embedding:** It is mainly used in double embedding. Multiple fragments and friable tissue may be impregnated in one block when sectioning on the cryostat. Another use of agar embedding is for FNAC specimens.

- **Celloidin media:** Celloidin is a purified form of nitrocellulose. It is used for cutting hard tissues. z **Gelatin:** Its melting point is less than the melting point of agar. Gelatin may be used when frozen sections are required on friable and necrotic tissues

(iii) Devices for Tissue Embedding: Devices designed specifically for tissue embedding are available for laboratories in need of such equipment. These machines vary in size and design depending on the number of samples they are designed to process. Some are designed for specific embedding media, including proprietary compounds intended for specific kinds of histopathology applications. Tissue embedding equipment tends to be expensive. Manufacturers have sales representatives who can provide information and advice when a lab is selecting new or replacement equipment. Tissue embedding machine all the blocking steps can be performed with the help of tissue embedding machine. The working method of machine is provided in lab manual that is provided by the company. The machine can be fully automates, semi automated or fully manual (hand operated). Nowadays modern machine are available which perform trimming and embedding automatically. The embedding machine contains the following features. If Machine is not available than we can perform trimming after fixation and after that embedding will be done.

If embedding machine is not available we can do embedding by hand or manually. The manual method is given bellow. Manual method is not used in hospitals.

(a) Types of Moulds: if embedding machine is not available than variety of moulds are used for embedding manually. These are followings types:



Fig: 1.7 Embedding machine fully automated

- **LEUCKHARD embedding moulds (L mould):** Most of the laboratories use L moulds. L moulds are made up of metal, easy to procure, reusable and may be adjusted to make different size of blocks. One limb of the "L" is longer than the other. The two "Ls" are jointed to form a sides of the rectangular box that act as a cast to make the mould (figure: 2a).



Fig: 1.8 leuckhard embedding moulds

- **Plastic moulds:** Most of the laboratories use plastic embedding rings now. These are relatively inexpensive, convenient and support the block during sectioning and are designed to fit it on the microtome. This eliminates the step of mounting or attaching the block on a holder (metal or wooden holder).



Fig: 1.9 plastic moulds

(b)Procedure of embedding: 1. Open the tissue cassette or mold, check requisition form entry to ensure the correct number of tissue pieces is present. Select the mould; there should be sufficient space for the tissue with allowance for at least a 2.00 mm surrounding margin of

wax. LEUCKHART method is very traditional embedding method. The L moulds are adjusted according to the shape and size of the tissue. Glycerine may be applied to the L pieces and also to the metal or glass plate on which the moulds are placed for embedding so that tissue will not stick on L piece and glass plate. Simple glossed wall or floor tiles may also be used in place of glass plate.

3. Fill the mould with paraffin wax gently.
4. Using warm and cleaned forceps select the tissue, taking care that it does not cool in the air; at the same time.
5. Place the tissue in the mould according to the side to be sectioned. This side should be facing down against the mould. A small amount of pressure may be used in order to have more even embedding.
6. Chill the mould on the cold plate, orienting the tissue and firming it into the wax with warmed forceps. This ensures that the correct orientation is maintained and the tissue surface to be sectioned is kept flat.
7. Insert the identifying label or place the labeled embedding ring or cassette base onto the mould.
8. Add more paraffin into the mould to fill the cassette and mould.
9. Cool the block on the cold plate.
10. Remove the block from the mould.
11. Cross check block, label and requisition form.

Placement (orientation) of different tissue - During embedding the placement of tissue is important. Correct orientation of tissue in a mould is the most important step in embedding. Incorrect placement of tissues may result in diagnostically important tissue elements being missed or damaged during microtomy. During embedding it is important to orient the tissue in a way that will provide the best information to the pathologist. At the time of grossing, mark with India ink may be put on the side of the tissue opposite that to be cut. The embedding should be done according to the type of tissue. The requisition form should always be read during embedding for proper orientation.

Some general precautions are as follows:

- Elongate tissues are placed diagonally across the block.
- Tubular and walled specimens such as vas deferens, cysts and gastrointestinal tissues are embedded so as to provide transverse sections showing all tissue layers.
- Tissues with an epithelial surface such as skin, are embedded to provide sections in a plane at right angles to the surface (hairy or keratinized epithelia are oriented to face the knife diagonally).
- Multiple tissue pieces are aligned across the long axis of the mould, and not placed at random.

Incorrect placement of tissues may result in diagnostically important tissue elements being missed or damaged during microtomy. In circumstances where precise orientation is essential, tissue should be marked or agar double embedded. Usually tissues are embedded with the surface to be cut facing down in the mould.

1.3.4 SECTIONING:

After embedding the tissue sample is called block. Next step of microtomy is sectioning after sectioning fine ribbons are obtained. The sectioning method is depend on microtome apparatus that we are going to use for making the section and hardness of tissue. However, only very thin samples can be readily observed with microscopes, otherwise there would be diffusion and poor penetration of light for light microscopy, or electrons for transmission electron microscopy. Because of this, it is necessary to obtain sections from tissues we want to study. Section thickness may rank from hundreds of micrometers (μm) to a few nanometers (nm). Some tissues, such as plant tissues, may be studied in thick sections (hundreds of μm). Blood cells or cell cultures are observed without sectioning because they can be extended onto a slide and form one cell-thick layer. Following types of microtome are used in histopathology.

(A)Types of microtome apparatus: Following types of microtome are used in histopathology.

(i)Sledge Microtome: A sledge microtome is a device where the sample is placed into a fixed holder (shuttle), which then moves backwards and forwards across a knife. Modern sledge microtomes have the sled placed upon a linear bearing, a design that allows the microtome to readily cut many coarse sections. By adjusting the angles between the sample

and the microtome knife, the pressure applied to the sample during the cut can be reduced. Typical applications for this design of microtome are of the preparation of large samples, such as those embedded in paraffin for biological preparations. Typical cut thickness achievable on a sledge microtome is between 1 and 60 μm .



fig: 1.10 sledge microtome

(ii) **Rotary Microtome:** This instrument is a common microtome design. This device operates with a staged rotary action such that the actual cutting is part of the rotary motion (figure-2). In a rotary microtome, the knife is typically fixed in a vertical position. In the figure 2.1, the principle of the cut is explained. Through the motion of the sample holder, the sample is cut by the knife position 1 to position 2, at which point the fresh section remains on the knife. At the highest point of the rotary motion, the sample holder is advanced by the same thickness as the section that is to be made, allowing the next section to be made.

The flywheel in many microtomes can be operated by hand. This has the advantage that a clean cut can be made, as the relatively large mass of the flywheel prevents the sample from being stopped during the sample cut. The flywheel in newer models is often integrated inside the microtome casing. The typical cut thickness for a rotary microtome is between 1 and 60 μm . For hard materials, such as a sample embedded in a synthetic resin, this design of microtome can allow good "semi-thin" sections with a thickness of as low as 0.5 μm .

(iii) **Cryomicrotome:** For the cutting of frozen samples, many rotary microtomes can be adapted to cut in a liquid-nitrogen chamber, in a so-called cryomicrotome setup. The reduced

temperature allows the hardness of the sample to be increased, such as by undergoing a glass transition, which allows the preparation of semi-thin samples. However the sample temperature and the knife temperature must be controlled in order to optimize the resultant sample thickness.



Fig: 1.11 Rotary microtome

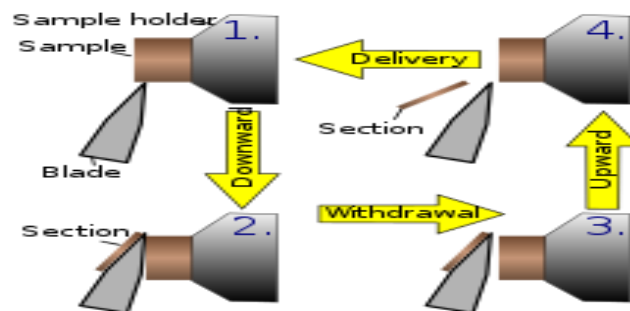


Fig: 1.12 Parts of rotary microtome



Figure: 1.13 Cryomicrotome

(iv) **Ultramicrotome:** Ultramicrotomy is a method for cutting specimens into extremely thin slices, called ultra-thin sections, that can be studied and documented at different magnifications in a transmission electron microscope (TEM). It is used mostly for biological specimens, but sections of plastics and soft metals can also be prepared. Sections must be very thin because the 50 to 125 kV electrons of the standard electron microscope cannot pass through biological material much thicker than 150 nm. For best resolutions, sections should be from 30 to 60 nm. This is roughly the equivalent to splitting a 0.1 mm-thick human hair into 2,000 slices along its diameter, or cutting a single red blood cell into 100 slices.

Ultramicrotomy process: Ultra-thin sections of specimens are cut using a specialized instrument called an "ultramicrotome". The ultramicrotome is fitted with either a diamond knife, for most biological ultra-thin sectioning, or a glass knife, often used for initial cuts. There are numerous other pieces of equipment involved in the ultramicrotomy process. Before selecting an area of the specimen block to be ultra-thin sectioned, the technician examines semithin or "thick" sections range from 0.5 to 2 μm . These thick sections are also known as *survey sections* and are viewed under a light microscope to determine whether the right area of the specimen is in a position for thin sectioning. "Ultra-thin" sections from 50 to 100 nm thick are able to be viewed in the TEM.

Tissue sections obtained by ultramicrotomy are compressed by the cutting force of the knife. In addition, interference microscopy of the cut surface of the blocks reveals that the sections are often not flat. With Epon or Vestopal as embedding medium the ridges and valleys usually do not exceed 0.5 μm in height, i.e., 5–10 times the thickness of ordinary sections.

A small sample is taken from the specimen to be investigated. Specimens may be from biological matter, like animal or plant tissue, or from inorganic material such as rock, metal, magnetic tape, plastic, film, etc. The sample block is first trimmed to create a block face 1 mm by 1 mm in size. "Thick" sections (1 μm) are taken to be looked at on an optical microscope. An area is chosen to be sectioned for TEM and the block face is re-trimmed to a size no larger than 0.7 mm on a side. Block faces usually have a square, trapezoidal, rectangular, or triangular shape. Finally, thin sections are cut with a glass or diamond knife using an ultramicrotome and the sections are left floating on water that is held in a boat or trough. The sections are then retrieved from the water surface and mounted on a copper, nickel, gold, or other metal grid. Ideal section thickness for transmission electron

Microscopy with accelerating voltages between 50kV and 120kV is about 30–100 nm. Nowadays the modern is widely used in histopathology.



Figure: 1.14 Cryo ultramicrotome

(iv) Vibrating or Vibratome: The vibrating microtome operates by cutting using a vibrating blade, allowing the resultant cut to be made with less pressure than would be required for a stationary blade. The vibrating microtome is usually used for difficult biological samples. The cut thickness is usually around 30–500 μm for live tissue and 10–500 μm for fixed tissue.

A variation on the vibrating microtome is the Compresstome microtome. The Compresstome uses a specimen syringe or "lipstick-like" tube to hold the tissue. The tissue specimen is completely embedded in agarose (a polysaccharide), and the tissue is slowly and gently pressed out of the tube for the vibrating blade to cut. The device operates in the following way: the end of the specimen tube where the tissue emerges is slightly narrower than the loading end, which allows gentle "compression" of the tissue as it comes out of the tube. The slight compression prevents shearing, uneven cutting, and vibration artifacts from forming. Note that the compression technology does not damage or affect the tissue being sectioned.

There are several advantages of the Compresstome microtome: (a) the agarose embedding provides stability to the entire specimen on all sides, which prevents uneven slicing or shearing of tissue; (b) the compression technology gently compresses tissue for even cutting, so that the blade doesn't push against the tissue; (c) faster sectioning than most vibrating microtomes; and (d) it cuts tissue from older or more mature animals well to provide healthier tissues.

(v) Saw microtome: The saw microtome is especially for hard materials such as teeth or bones. The microtome of this type has a recessed rotating saw, which slices through the sample. The minimal cut thickness is approximately 30 μm and can be made for comparatively large samples.^[11]

(vi) Laser microtome: The laser microtome is an instrument for contact-free slicing.^[18] Prior preparation of the sample through embedding, freezing or chemical fixation is not required and thereby minimizing the artifacts from preparation methods. Alternately laser microtome can also be used for very hard materials, such as bones or teeth, as well as some ceramics. The achievable thickness of section is between 10 and 100 μm .

This device uses infrared laser for section cutting. As the laser emits infra red radiation, the laser can interact with biological materials. Through sharp focusing of the probe within the sample, a focal point of very high intensity, up to TW/cm^2 , can be achieved. Through the non-linear interaction of the optical penetration in the focal region a material separation in a process known as photo-disruption is introduced. By limiting the laser pulse durations to the femto second range, the energy expended at the target region is precisely controlled, thereby limiting the interaction zone of the cut to under a micrometre. External to this zone the ultra-short beam application time introduces minimal to no thermal damage to the remainder of the sample. The laser radiation is directed onto a fast scanning mirror-based optical system, which allows three-dimensional positioning of the beam crossover, whilst allowing beam traversal to the desired region of interest. The combination of high power with a high raster rate allows the scanner to cut large areas of sample in a short time. By using laser microtome the laser-microdissection of internal region of tissues, cellular structures, and other types of small features is also possible.

(B) Knives: The selection of microtome knife blade profile depends upon the material and preparation of the samples, as well as the final sample requirements (e.g. cut thickness and quality), which falls under the categories of planar concave, wedge shaped or chisel shaped.

(B) Method of Sectioning: Here we are going to learn that how we prepare the ribbons from block by using rotary microtome. It included two steps: (i) section cutting and (ii) Pack up.



Fig.1.15 Diamond knife

Knife profiles

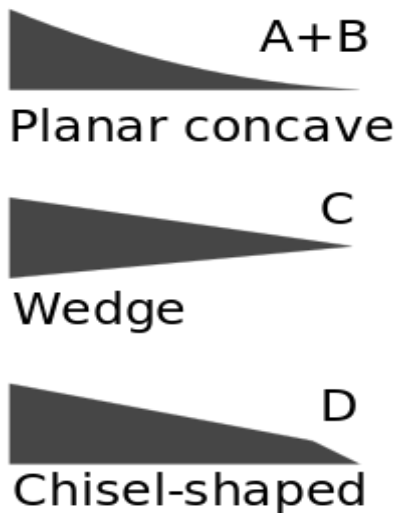


Fig.1.16: Various shapes of knives

(B)Method of Sectioning: Here we are going to learn that how we prepare the ribbons from block by using rotary microtome. It included two steps: (i) section cutting and (ii) Pack up.

(i) Section cutting

- Set the desired section thickness using the thickness setting knob at the front of the microtome on the right and check the value in the display window.
- Use a different area of the cutting edge (blade) for trimming than for sectioning.

- Use caution when repositioning blades and always ensure they are clamped back in place. For sectioning, turn the handwheel (right hand side) evenly in a clockwise direction. Repeat until desired number of sections is cut.
- Pick up the sections and mount them on microscope slides by preferred method. Always rotate the handwheel at a uniform speed. The rotation speed of the handwheel must be adapted to suit the hardness of the specimen. For harder specimens, use a slower speed.

(b)Pack up:

- Move the specimen clamp to the upper end position and lock the handwheel
- Remove the knife from the knife holder clean it and put it back in the knife case.
- Remove knife holder base and knife holder and clean them.
- Remove the specimen from the specimen clamp.
- Remove section waste with a dry paint brush.
- Remove specimen clamp and clean separately.

1.3.5 STAINING:

The prepared sections (ribbons) are colorless and different components of tissue can't be appreciated. Staining them by different colored dyes, having affinities of specific components of tissues, makes identifiable and study of their morphology possible. There are several stains for staining the tissue but Hematoxylin and Eosin is the most frequently used stain in histology.

(A) Hematoxylin and its properties: It is extracted from the bark of a tree, "hematoxylum campechianum". The hematoxylin which we buy is extracted from this bloodwood tree. To obtain the bark of freshly logged tree is chipped off, then boil the chips in water. An orange red solution is obtained, which turns yellow, then black on cooling. The water is evaporated leaving crude hematoxylin. Further purification is done. Solutions of the dye should be oxidized to retain its staining ability longer. The dye may be oxidized by exposure to the natural light for 3-4 months. Chemical oxidation is done by using either sodium iodate or mercuric oxide. The chemical oxidation changes the dye almost instantaneously but the product does not have shelf life. Sodium iodate is widely used oxidizing agent (0.20 gm

Oxidizes 1.0 gm hematoxylin). Hematoxylin has no coloring properties. For nuclear staining it is necessary to oxidize the hematoxylin to hematin which is a weak anionic purple dye. Anionic hematin will have no affinity for the nucleic acids of nuclei. Hence a metallic salt or mordant is combined with hematoxylin so that a positive charge to the dye is obtained by metallic action. Thus the cationic dye –metal complex will bind to the anionic nuclear chromatin. In order for hematin to attach itself to the nuclear components within a cell, a mordant must be present. A mordant is a chemical that serves as a link between the dye and the substrate. The result is an insoluble compound that helps adhere the dye to the cells. The most useful mordants for hematoxylin are salts of aluminum, iron, tungsten, and occasionally lead. These are classified respectively as:

- Alum hematoxylin
- Iron hematoxylin
- Tungsten hematoxylin
- Lead hematoxylin

The type of mordant used influences the type of tissue components stained and the final color. Most mordants are combined into the staining solution, although a pre-treatment with the mordant is required with some hematoxylin stains ^[21]. Hematoxylin has following properties:

- Hematoxylin has no staining property.
- Hematin with mordant such as ammonium or potassium alum forms reservoir which functions as cationic dye and stains anionic tissue components.
- Hematin in an aqueous solution can be acidic or an alkaline dye depending.
- Hematin has affinity for several tissues with an appropriate mordant or it is multipurpose.

Progressive staining - When tissue is left in the stain just long enough to reach the proper end point. The slides have to be examined at different interval to find out when the staining is optimum.

Regressive staining - In this method the tissue is over stained and then destained (differentiate) until the proper endpoint is reached. Harris hematoxylin is a regressive stain;

the over staining is removed by acid – alcohol this is called is called differentiation. The hematoxylin alum gives a reddish hue to the tissues because of acidic pH. To convert this colour to the final blue, alkaline pH is required. It is done either by tap water or by ammonium hydroxide solution.

Preparation of Mayer’s hematoxylin: For the preparation of Mayer’s hematoxylin following ingredients are required:

Hematoxylin	1.00ogm.
Distilled Water	1000ml.
Ammonium alum	50.00gm S
Sodium iodates	0.20gm.
Citric acid (reduces pH)	1.00gm
Chloral hydrate (preservative)	50.00gm

Weigh accurately 1.00 gm hematoxylin and dissolved in distilled 1000 ml distilled water using gentle heat. Then add 50.00gm Ammonium alum and dissolve it. Then Sodium iodate 0.20, Citric acid 1.00gm and chloral hydrate 50.00 gm are added respectively: allow the solution for cooling.

(B) Eosin: Eosin is used as a counter stain that stains the cytoplasm gives rose color. The intensity of the eosin is individual choice. The most widely used eosin is “eosin Y”. The “Y” stands for yellowish. It is available in water soluble or alcohol soluble form. Most laboratories use the water soluble form of eosin Y. Here the methods is given for alcohol and water solution of eosin Y.

Water soluble Eosin Y:

Eosin Y (water soluble)	1.0gm
Distilled water	100ml

Alcoholic eosin Y:

Eosin Y (1% solution)	50.00ml
Phloxine B (1% W/V)	5.0 ml
Ethanol	390.0 ml
Acetic acid, glacial	4.0 ml

Method for preparation of Water soluble and Alcoholic eosin Y stain:

Weigh accurately 1.00gm Eosin Y by using electronic balance and dissolve it in 100 ml. distilled water with the help of glass stirrer. It is water soluble eosin Y stain and ready to use.

Take 50 ml. of eosin water soluble stain and add 5.00 ml Phloxine B solution (1%) in it. Now shake it gently now add 390 ml ethanol in it. Now add 4.00 ml glacial acetic acid with the help of graduated pipette. It is Alcoholic eosin Y stain and ready to use.

(C) Staining method of hematoxylin:

1. Deparaffinize sections in xylene, 10-20 minutes. Filter Hematoxylin.
2. Rehydrate sections: 100% alcohol for 1-2 minutes 95% alcohol for 1-2 minutes
3. Rinse in tap water
4. Rinse in distilled water
5. Stain with Hematoxylin for 3-5 minutes
6. Wash in tap water
7. Differentiate section with 1% HCl in 70% alcohol 1-2 dips and check under microscope. If necessary, return slides to HCl for further differentiation.
8. Wash slides in running tap water for 15-20 minutes
9. Stain slides in Eosin for 2-4 minutes.
10. Dehydration and Differentiation: 95% alcohol 5-6 dips 100% alcohol 5-6 dips.
11. Clear slides in Xylene 2 times

12. Mount slides with mounting media (Permount or DPX)

Note: 1. before the staining the section should be dry

2. Hematoxylin and Eosin are regressive stain in which a tissue is over-stained and then excess dye is removed to obtain desired result.

3. Filtration of Hematoxylin each time before staining is mandatory.

4. Change most of alcohol and xylene each time before staining.

1.3.6: EXAMINATION AND OSERVATION OF HISTOLOGICAL SLIDE:

1. Inspection:

Here we are going to lean that how to examine a histological slide under light microscope. A good light microscopy involve use of electric microscope. Inspect the slide using just your eyes and a good light source to first determine the shape of the prepared section. Occasionally, a specific section has a characteristic shape and is much easier to identify. e.g on the cross section of tracheal cartilage an annular preparation can be seen.

2. Calibration of microscope:

Place the slide under the microscope and calibrate the microscope so that the image produced is clear. Move the slide around so that its entire surface can be seen and check it with different lenses and magnifications. These objectives are usually standardized at 4X, 10X, 40X and 100X magnifications as shown in Figure: 1. this is important because:

- there are always major and minor structures on the preparation that might not always be visible with a single lens or magnification e.g in the ileum Peyer's patches are large and characteristic, whereas the other cells are smaller and not so defined.
- because the slide is always bigger than the lens so in order to view all the structures it must be moved around e.g a blood slide contains many different cells and they are not always evenly distributed.

3. Description: Write down a description of the major and minor structures that can be seen and name the ones that you are sure of e.g Large variable size nuclei, many dividing cells in

disorganized arrangement, variation in size and shape of cells, loss of normal tissue feature after comparing with control slide.

4. Determination: Determine the staining, sectioning and preparation process of the slide e.g eosin or silver nitrate staining, in longitudinal or cross section, frozen and sliced etc. as given in figure: 2^[24].

5. Identification: Once you have collected all the necessary information, try to piece the evidence together and through a process of elimination, identify the slide.

6. Completion: Add all additional information to your notes e.g cell functions, extra information mentioned by teachers etc.

7. Remember! Never jump to any conclusions, even if you are sure which micro preparation you have. Review all of the content at your disposal and only then, identify your slide.



Fig.1.16: Calibration of microscope

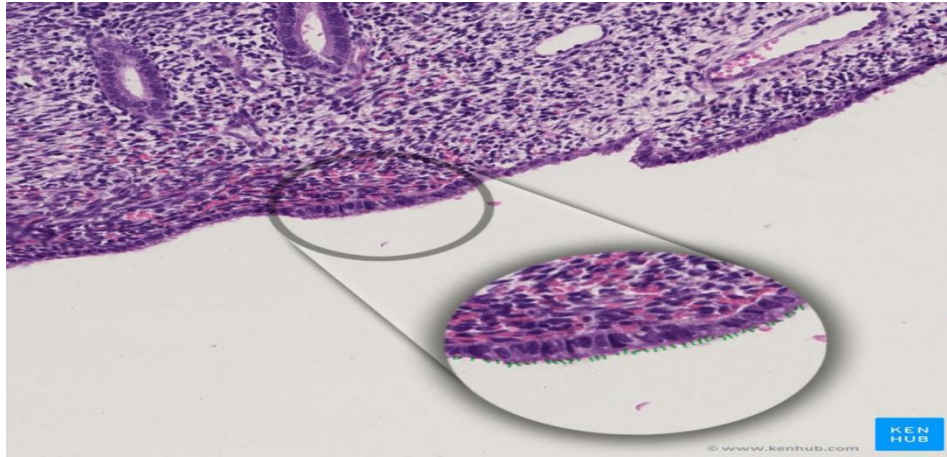


Figure: 1.17 Hematoxylin and Eosin stained slide

1.4 IMPORTANCE OF MICROTOMY:

Important in histopathology, microtomes are used in microscopy, allowing for the preparation of tissue sample for observation under light microscope or under electron microscope to detect various types of histopathological conditions *viz*, Cancer, abnormal haemopoiesis inside bone marrow, Condition of connective tissues and liquid connective tissue etc. It is also very important tool in histochemical study Immuno-histochemical study.

1.5 PROTOCOL FOR PRACTICAL OF MICROTOMY

STEP 1: HISTOLOGICAL PROCESSING: Collection of sample tissue, labeling given in 1.3.1.

STEP 2: FIXATION: Method of fixation given in 1.3.2 according to selected tissue.

STEP 3: TRIMMING AND EMBEDDING

(i) Trimming: After fixation trimming is done. Trimming is a process by which we make the tissue thinnest by using sharp object, cutting board, forceps, and single edge razor blade.

(ii) Embedding: It involve following steps:

3. Fill the mould with paraffin wax gently.
4. Using warm and cleaned forceps select the tissue, taking care that it does not cool in the air; at the same time.
5. Place the tissue in the mould according to the side to be sectioned. This side should be facing down against the mould. A small amount of pressure may be used in order to have more even embedding.

6. Chill the mould on the cold plate, orienting the tissue and firming it into the wax with warmed forceps. This ensures that the correct orientation is maintained and the tissue surface to be sectioned is kept flat.

7. Insert the identifying label or place the labeled embedding ring or cassette base onto the mould 8. Add more paraffin into the mould to fill the cassette and mould.

9. Cool the block on the cold plate.

10. Remove the block from the mould.

11. Cross check block, label and requisition form.

STEP: 4

Section cutting: Here we are learning the sectioning in Rotary microtome:

- Set the desired section thickness using the thickness setting knob at the front of the microtome on the right and check the value in the display window.
- Use a different area of the cutting edge (blade) for trimming than for sectioning.
- Use caution when repositioning blades and always ensure they are clamped back in place. For sectioning, turn the handwheel (right hand side) evenly in a clockwise direction. Repeat until desired number of sections is cut.
- Pick up the sections and mount them on microscope slides by preferred method. Always rotate the handwheel at a uniform speed. The rotation speed of the handwheel must be adapted to suit the hardness of the specimen. For harder specimens, use a slower speed.

(b)Pack up:

- Move the specimen clamp to the upper end position and lock the handwheel
- Remove the knife from the knife holder clean it and put it back in the knife case.
- Remove knife holder base and knife holder and clean them.
- Remove the specimen from the specimen clamp.
- Remove section waste with a dry paint brush.
- Remove specimen clamp and clean separately.

STEP 5: Staining: Here the method of staining only for hematoxylin. If already prepared stain is not available prepare it by following the method given in staining section 1.3.5 in theory.

Staining method of hematoxylin:

1. Deparaffinize sections in xylene, 10-20 minutes. Filter Hematoxylin.
2. Rehydrate sections: 100% alcohol for 1-2 minutes 95% alcohol for 1-2 minutes
3. Rinse in tap water
4. Rinse in distilled water
5. Stain with Hematoxylin for 3-5 minutes
6. Wash in tap water
7. Differentiate section with 1% HCl in 70% alcohol 1-2 dips and check under microscope. If necessary, return slides to HCl for further differentiation.
8. Wash slides in running tap water for 15-20 minutes
9. Stain slides in Eosin for 2-4 minutes.
10. Dehydration and Differentiation: 95% alcohol 5-6 dips 100% alcohol 5-6 dips
11. Clear slides in Xylene 2 times
12. Mount slides with mounting media (Permount or DPX)

Note: 1. before the staining the section should be dry

2. Hematoxylin and Eosin are regressive stain in which a tissue is over-stained and then excess dye is removed to obtain desired result.
3. Filtration of Hematoxylin each time before staining is mandatory.
4. Change most of alcohol and xylene each time before staining.

STEP 6: Observation of sections under microscope: Read 1.3.6 section of theory.

1.6 SUMMERY:

Nowadays advanced types of microtomes have been invented for histopathological works. are used in microscopy, allowing for the preparation of tissue sample for observation under light microscope or under electron microscope to detect various types of histopathological conditions viz, Cancer, abnormal haemopoiesis inside bone marrow, Condition of connective tissues and liquid connective tissue etc. It is very important tool in Histochemical and Immuno-histochemical study. The advance types of microtomes are being used in microtomy nowadays. These are Sledge, Rotary.Cryomicrotome, Ultramicrotome, Vibrating, Saw and Laser microtome. Their specificity depends upon tissues complexity and types of fixation. For the cutting of tissue specific kind of metal blade are require viz steel blade, diamond blade etc. Microtomy is six steps process: Histological process, fixation, trimming and embedding, sectioning, staining and observation of stained sections. Each step is tissue specific.Hence microtomy has great importance in medical science and research.

1.7 TERMINAL QUESTIONS:

1. Write briefly about receiving and labeling of the specimen.
2. What is a fixative? What is the commonest fixative?
3. Write the properties of an ideal fixative.
4. Write names of two special fixatives and their use.
5. What is dehydration and it is necessary. Write the name of common dehydrating agents?
7. What is decalcification? What kind of tissue requires decalcification?
8. Define embedding
9. Explain the types of embedding media
- 10 Explain the types of moulds
11. What is a microtome?
12. Write the name of various types of microtomes and their uses.
13. What are the steps to sharpen the knife?
14. What are the applications of microtome?

15. Name two types of disposable microtome blades and their use.
16. Explain the properties of hematoxylin.
17. Explain preparations of hematoxylin and Eosin.
18. Describe the method of Hematoxylin & Eosin staining.

1.8 REFERENCES:

- Gudrun Lang (2006 a, b, c, d, e, f, g). Histotechnik. Praxislehrbuch für die Biomedizinische Analytik. (*Histology: practical textbook for analytical biomedicine*). Springer, Wien/New York. ISBN 978-3-211-33141-5.
- Klaus Henkel (2006a, b, c), *Das Schneiden mit dem Mikrotom Archived 10 November 2009 at the Wayback Machine*. Mikrobiologische Vereinigung München e. V., 2006, accessed 15 February 2009.
- "Electron Microscopy", chapter 4, by John J. Bozzola and Lonnie Dee Russell.
- Micro Star Technologies, diamond knives.
- Krumdieck, Carlos L. (January 2013). "Development of a live tissue microtome: reflections of an amateur machinist". *Xenobiotica*. **43** (1): 2–7. Doi:10.3109/00498254.2012.724727. ISSN 0049-8254. PMID 23009272. S2CID 6108637.
- Abdelaal, Hadia M.; Kim, Hyeon O.; Wagstaff, Reece; Sawahata, Ryoko; Southern, Peter J.; Skinner, Pamela J. (1 January 2015). "Comparison of Vibratome and Compressatome sectioning of fresh primate lymphoid and genital tissues for in situ MHC-tetramer and immunofluorescence staining". *Biological 17Procedures Online*. **17** (1): 2. Doi:10.1186/s12575-014-0012-4. ISSN 1480-9222. PMC 4318225. PMID 25657614.
- Holger Lubatschowski 2007: *Laser Microtomy*, WILEY-VCH Verlag GmbH, Biophotonics, S. 49–51 (PDF Archived 19 July 2011 at the Wayback Machine). Doi: 10.1002/opph.20119025.
- <https://www.kenhub.com/en/library/learning-strategies/how-to-examine-a-histology-slide>.

UNIT 2: STUDY OF THE SKELETON

2.1 Objectives

2.2 Introduction

2.3 Skeleton study of Frog, *Varanus*, *Chelonia*, crocodile, snake, rabbit

2.4 Vertebrae and skull of poisonous and non-poisonous snake

2.5 Gallos and various types of palate

2.6 Skull of bat, dog, hedgehog, monkey, sheep, rodent and other mammal

2.7 Summary

2.8 Terminal Questions and Answers

2.1 OBJECTIVES.

After the study of this unit you will be able to:

- Determine the parts of endoskeleton Frog, *Varanus*, Snake and fowl and Rabbit.
- Identify and distinguish the bones of axial and appendicular skeleton of frog, *Varanus*, Snake and Rabbit.
- Identify and distinguish the different types of vertebrae and distinguish the skull of poisonous and non-poisonous snake.
- Identify and distinguish the various types of palate (small bones) present in skull of Gallos.

2.2 INTRODUCTION

The skeleton forms the frame-work of the animal body, and so is extremely important for the organism. An external skeleton as found in a number of nonchordates, especially in the insect group of phylum Arthropoda; and an internal skeleton which is found in all chordates and forms an internal framework of cartilages and bones. This skeleton is also referred to as endoskeleton. You will also recall from the earlier courses that the absence or presence of the endoskeleton in animals has been used to divide them into two distinct divisions of the animal kingdom. In non -chordates in which the endoskeleton is absent, while the chordates in which the notochord which is a part of the endoskeleton is present and it is well developed. The main object of endoskeleton study of vertebrates viz; amphibia (*Rana tigrina*, order-anura), reptilia (*Varanus*, snakes) and mammals (*Oryctolagus*) is the establishment of affinities and differences with these different class of animals. More over the skeleton study of *Rana tigrina* also helpful in understanding the interrelationship of Anurans with other living amphibians order namely, Apoda or gymnophiona and caudate or urodela.

Similarly the study of reptilian endoskeleton viz; *Varanus* and snake (order squamata) establishes the phylogenic history and interrelationship between other reptilian orders namely, chelonia crocodila and ophidia. On other hand study osteology of mammals (*Oryctolagus*) and amphibian also establishes the affinities between two classes because both are dicondylic (two occipital condyle) and both have paired forelimb and hindlimbs and their limb bones are structurally similar however, according to body size they are reduce in *Rana tigrina* and larger in *Oryctolagus*. It may be due to adaptation and adaptive radiation.

The endoskeleton of vertebrates divided into two parts the axial skeleton and appendicular skeleton. The endoskeleton of tetrapods can be divided into two parts the: (1) Axial skeleton

which comprises of: (A) bones of the head (skull); (B) vertebral column, (C) thorax and sternum (2) Appendicular skeleton which comprises: (A) the bones of the paired limbs, namely the (A) forelimbs and the (B) hind limbs (C) the pectoral (shoulder) and (D) pelvic girdles.

2.3 SKELETON STUDY OF FROG:

The skeleton of frog can be studied under two headings (1) The axial skeleton (2) The appendicular skeleton.

1. THE AXIAL SKELTON:

(A) Skull: The skull of frog is broad and flat and consists of a narrow cranium (brain box), paired sense capsules, large orbits, the jaws, hyoid and cartilages of larynx. In the complete endoskeleton is shown in Figure: 2.1 while 2a and 2b the articulated (fused) bones of skull are shown while in figure: 3, 4, 5 and 6, disarticulated bones (separate bones or loose bones) of skull are shown.

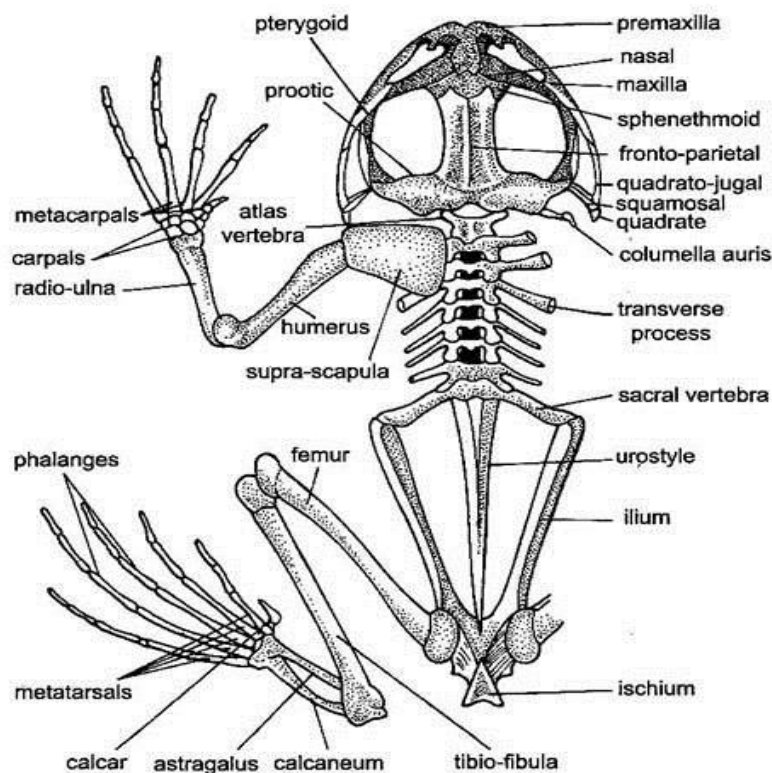


Figure 2.1: Frog skeleton (left side only)

(a) Cranium: The cranium is the narrow cavity lodging the brain, it is also called brain box. In the anterior part of the cranium is a sphenethmoid surrounds the forebrain and olfactory

sacs. Skull is divided by a transverse partition into an anterior ethmoidal area and a posterior sphenoidal area (region) which encloses the forebrain. The ethmoidal region surrounds the olfactory sacs. Sphenethmoid bone is exposed laterally. It is covered dorsally by a pair of nasals and a fronto-parietal bone and covered ventrally by a blade-shaped parasphenoid bone (figure-.3)

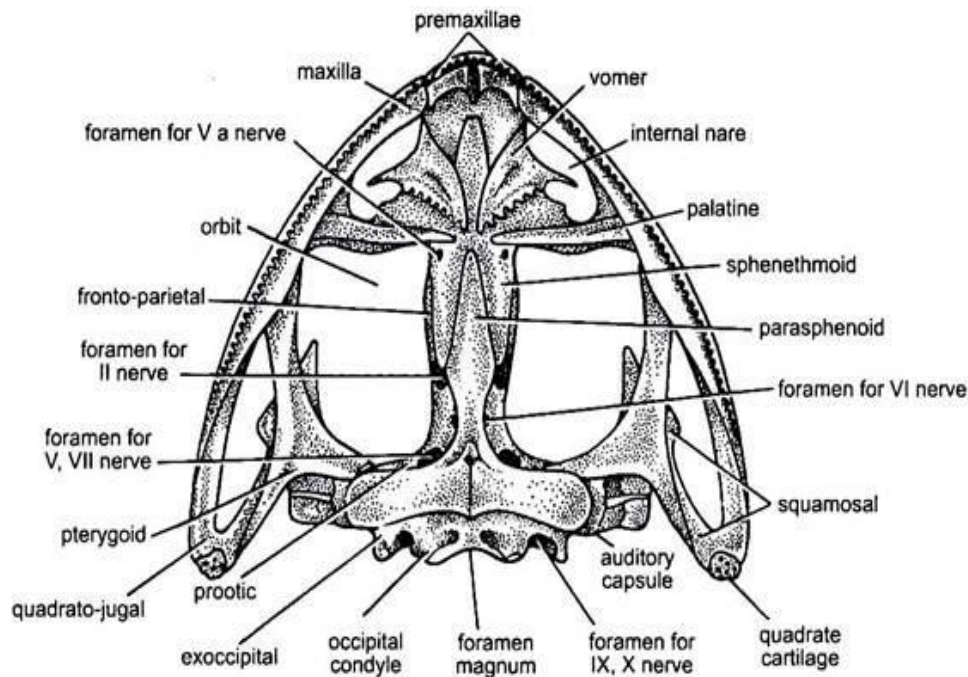


Figure 2.2 Frog. Skull (dorsal view)

(i) Occipital Segment: At the posterior end of the cranium is a foramen magnum surrounded by two exoccipitals. Each exoccipital carries at its posterior end a convexity, the occipital condyle (out growth of bone) which articulates (connects) with the concavity of the atlas vertebra. The auditory capsule is fused on the outer side of each exoccipital. Each auditory capsule has a pro-otic in front; the capsule has an aperture, the fenestra ovalis into stapedial plate fits, stapedial plate cartilaginous. The stapedial plate is a part of the columella develops from the hyandibular bone.

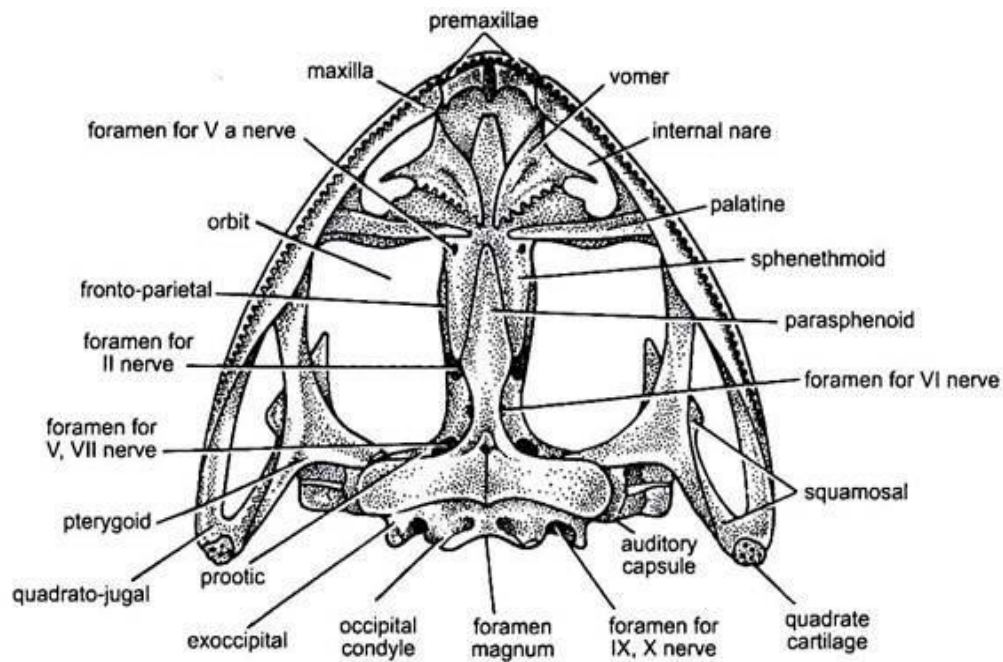


Figure 2.3: Frog. Skull (ventral view)

(ii) Olfactory Capsules: The olfactory capsules have two nasals dorsally and two vomers ventrally, the vomers bear vomerine teeth. A pair of special bones called septomaxillary (ethmoids) form the boundary of nostrils. They are associated with and surround the Jacobson's organ Figure-3).

(iii) Optic Capsules: They enclose the eyes and are not fused with the skull.

(b) Visceral Skeleton: Visceral skeleton includes the upper and lower jaws, the hyoid apparatus, the columella auris and cartilages of larynx.

(i) Upper jaw: The upper jaw is divided in two halves, each half has an anterior premaxilla followed by a long maxilla, both halves bear teeth. The posterior part of the upper jaw has a small quadratojugal bone. Its largest posterior end unites with quadrate cartilage, which is a small thin rod forming the suspensorium. The mandible fused with the quadrate cartilage. Ventral anterior to the orbit is a slender, rod-like palatine bone. At the posterior lateral end of cranium is present a large 3-rayed or Y-shaped pterygoid bone. It joins anteriorly with the maxilla and palatine and on the inner side with the parasphenoid and auditory capsule, and posteriorly with the quadratojugal and quadrate cartilage

At the posterior dorsolateral end of cranium is the hammer-shaped bone called squamosal. It lies above the pteryoid. Its front limb or head is free and the short posterior limb joins with the auditory capsule and prootic bone and its handle joins with the quadrate cartilage.

(ii) Lower Jaw or Mandible: The lower jaw has two vertical portion called rami joined in front by elastic ligament. Each half has a core of Meckel's cartilage covered over by an angulosplenic

Forming the inner and posterior portion of each ramus. Its anterior end is tapering and posterior end possesses dorsally a condyle for the fusion with the quadrate cartilage. Just anterior to the condyle a small dorsal projection is present called the coronoid process. Anterior outer surface of Meckel's cartilage is covered by a small, flat, dogger-like dentary. In front it extends to Mentomeckelian bone and its posterior part is attached with the outer side of angulosplenic. A small cartilage bone, the Mentomeckelian is found at the extreme anterior end of Meckel's cartilage Just anterior to the condyle a small dorsal projection is present called the coronoid process. Anterior outer surface of Meckel's cartilage is covered by a small, flat, dogger-like dentary. In front it extends to Mentomeckelian bone and its posterior part is attached with the outer side of angulosplenic. A small cartilage bone, the Mentomeckelian is found at the extreme anterior end of Meckel's cartilage.

(iii) Hyoid: Hyoid has a thin structure and it is cartilaginous. It is situated in front into two alar processes and behind into two posterior lateral processes. In front there are also two long slender

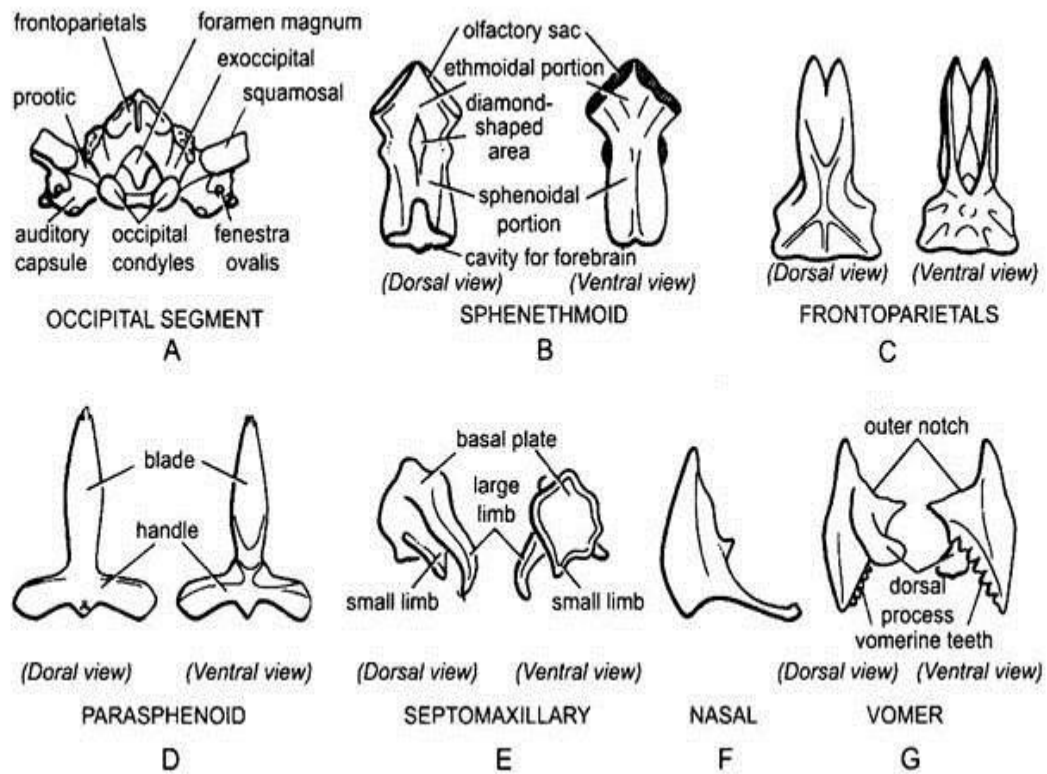


Figure-2.4: Frog. Loose skull bones of cranium and sense capsules.

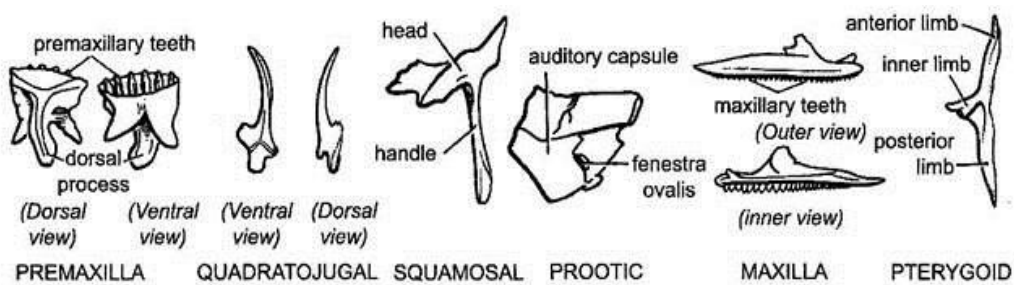
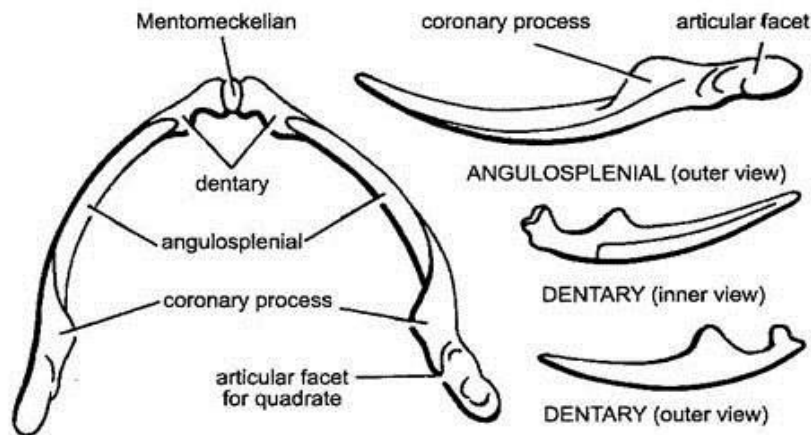


Figure-2.5: Frog. Loose (disarticulated) skull bones of upper jaw

anterior cornua of cartilage, they turned backwards and connects the auditory capsules posteriorly is a pair of strong bony posterior cornua or thyrohyals between which lies the glottis. The hyoid lies in the floor of the pharynx, bellow the tongue.



Figur-2.6: Frog. Loose bones of mandible (lower jaw)

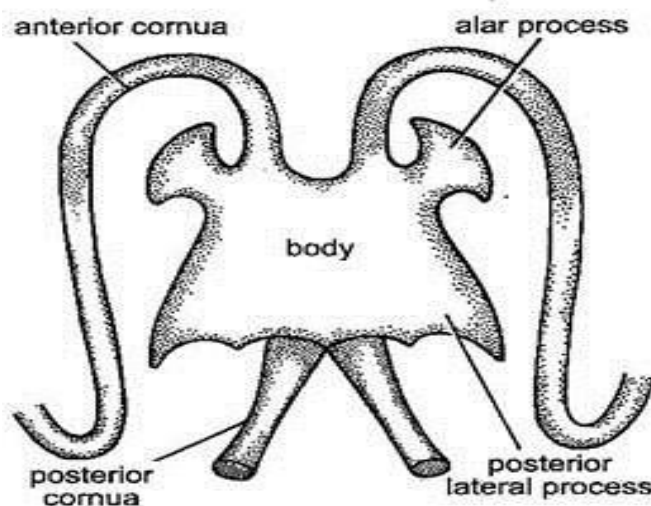


Figure-2.7: Hyoid apparatus

(B) Vertebral Column: The vertebral column or backbone of frog surrounds and protects the spinal cord from external shock. Due to absence of tail it is very short. It consists of nine vertebrae and a last rod-like structure called the urostyle. The first, eighth and ninth vertebrae are uncommon in structure, while vertebrae from second to seventh are almost similar in structure.

(i) Typical Vertebra (II-VII vertebra): There are six typical vertebrae in the axial skeleton of frog (II to VII vertebra). All the typical vertebra is anatomically similar. A typical vertebra has a solid cylindrical part known as the centrum. The centrum is procoelous, (it is concave in front

neural arch is large. The front face of centrum carries a pair of concave facets for the articulation with the occipital condyles of the skull. The posterior part of the neural arch having a pair of postzygapophyses.

(iii) Eighth Vertebra: The centrum of eighth vertebra is amphicoelous, (concave on both the sides). The anterior concavity takes the posterior convexity of the seventh vertebra. Transverse processes outwardly directed, slender and long. Prezygapophyses and postzygapophyses are present on the front and posterior margins of the neural arch.

(iv) Ninth Vertebra: It is also known as sacral vertebra. The centrum of this vertebra is biconvex, i.e., convex on both the sides (one convexity anteriorly and two convexities posteriorly). The anterior convexity fits into the posterior concavity of eighth vertebra. The posterior convexities of centrum fall in with the anterior concavities of urostyle. Transverse processes are cylindrical, stout and backwardly directed. Iliac facet is present at the tip each transverse process for the articulation of ilium bone of pelvic girdle. Neural spine is greatly reduced. Prezygapophyses are well developed along the front end of neural arch, while the postzygapophyses are completely absent.

Functions of Vertebral Column: (i) it supports the trunk region and provides strength. (ii) It encloses and protects the spinal cord from external shock (iii) In front it supports the head which is held slightly above the ground and help in making body balance. (iv) It acts as a body-axis from which viscera are suspended in the body cavity by mesenteries.

(v) Sternum: It is situated midventrally connected between the both halves of pectoral girdle. Sternum consists of four parts. Anterior to the clavicle lies an inverted Y-shaped bony omosternum which is frontally attached with the cartilaginous round, flat episternum. Posterior to the epicoracoid and coracoids is a bony rod-like sternum proper mesosternum (sternum proper) to which is attached a broad cartilaginous xiphisternum posteriorly. Ribs are absent.

2. APPENDUCULAR SKELETON:

(A) Pectoral Girdle: The pectoral girdle or shoulder girdle is present in the thoracic region and provides attachment to the forelimbs and their muscles (figure-8). It also protects the inner softer parts of the thorax. It consists of two similar halves united mid-ventrally and

separated dorsally. Each half is divided into a dorsal (i) scapular portion and a (ii) ventral coracoid portion.

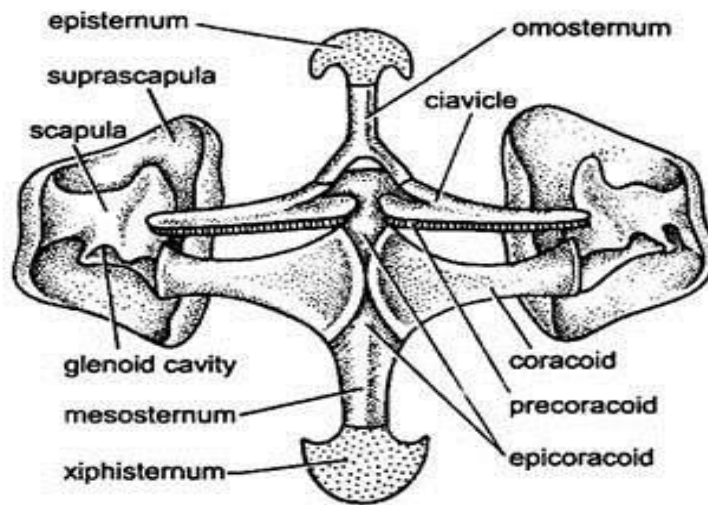


Figure-2.9: Pectoral Girdle of frog

(i) Scapular Region: The scapular portion comprises the suprascapula and scapula. Suprascapula is a thin, flat, somewhat rectangular cartilaginous plate on the dorsal side. It covers dorsally the first four vertebrae. Its free margin is calcified and the lower part articulating with the scapula is bony. At its posterior end is present a glenoid cavity into which articulates the head broad towards the end and narrower in the middle.

(ii) Coracoid Portion: The coracoid portion comprises the clavicle, coracoid, precoracoid and epicoracoid. Clavicle (a slender rod) and coracoid (dumb-bell-shaped) meet mid-ventrally with the sternum and their counterparts of other side by a strip of cartilage called epicoracoid.

(B) Pelvic Girdle: The pelvic girdle in frog lies in the posterior region of the trunk. It gives support to the hind limbs. It is V-shaped and made up of two equal halves, each of which is known as os-innominatum. Each os-innominatum is made up of three bones namely, ilium, pubis and ischium, which form the disc and the acetabulum.

(i) Ilium: it is much elongated and forms the major part of each os-innominatum. It runs forwards to meet the transverse process of the ninth vertebra. It carries a prominent dorsal vertical ridge, the iliac crest. Both the ilia fuse posteriorly and form the anterior and upper half of the disc and acetabulum.

(ii)Publis: It is much reduced, triangular piece of calcified cartilage, forming the mid part of the disc and a small part of the acetabulum. Both the pubes are also fused and give rise one-third part of the disc and acetabulum. Thus, the disc is formed by the fusion of three bones containing a cup-shaped cavity called acetabulum. In acetabulum, the head of femur fuses.

(iii) Ischium: is larger and slightly oval in shape and both the ischia fused in the middle and give rise one-third part of the disc and acetabulum. Thus, the disc is formed by the fusion of three bones containing a cup-shaped cavity called acetabulum. In acetabulum, the head of femur fuses.

(C)Forelimbs and its bones: The bones of the forelimbs include humerus, radio-ulna and the bones of hand.

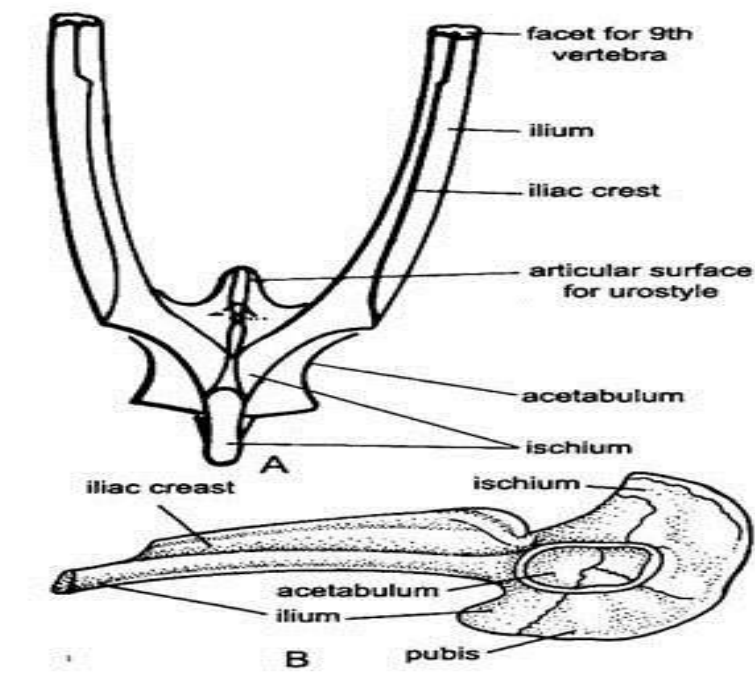


Figure-2.10: Lateral view of Pelvic girdle of frog

(i)Humerus: It is the bone of the upper arm of forelimb. It is a short, stout and cylindrical bone with a slightly curved shaft. Its proximal rounded end is known as the head which fits into the glenoid cavity of pectoral girdle. The head is covered by calcified cartilage. The ridge beneath the head is called deltoid ridge (furrow) to which muscles is attached. The distal end forms a rounded trochlea with a condylar ridge on both sides. The trochlea fuses with the groove of radio-ulna.

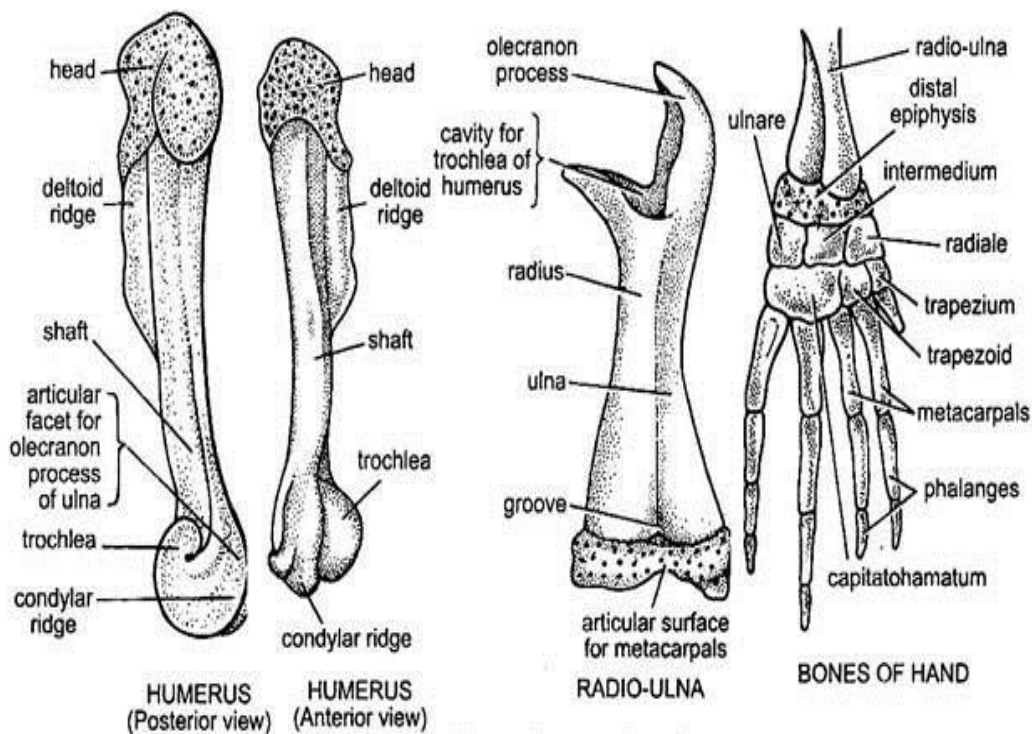


Figure-2.11: Forelimb bones of frog: (a) anterior and posterior view of the humerus bone of the upper arm; (b) Radio-ulna of the lower arm of the forelimb; and (c) bones of hand.

(ii) Radio-ulna: Radio-ulna is a compound bone of forearm of forelimb and formed by the fusion of radius and ulna bones. Its proximal end has a concavity to takes the trochlea of humerus bone. The proximal portion of ulna projects into an olecranon process and forms the elbow joint. The distal portion of radio-ulna having a median furrow dividing it into an anterior (radial) part and a posterior (ulnar) part terminating into a facet providing articular surface for the proximal line of carpals.

(iii) Bones of Hand:

The wrist bones are called carpals. The carpals bone is six in number. These six carplas arranged in two rows (three in each row). The bones of the first row (close to epiphysis) row are called ulnare, intermedium (centrale) and radiale. These bones fuses with the radio-ulna through epiphysis. The bones of the distal 1 row are called capitohamatum, trapezoid and trapezium. These bones fused with the metacarpals.

The hand or manus is provided with five slender metacarpals. The first metacarpal is rudimentary. The digit corresponding to thumb is absent; the remaining four metacarpals are

supported by phalanges. The second digit bears two phalanges. The third and fourth digits bear three phalanges each.

(E)Bones of Hindlimbs:

The bones of hindlimbs include femur, tibio-fibula, astragalus-calcaneum and bones of the foot.

(i) Femur: Femur is also called “thigh bone” and is bone of hindlimb. It is long and slender having a slightly curved stem. The anterior swollen end is called the head which fits into the acetabulum of pelvic girdle consequently forming a ball and socket joint. The posterior end forms a condyle which fuses with the tibio-fibula. The head and condyle are covered by cartilage which is made up of calcium.

(ii) Tibio-Fibula: Tibio-fibula is a compound bone of shank region of hindlimb. It is formed by the fusion of tibia and fibula bones forming a compound bone called the tibio-fibula. In between tibia and fibula a median longitudinal groove found. Likewise radio-ulna tibio-fibula also has anterior end (proximal end) having and posterior ends (distal end) are covered by calcified cartilage. Near the proximal end tibia bears an cnemial or tibial crest. The proximal end fuses with the femur, while the distal end fuses with the astragalus-calcaneum.

(iii) Astragalus-Calcaneum: Astragalus-calcaneum is also a compound bone of ankle of hindlimb. The ankle made up of two rows of four tarsal bones. The proximal row comprises two long bones fused together at their proximal and distal ends with a wide space in the middle.

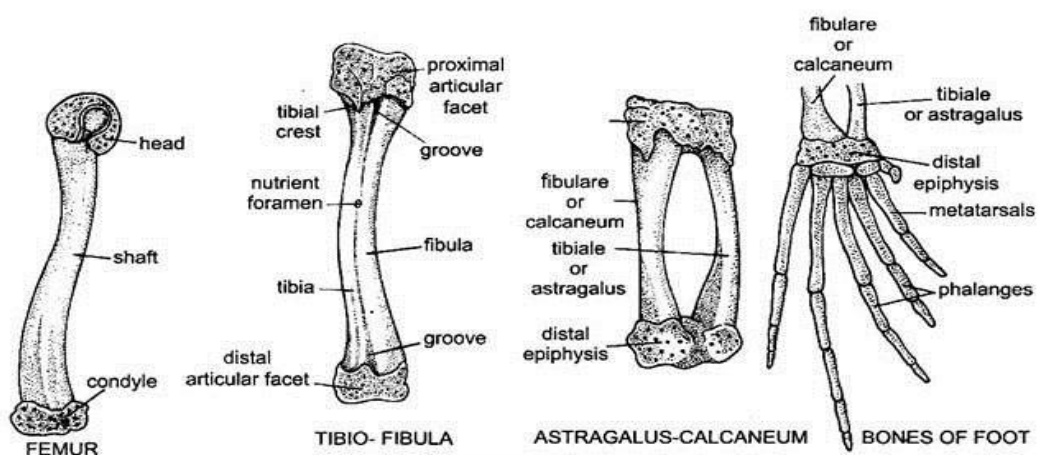


Figure-2.12: Hind limb bones of frog: (a) Femur bone;(b) Tibio-fibula bone(c) Astragalus-calcaneum and d) bones of foot.

The inner bone is thinner and slightly curved, called the astragalus or tibiale, while the outer bone is thicker and straight, called the calcaneum or fibulare. The proximal and distal ends are covered by small bones by epiphyses which is cartilaginous and calcified. Distal row of tarsals has two Very small bones.

(iv)Bones of Foot:

The foot is supported by five long and slender metatarsals bones having five true toes, having 2, 2, 3, 4 and 3 phalanges. A small preaxial sixth toe consists of two bones (in some anuran 3 bones) is present on the inner side of the first toe (hallux). The preaxial sixth toe is known as prehallux or calcar.

References:

1. <http://egyankosh.ac.in/handle/123456789/57537>
2. <https://www.notesonzoology.com/frog/endoskeleton-of-indian-frog-with-diagram-chordata-zoology/8261>
3. <https://www.notesonzoology.com/frog/endoskeleton-of-indian-frog-with-diagram-chordata-zoology/8261>.
4. <https://www.notesonzoology.com/frog/endoskeleton-of-indian-frog-with-diagram-chordata-zoology/8261>.

2.3 SKELETON STUDY OF VARANUS

Varanus is commonly called monitor lizard. Monitor lizards have long necks, powerful tails and claws, and well-developed limbs. The adult length of extant species ranges from 20 cm (7.9 in) in some species, to over 3 m (10 ft) in the case of the Komodo dragon, though the extinct varanid known as megalania (*Varanus priscus*) may have been capable of reaching lengths more than 7 m (23 ft). Most monitor species are terrestrial, but arboreal and semiaquatic monitors are also known. While most monitor lizards are carnivorous, eating eggs, smaller reptiles, fish, birds, insects, and small mammals, some also eat fruit and vegetation, depending on where they live.^[1] The endoskeleton of *Varanus* is also divisible in two types (1) Axial skeleton (2) Appendicular skeleton. Axial skeleton consists of skull, vertebral column, sternum and ribs while appendicular skeleton contains (A) pectoral girdle (B) pelvic girdle and bones of (C) forelimbs and (D) hindlimbs. In figure-1 the fused endoskeleton (articulated) is shown.

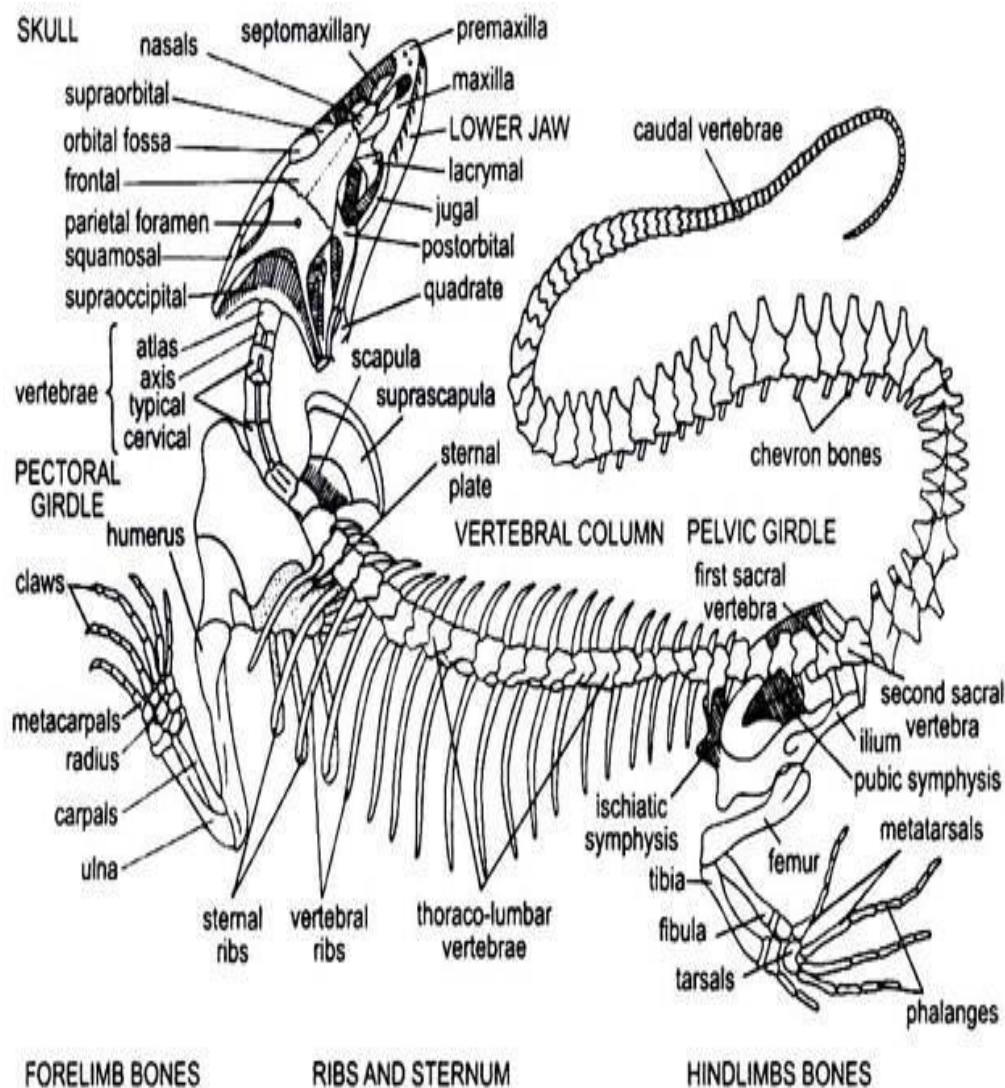


Figure-2.1. Complete articulated endoskeleton of *Varanus*.

1. AXIAL SKELETON:

(A) **SKULL:** The skull of *Varanus* is monocondylic, i.e., single occipital condyle formed by the basioccipital. It is tropibasic, i.e., having a interorbital septa separating the two orbits. Alisphenoids, orbitosphenoids and presphenoid bones are absent while prefrontals, supraorbitals and postorbitals are present. A pair of parietals are fused and perforated by a median parietal foramen. Both the premaxillae are also articulated to form a single bone. Three temporal fossae are also found in skull. In the tympanic cavity a single ear ossicle (columella) is found. In jaws polyphyodont, homodont and pleurodont teeth are found. Jaw suspension is Autostylic i.e., lower jaw fused with the quadrate bone of upper jaw.

The skull of *Varanus* is divided into four main parts viz., the cranium, sense capsules (auditory, optic and olfactory) and the visceral skeleton consists of jaws and hyoid apparatus. Articulated (fused) skull of *Varanus* is shown in figure-2 and disarticulated(separate) bones of skull is shown in figure-3.

(a) Cranium:

The proper cranium makes the posterior part of the skull and lodges the brain. The cranium consists of three compartments, i.e., the anterior frontal segment, the middle parietal segment, and posterior occipital segment.

(i) **Frontal segment:** The frontal segment comprises only three bones, a pair of frontals and a parasphenoid. **Frontals:** The frontals are large triangular bones situated on the dorsal side with their top forwards. They join to each other along the median line by a frontal suture and with the parietal behind by a bone called coronal suture. The frontals make the roof of the cranium in the frontal segment.

Frontals fuses in front with nasals, with prefrontals, palatines and postorbitals bone on the outer sides, and with the parietals behind and below with the parasphenoid bone.

Parasphenoid:The parasphenoid is a long, narrow and rod-like bone in the mid-ventral line (figure-2).

(ii) **Parietal segment:** The parietal region consists of three bones, two parietals and a basisphenoid. **Parietal:** The parietal is a large and flat bone situated on the postero-dorsal side of the cranium. It forms the roof of the cranium in the parietal region . The two parietals articulates

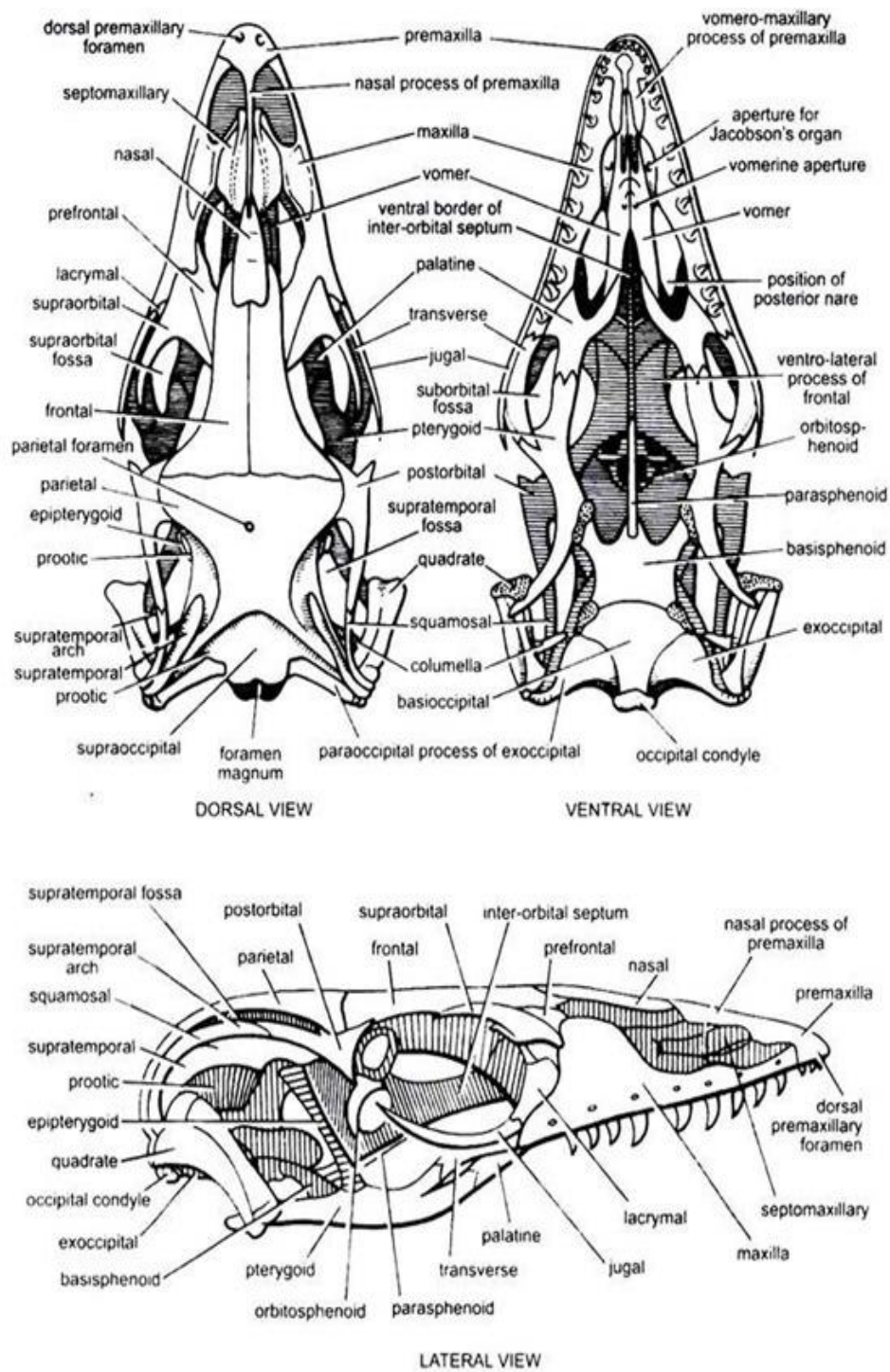


Figure-2:2 Skull of *Varanus* in dorsal, ventral and lateral view.

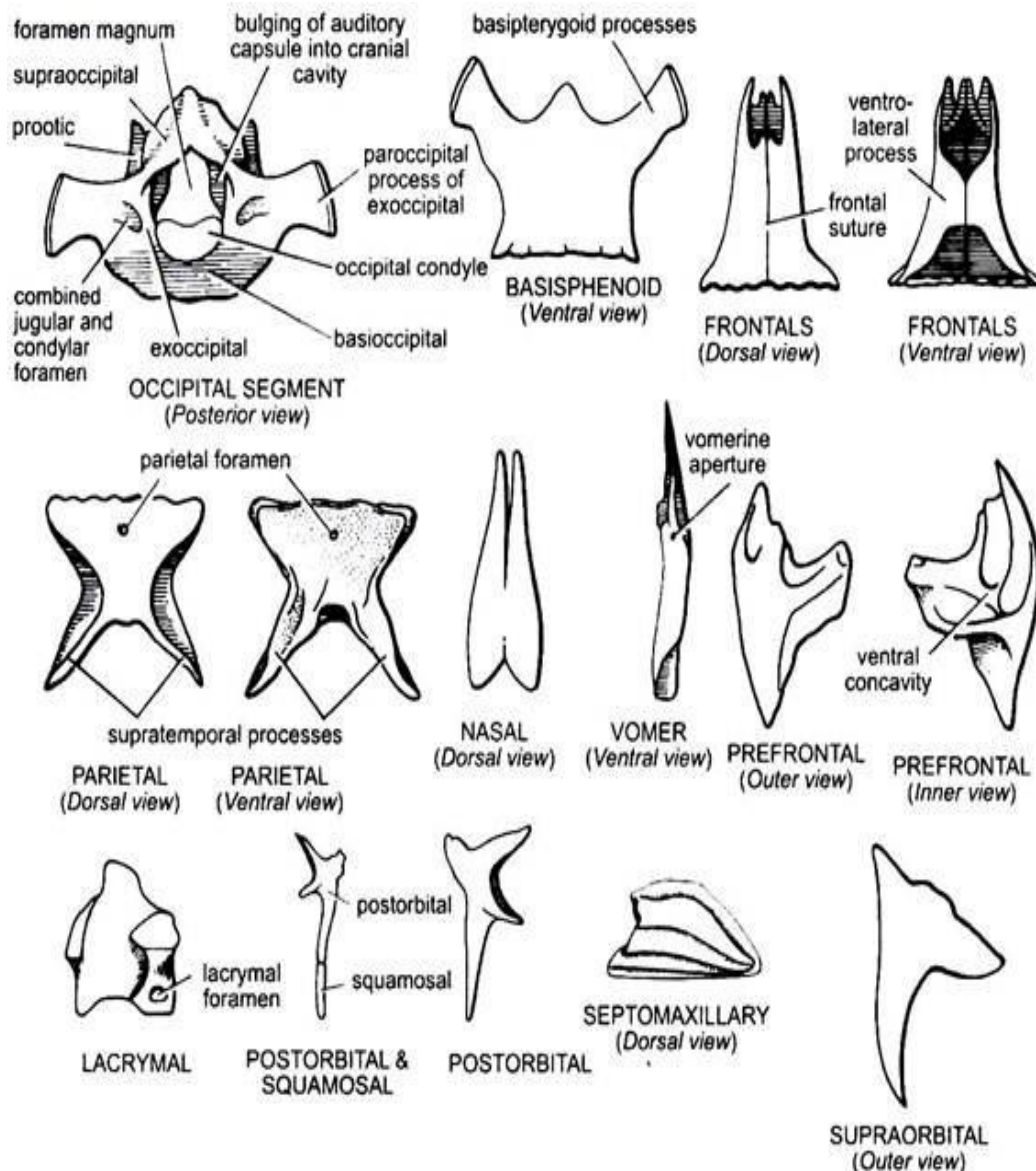


Figure 2.3 : *Varanus*. Loose skull bones of cranium and sense capsules.

and form a single bone. It is broad in front and narrow behind. It has a parietal foramen in its centre. Its postero-lateral angles are produced into supratemporal processes, each of which fuses with the quadrate, squamosal, supratemporal and paroccipital bones of the exoccipital of its end. The supratemporal bone makes the outer margins of the post-temporal fossa.

(iii) Occipital Segment: The occipital region is the most posterior part of the cranium. It surrounds a large aperture called foramen magnum in its centre. It comprises 4 bones namely, the dorsal supraoccipital, lower basioccipital and paired lateral exoccipitals. Supraoccipital is more or less rectangular and forms the roof of the back portion of the cranium. Supraoccipital fuses anteriorly with the parietals and laterally with the prootics and forms the post-temporal fossa.

Basioccipital makes the floor of the hindermost portion of the cranium and bears a single occipital condyle posteriorly. It anteriorly fuses with the basisphenoid and laterally with the exoccipitals and prootics.

Exoccipitals enclose the foramen magnum from its lateral sides. Each exoccipital is produced on its outer side into a paroccipital process fusing with the supratemporal, parietal, squamosal, and quadrate. Each exoccipital has integrated juglar and condylar foramen from which X, XI and XII cranial nerves and artery and vein exit.

Each exoccipital fuses with the supraoccipital, prootic and the basioccipital. Occipital segment posteriorly fuses with the atlas vertebra by the occipital condyle of the basioccipital. All the bones of this segment are fused and form a ring-like structure.

(b) Sense capsules : There are three pairs of sense capsules- auditory, optic and olfactory inside the skull of *Varanus*.

(i) Auditory Capsules:

The auditory capsules surround the internal ears, organs of hearing. They are located on the lateral sides of the posterior end of cranium. Each capsule consists of a single small irregular vertical(perpendicular) bone called prootic which occurs just outside the supraoccipital bone. The epiotic and opisthotic bones are indistinguishable. The epiotic is articulated with the supraoccipital bone. The opisthotic bone is fused with the exoccipital bone.

(ii) Optic Capsules:

The orbits or optic capsules are a pair of large excavations on the lateral sides of the cranium. They surround the eyes. The two orbits are isolated from one another by a thin, long, vertical partition, the interorbital septa. Each orbit is bounded by 5 bones- prefrontal, supra-orbital, lacrymal, post-frontal or post-orbital and jugal.

Prefrontal: The prefrontal is a small, more or less triangular bone having a deep. On its ventral side it bears a cup-like concavity. It is situated obliquely between the frontal and the maxilla. It makes the anterior periphery of the orbit and posteriorly it fuses with the suprarorbital.

Lacrymal: Lacrymal is a square-shaped bone and makes the anterior boundary of the orbit. It is perforated by a lacrymal duct.

Postfrontal: Postfrontal name is given because it is present behind the frontal, and postorbital name is given because it forms postero-dorsal boundary of orbit. Postfrontal or postorbital is an irregular bone producing four processes. In between the two inner processes is present a deep notch which receives the parietal and frontal. The posterior longest process

fuses with the squamosal while the antero-lateral process occurs free. It forms the posterior boundary of the orbital capsule.

Jugal: Jugal is a slender, curved, rod-like bone forming the ventral border of the orbit.

(iii) Olfactory Capsules: The olfactory capsules situated side by side in front of the cranium and consists of the organs of smell. Each capsule comprises dorsal nasal, septomaxillary and ventral vomer.

Nasals:

Nasals make the roof of the olfactory capsules. Two nasals fused in the mid-line and forms a single compound bone. Each nasal is a flat triangular bone, anteriorly narrow and posteriorly broad. Nasals fuses anteriorly with the nasal process of premaxilla and two septomaxillanes, and posteriorly with the frontals.

Vomer:

The vomer is a long rod-shaped bone situated on the floor of the olfactory capsule. It joins with its counterpart in the mid-line in the anterior half and their posterior half remains free. It makes the inner boundary of the posterior nares and depressed by a vomerine aperture in its centre. anteriorly it fuses with the vomero-maxillary process of premaxilla, with the palatine posteriorly and Jacobson's organ outside in the anterior region.

(c) Visceral Skeleton¹:

It consists of jaws (upper jaw and lower jaw), suspensorium and hyoid (apparatus figure-4).

(i) Upper Jaw:

The upper jaw contains of two similar halves (rami) which are fused frontally together in the middle line but diverge behind. It articulates with the cranium with close association. Each half (ramus) comprises of nine bones distinguishable into two sets- the outer and inner. The outer set contains four bones- premaxilla, maxilla, jugal, septomaxillary, and quadrate, while the inner set consists of five bones- pterygoid, palatine, transpalatine or transverse or ectopterygoid, epipterygoid and squamosal. The detail of the bones of upper jaw is given below (figure-4).

Premaxillae:

Two premaxillae articulates in the mid-line into a single bone and form the anterior margin of the snout. On its ventral surface it carries 6-8 small conical teeth along its margins. Posteriorly it is produced into a long, dorsally narrow nasal process which remains into the groove present on the anterior part of the nasals. A pair of wing-like ventral vomero-

maxillary processes fusing with the vomers behind. Premaxillae articulate on either lateral sides with the maxillae.

Maxilla:

The maxilla makes the major region of the upper jaw on either side. It is a long irregular bone lying on either side behind the premaxillae. Outer surface of each maxilla is perforated by a number of maxillary foramina. The main body of each maxilla is known as alveolar part which bears a row of 8-10 teeth along its outer margin. These teeth pleurodont type, small, conical and pointed backward.

The palatine process located on the inner side and is poorly developed due to which a gap is present between maxilla and palatine. Maxilla fuses anteriorly with the premaxillae, septomaxillary and vomer. Its upper process fuses with the prefrontal, supraorbital, nasal and lacrymal. Posteriorly it fuses with palatine, jugal and transverse bones.

Jugal:

Jugal is located behind the maxilla. It is slender curved, rod-like bone. Besides forming a part of the upper jaw, it also bounds the orbit ventrally. In front it fuses with the maxilla and lacrymal and on the inner side with the transverse, but free from behind.

Palatine:

Palatine is the bone makes the roof of the buccal cavity. It is small, flat and more or less irregular bone. It is produced into three processes. The anterior long process joins with the vomer, the

posterior small process with the pterygoid and the outer broad process with the maxilla and transverse. Palatines makes the posterior boundary of inner nares.

Pterygoid:

Pterygoid is a irregular and large elongated bone. Pterygoids are located on the roof of mouth. It has an anterior palatine process and a posterior quadrate process. It fuses anteriorly with the palatine bone on the inner side and transverse on the outer side, posteriorly with the basipterygoid process of basisphenoid on the inner side and with the quadrate on the outer side.

Transverse:

The transverse is a small curved bone connecting the pterygoid with the jugal and the maxilla. It makes the floor of the orbit. It is also called the ectopterygoid or transpalatine.

Epipterygoid:

It is also called columella crani. Epipterygoid is slender rod-like bone extending almost vertically from the upper surface of the pterygoid to the prootic.

Squamosal:

The squamosal is a curved rod-like bone and attached to the posterior end of the arcade. It's anterior end joins a backward process of the post-frontal to form the supra-temporal arch, and it's posterior end bends downwards and fuses with quadrate, supra-temporal, parietal and exoccipital.

Septomaxillary:

A pair of irregular, small, flat bones is located on the dorsal side of vomers and one on either side of nasal process of premaxillae in the nasal region. These fuses with maxillae and nasals.

Suspensorium:

It includes quadrate and squamosal bones which suspend the lower jaw with the cranium and upper jaw.

Quadrate: The quadrate is a thick, small, rod-like bone of the suspensorium. It situated obliquely in the postero-lateral side of the back region of the cranium. Posteriorly it fuses with the squamosal, supra-temporal, supra-temporal process of the parietal and paroccipital process of exoccipital. Anteriorly it fuses with the quadrate process of pterygoid and lower jaw.

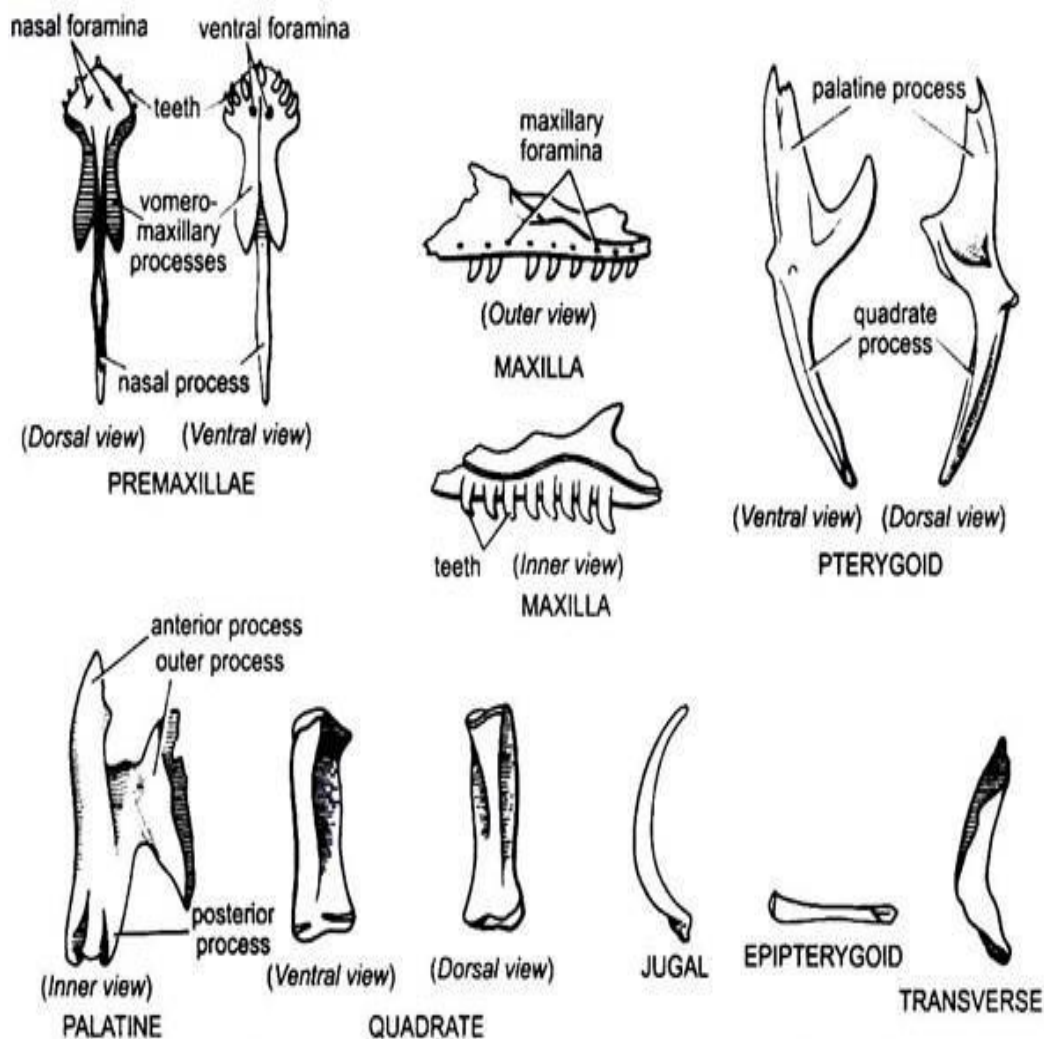


Figure-2.4: *Varanus*. Loose skull bone of suspensorium and upper jaw.

(ii) Lower Jaw: The lower jaw or mandible consists of two halves or rami joining anteriorly. Each ramus is composed of six bones (palates), i.e., articular, angular, supra-angular, coronoid, splenial and dentary around an axial Meckel's cartilage. The detail of these bones given below (figure-5):

Articular:

The articular is the posterior most bone of the ramus. It bears an articular surface for the quadrate on its dorsal surface and extends posteriorly closing out into an articular cartilage.

Angular:

Angular is a small splint-like bone fitted in between the dentary and articular and perforated by an angular foramen.

Supra-Angular:

Supra-Angular is a elongated, flat and more or less rectangular bone located in the middle of the ramus. It bears a pair of mandibular foramina for the mandibular nerves. It is found over the upper half of the outer surface of articular.

Coronoid:

Coronoid is a small more or less conical bone located above the supra-angular. It forms the dorsal side of the middle portion of ramus. Just behind the last tooth it is produced into an upwardly directed coronoid.

Splénial:

Splénial is a, irregular and membranous bone located on the inner side of the dentary.

Dentary:

Dentary is the largest bone and makes the distal half portion of the ramus. It carries a row of 8 to 10 small, conical mandibular teeth which are of pleurodont type. Its outer surface also carries numerous foramina for the mandibular nerves. Both the dentaries fuses suturally at their anterior ends.

Hyoid Apparatus:

The hyoid apparatus lies enclose in the floor of the buccal cavity. It support the tongue and it is cartilaginous . It consists of a basihyal (main body) and two pairs of cornua originating from basihyal (figure-6).

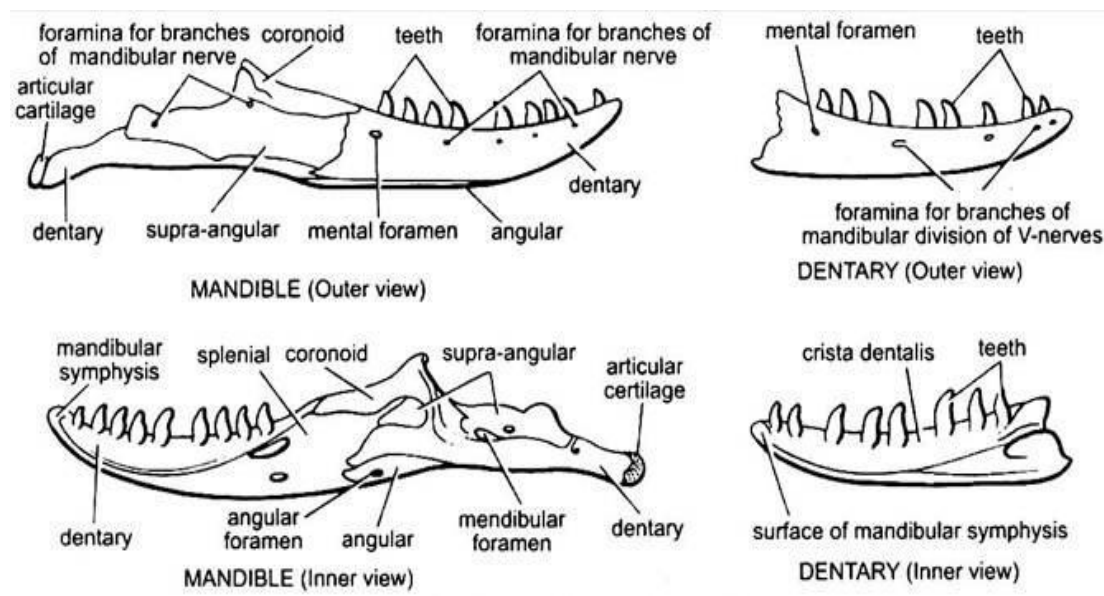


Figure-2.5 : *Varanus*. Loose bones of Lower jaw (mandible).

Basihyal:

Basihyal is an elongated, median, rod-like structure and forms the body proper of hyoid apparatus. Its tapers anteriorly into lingual process or os-entoglossus.

Anterior Cornua:

The anterior cornua are elongated cartilaginous rods ventrally connected with the basihyal and going upwards curving round the gullet and finishing on the ventral surface of the auditory capsule of their side. Each anterior cornua comprises a proximal and a distal piece, they joined together by ligaments.

Posterior Cornua:

The posterior cornua are also cartilaginous two segmental rods originating from the posterior end of the basihyal and moving towards the hind end. Posterior cornua originates from branchial arches, while anterior cornua arise from hyoid arch.

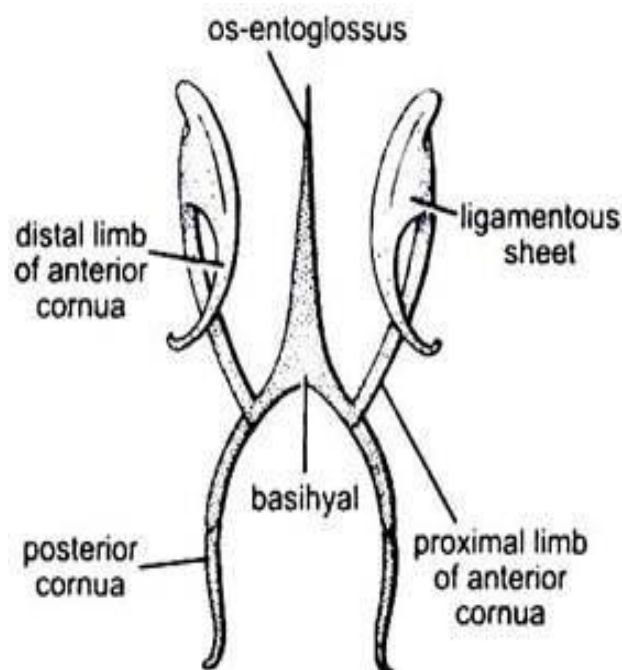


Figure.-6: Varanus. Hyoid apparatus

B. Vertebral Column ¹:The vertebral column comprises of a large number (83-85) of vertebrae. Epiphyses are absent and centra of vertebrae are completely procoelous. The vertebral column is divided into four parts: The cervical containing 8 vertebrae, the thoracolumbar consists of 22 vertebrae, the sacral having only 2 vertebrae, and the caudal with about 51-53 vertebrae. The detail of these vertebrae are given below (figure-7).

(i) Cervical Vertebrae:

These are 8 in number. A typical cervical vertebra consists of a elongated and stout centrum which is anteriorly concave and convex posteriorly, i.e., procoelous. Neural spine is crest-like. Prezygapophyses present at the anterior surface of neural arch are directed upwards and outwards, while postzygapophyses present on the posterior surface of neural arch are directed downwards and inwards. On the ventral surface, the posterior part of the centrum carries a backwardly directed hypapophysis. On the outer anterior surface the centrum bears articular facets for cervical ribs. Articular facets are present behind the third cervical vertebra.

(a) Atlas Vertebra:

Atlas vertebra is the first vertebra of cervical region. It is small and ring like in shape. It has no distinct centrum. It consists of three distinct bony pieces from which two are dorso-lateral and one ventral around the neural canal. The neural canal in living animals is divided by a ligament into the dorsal and ventral portion which is downwardly projected into a small spine. Ventral piece occupies the position of centrum.

The dorso-lateral pieces have a space filled by a membrane at the point of their union in the mid-dorsal line. Along the anterior face of the ventral piece is present, a cavity for the articulation of occipital condyle of the basioccipital of skull. On the posterior side of the ventral piece is also found an articular facet for the odontoid process of the axis vertebra. Pre- and postzygapophyses are absent. Transverse processes are completely absent.

(b) Axis Vertebra:

This vertebra is the second vertebra of the cervical region. It is similar to the typical cervical vertebra in structure but it is slightly larger and carries a posteriorly directed hook-like spine below the odontoid process and originating from the centrum.

The neural spine is vertical crest-like. It is characterised by the presence of an odontoid process at the anterior face of centrum.

Below the odontoid process, from the anterior end of centrum arises a backwardly directed hook-like spine. It represents the hypapophysis or intercentrum of atlas vertebra. A hypapophysis is also present on the ventral surface of the centrum in the posterior region. Prezygapophyses are rudimentary represented by simple notches while postzygapophyses are well developed.

(ii) Thoraco-Lumbar Vertebrae:

Thoraco-lumbar vertebrae situated in the thoracic and abdominal regions. Thoraco-lumbar vertebrae are similar to cervical vertebrae but they are slightly larger in size and do not possessed hypapophysis. Centrum is procoelous. The vertical crest-like neural spine is present. Pre- and postzygapophyses are found. On either side at the junction of the neural arch and centrum is present a capitular facet for fusion with the single-headed thoracic rib.

(iii) Sacral Vertebrae:

Both the sacral vertebrae are tightly united. These are strong and supporting to the pelvic girdle. Anterior or first sacral vertebra is more stout than the second vertebra. Its centrum is short and completely procoelous. The crest-like neural spine is also present. Pre- and postzygapophyses are well developed while hypapophysis is absent. Transverse processes are strong and disbursed at the tips which are also grooved to receive a part of the ilia bones of the pelvic girdle. Posterior or second sacral has also short, stout and completely procoelous centrum, neural spine is short and crest-like, and zygapophyses well developed. The transverse processes though expanded but not notched at the tips.

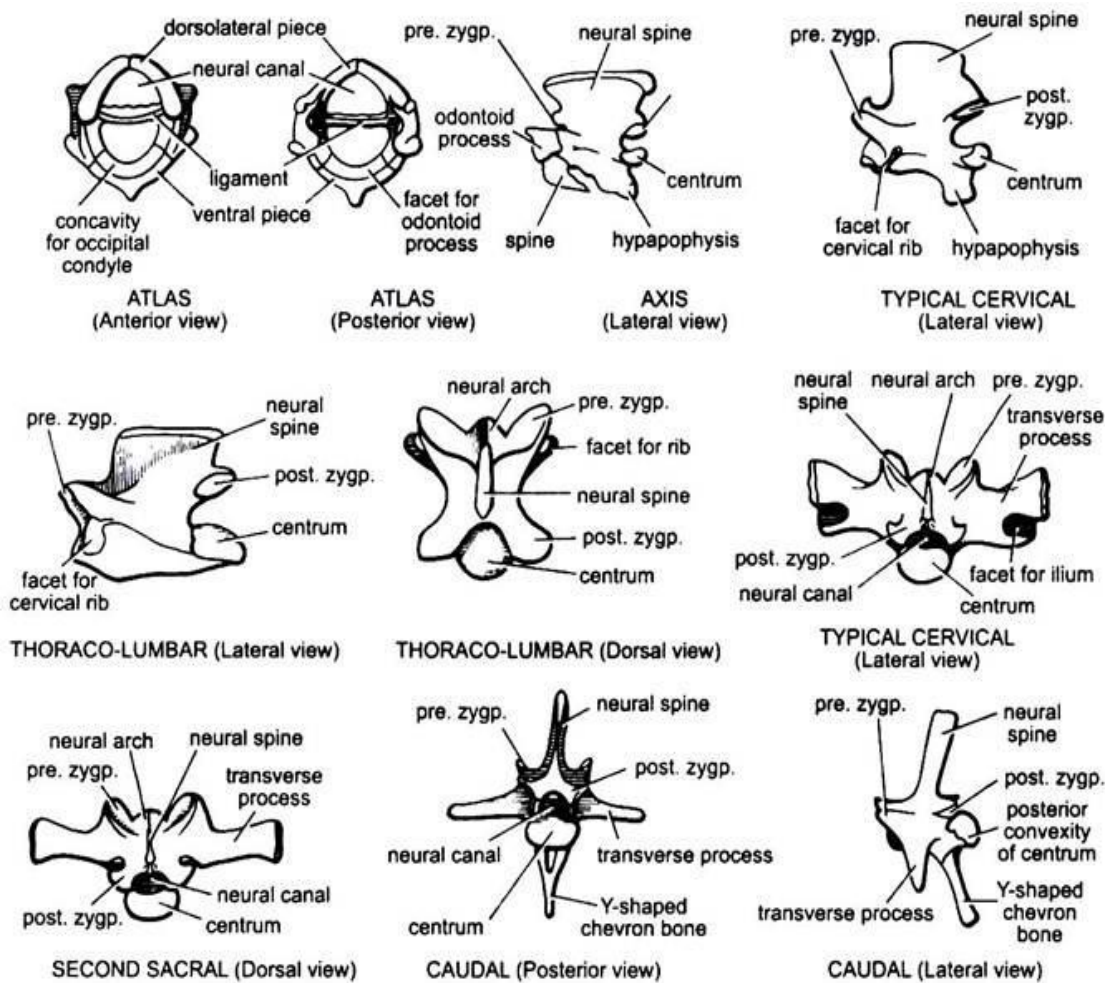


Figure27: *Varanus*. Vertebrae.

(iv) Caudal Vertebrae:

The caudal vertebrae gradually become smaller towards the posterior end, consequently getting reduced to bony rod-like centrum. Anterior caudal vertebrae: In the anterior caudal vertebrae the centrum is longer and highly procoelous. The neural spine is long, pointed and directed backwardly. Pre- and postzygapophyses are well developed. Transverse processes are long, slender, directed outwardly and downwardly. The most identifiable feature of the vertebra is the occurrence of Y-shaped chevron bone attached to centrum ventrally which carries two nodules for this purpose. Y-shaped chevron bone has two haemal arches attached to centrum ventrally and a long downwardly directed haemal spine.

It surrounds the haemal canal through which the artery and vein passes. Posterior caudal vertebrae: Posterior caudal vertebra is anatomically similar to the anterior caudal vertebrae except the absence of chevron bone. The various processes also become gradually reduced in size.

C. Sternum¹:

The breast bone or sternum is like rhomboid plate in shape made-up of calcified cartilage lying embedded in the thoracic wall ventrally (figure-8). Its antero-lateral borders fuses with the coracoids and epicoracoids of the pectoral girdle. Along its each postero-lateral border it bears two small facets for fusion with the 2 sternal ribs. Two sternal ribs are also carried by it at the posterior end. The interclavicle bone is found and its T shaped elongated stem lodged in a groove on the mid-ventral surface of sternal plate. A pair of slender curved rods, the clavicles, are adopting to the anterior cross-piece of the interclavicles (figure-9).

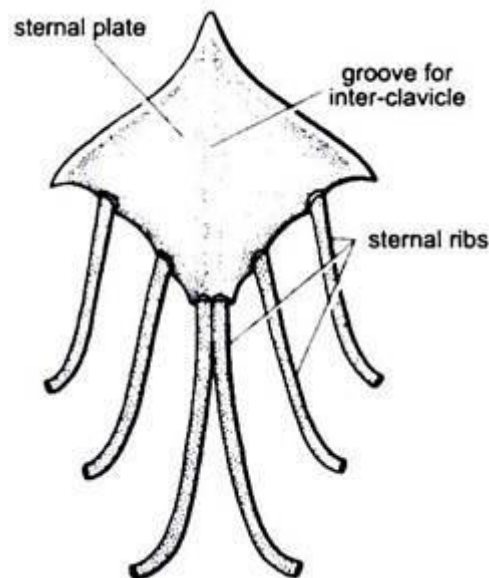


Figure-2.8: Varanus. Sternum.

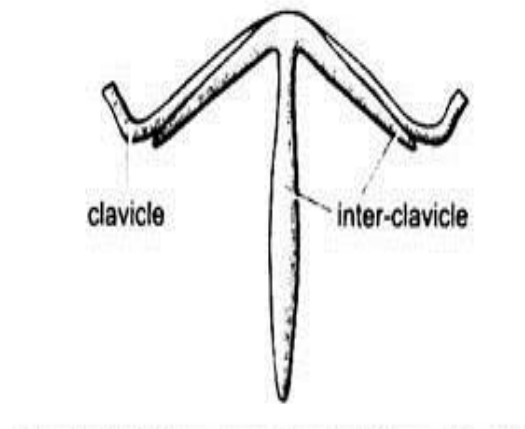


Figure2.9: Varanus. Interclavical and clavical.

(D) Ribs:

Ribs are unicephalous (single-headed). Their upper ends fuses with the capitular facets of corresponding vertebrae. Tubercular facets are not found. Ribs are curved, may be bony or bony and cartilagenous. Except first three cervicals, all the cervicals, thoracic and lumbar vertebra carries ribs.

(i) Thoracic Ribs:

These are larger and developed into a dorsal bony vertebral region fusing with the vertebra and a ventral cartilaginous sternal portion. First three thoracic ribs fuse with the sternum by their cartilaginous sternal parts. Remaining thoracic ribs do not fuse with the sternum and thus, remain free (figure-10).

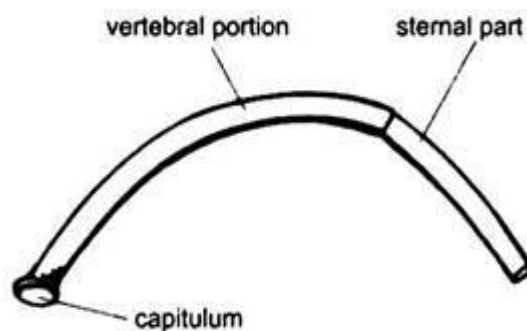


Figure-2.10: Varanus. Thoracic ribs.

(ii)Cervical Ribs:

Except first three cervical , all the remaining ones have cervical ribs. These are short and remain free ventrally and have no cartilaginous sterna part.

2. APPENDICULAR SKELETON ^[8]: The appendicular skeleton of *Varanus* consists of

(A) Pectoral Girdle (B) Pelvic girdle (C) Fore limb (D) Hind limb

(A) Pectoral Girdle:

The pectoral or shoulder girdle is located at the anterior end of the trunk. It surrounds and protects the heart and lungs along with the sternum , ribs and also provides articulation to the bones of forelimbs. The pectoral girdle is consists of two similar (rami) halves one lying on either side of the interclavicle bone which is T shaped and sternum. Each half of the pectoral girdle comprises scapula, suprascapula, coracoid and epicoracoid bones [Figur-11].

(i) Scapula:

Scapula is ossified material, oblong and flat plate,in middle it is narrow. Its outer broader end fuses with the suprascapula, on other hand, its inner narrow end joins to coracoid. Its lower posterior end makes a part of the glenoid cavity and its dorsal anterior end gives rise an ossified process called the mesoscapula.

(ii)Suprascapula:

Suprascapula is thin, more or less rectangular plate of calcified cartilage with a free distal margin. It fuses proximally with the scapula while its distal margin is free.

(iii)Coracoid:

Coracoid is broad, flat and cavities bone. It is partly ossified and partly cartilaginous.Two large fenestrae divide the coracoid into outer procoracoid, middle mesocoracoid and inner coracoid proper. Inner anterior part of coracoid is cartilaginous forming the epicoracoid. It lies above the two fenestrae. Epicoracoid meet with the posterior long arm of interclavicle and sternum.

(iv) Interclavicle or Episternum: Interclavical or episternum is a T-shaped bone located in between the two halves of pectoral girdle. Its lateral curved limbs lie anterior to the scapulae and the posterior long limb is closely set to the mid-ventral surface of sternum.

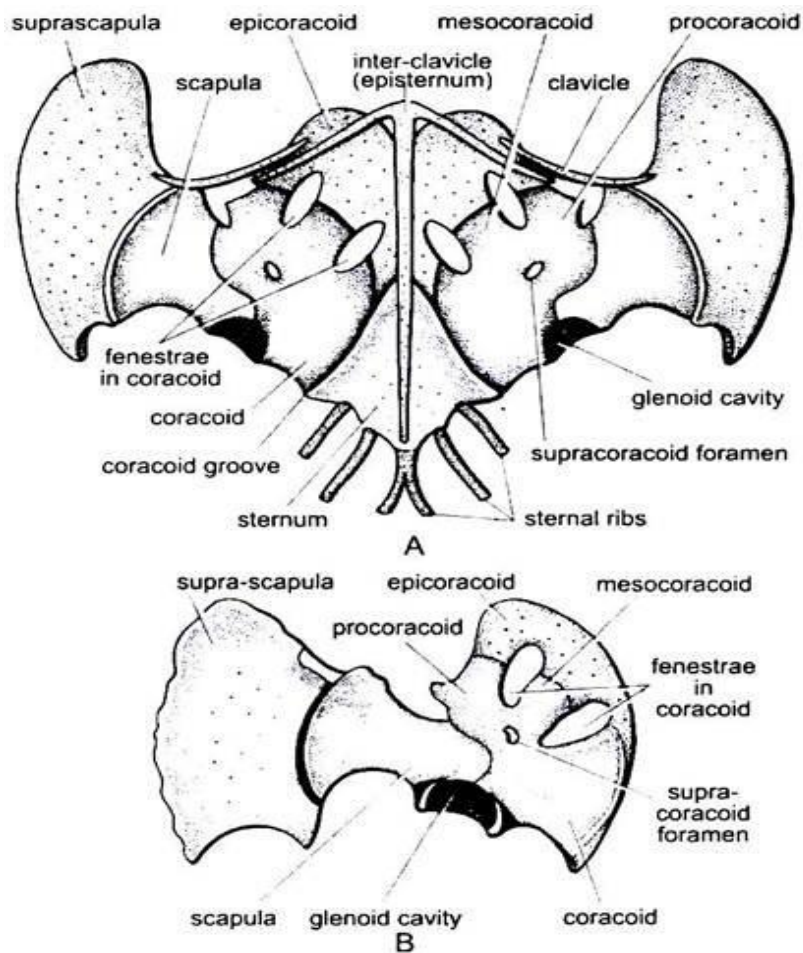


Figure-2.11: *Varanus*. (A) Pectoral girdle ventral view/. (B) A side of pectoral girdle.

(v) Clavicle:

It is a small curved narrow bone attached to the anterior side of lateral limb of interclavicle. Its outer distal end fuses with the joint of scapula and suprascapula, while its inner limb does not reach up to the middle of interclavicle. At the joint of scapula and coracoid along the ventral side a glenoid cavity is present for the articulation of head of humerus.

B. Pelvic Girdle: The hip or pelvic girdle is located at the hind end of the trunk. It provides articulation to the bones of the hindlimbs. Pelvic girdle comprise two similar halves (rami) joining in the mid-line by a vertical ligament. Each half is known as os-innominatum and composed of ilium, pubis and ischium. All these three bones are not articulated with each other. At their joining points on the outer surface a concave acetabulum is found for the head of humerus (Figure-12).

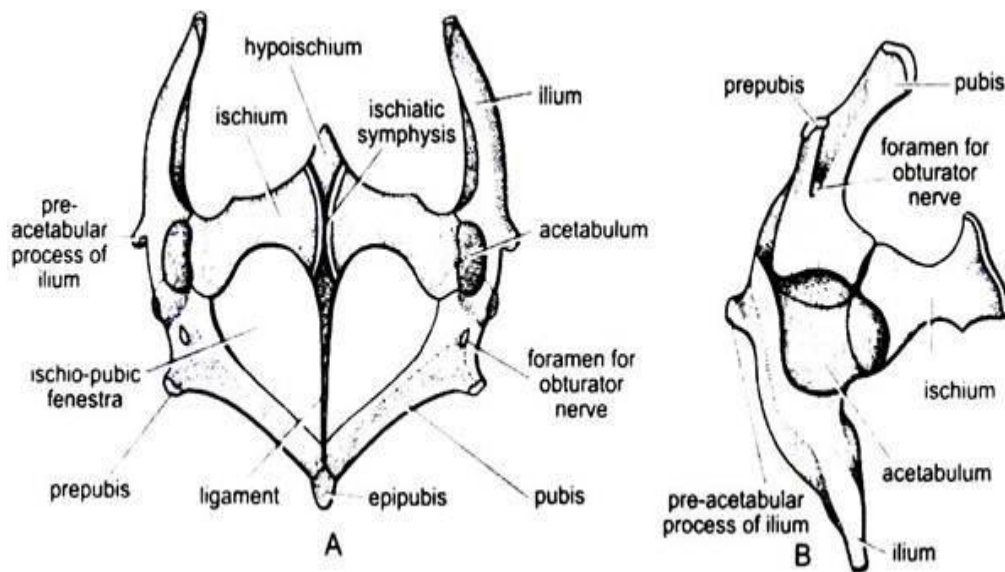


Figure-2.12: *Varanus*. A- Pelvic girdle (ventral view); B-one half of pelvic girdle.

(i) Ilium:

Ilium is compressed, strong, rod-like bone directed upwards and backwards to fuse with the sacral vertebrae (within the groove of transverse process of I sacral). On the outer side in front of the acetabulum it is produced into a pre-acetabular process and also contributes in the formation of about one-third part of acetabulum.

(ii) Pubis:

Pubis is slightly curved and flat bone, runs downwards to meet in front with its fellow of the other side in the middle line at the pubic symphysis. Between the anterior ends of two pubes the epipubis is present. Epipubis is backwardly directed nodule of cartilage made up of calcium.

On the anterior end near its fusion with the ilium and ischium it has an oval foramen for the obturator nerve. Just external and slightly posterior to the foramen is a small rod-like process called the prepubis is found, which is directed outwards. Pubis also contributes to about one-third of the acetabulum.

(iii) Ischium:

Ischium is a also fslightly curved and strong bone, runs inward to meet its fellow of the other side at the ischiatic symphysis. It fuses on the outer side with the pubis and ilium of its side. A small rhomboidal piece of calcified cartilage called hypoischium is present in between the two ischia at the anterior face of ischiatic symphysis and gives streingth to the ventral wall of cloaca. Ischium also forms about one-third of the acetabulum. The acetabulum is a cup-shaped cavity, located on the outer side at the point where all the three bones of each half of pelvic girdle join with each other. It provides surface for fusion with the head of femur.

A wide space is present between the pubes and ischia of both sides which is bifurcated into two lateral ischio-pubic fenestrae by a median ligament.

C.Forelimb and hand bones:

The forelimb comprises humerus, radius and ulna, and the bones of forefoot.

(i) Humerus:

Humerus is the bone of the upper arm of the forelimb. It has an elongated rod. Its both the ends 4of which are expanded and covered by cartilage called epiphyses. The proximal end carries the round head which fits into the glenoid cavity of the pectoral girdle. Below the head a prominent crest-like deltoid ridge is present . A bicipital fossa is surrounds between the medial process of proximal end and head. The distal end has a pulley-like articular surface called trochlea, is divisible into radial condyle and ulnare condyle by which it fuses with the radius and ulna.

(ii) Radius and Ulna: Radius and ulna are the bones of forearm of the forelimb. Radius is slender and contain a shaft and two epiphyses. At the distal end of radius is present a concave articular facet for the carpus and a preaxial styloid process. Ulna is allmost stouter situated on the outer side of the radius. The anterior end of ulna is produced into an upwardly directed

olecranon process, whereas near the posterior end it bears a concave articular surface for the carpus (figure-13b).

(iii) Forefoot:

Carpus or wrist consists of ten bony polyhedral carpals arranged in three rows. The proximal (anterior) row contains three carpals- radiale, ulnare and intermedium. The middle row has only one carpal, called centrale. The distal (posterior) row has five small carpals. Besides the above, a pisiform is attached to the distal epiphysis of the ulna on its post-axial side.

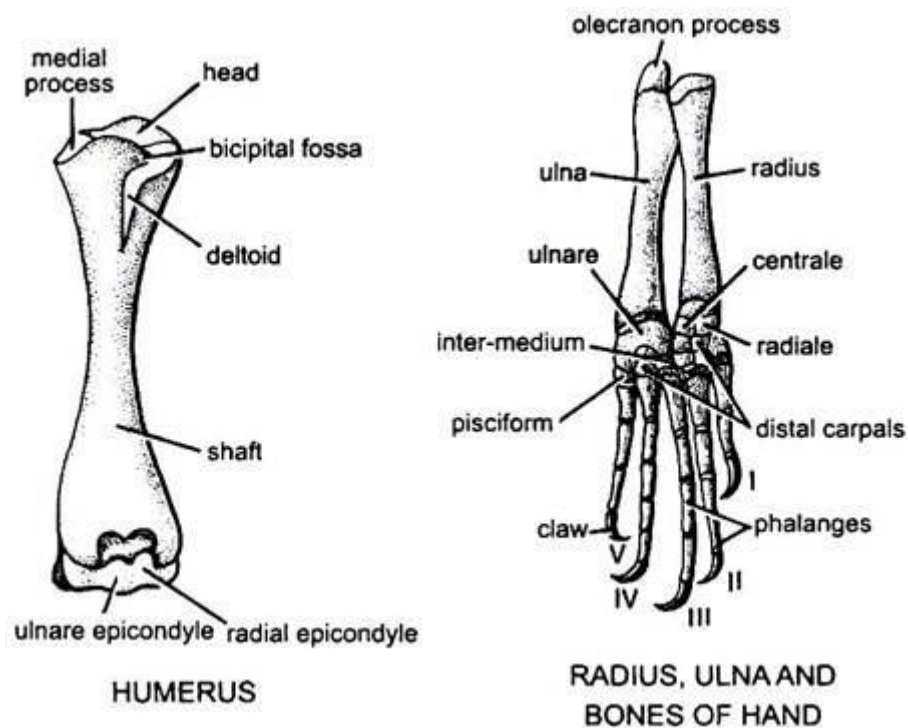


Figure-2.13 a and 13b: *Varanus*. Forelimb bones (Humerus and Radius and Ulna).

Manus:

The digits are five each consists of a metacarpal and phalanges which are varying in number i.e., 2, 3, 4, 5 and 3. The terminal phalange has a horny claw.

D. Hindlimb and foot bones:

The hindlimb consists of femur (thigh bone), tibia and fibula, and the bones of hindfoot.

(i) Femur:

Femur is the bone of thigh bone. It is a stout bone having an elongated rod having two epiphyses. The proximal end has a rounded head which fits into the acetabulum of pelvic girdle. A bit posterior to the head, on the pre-axial side is the prominent lesser trochanter and the greater trochanter located on the post-axial side which is greatly reduced. The distal epiphysis is pulley-shaped having two condyles(out growth) for the articulation of tibia and fibula and a tuberosity in between the two(figure-14a).

(ii)Tibia and Fibula:

Tibia and fibula are the bones of the shank of hindlimb. Tibia is a stout bone and possesses a longitudinal ridge, the enemial crest, along the anterior or dorsal surface. The proximal end of tibia possesses two concave facets for the fusion with the condyles of femur. Fibula slender bone proximally fuses with the distal tuberosity of the femur. The distal end of both tibia and fibula provide surface for the fusion with the tarsals (Figure-14b).

Tarsals: Tarsus consists of only 5 tarsal bones, arranged in two rows. In the proximal row there are 2 tarsals and the distal row consists of 3 tarsals. Two tarsals of the proximal row are suturally fused with each other and articulate with tibia and fibula. The distal row comprises three cuboid tarsals fusing with the five metatarsals of the foot. The number of phalanges in each toe is variable- the first toe has 2, second toe has 3, third toe has 4, fourth toe has 5 and fifth toe has 3 phalanges. The terminal phalange of each toe has a horny claw(Figure-14b)

Page-40

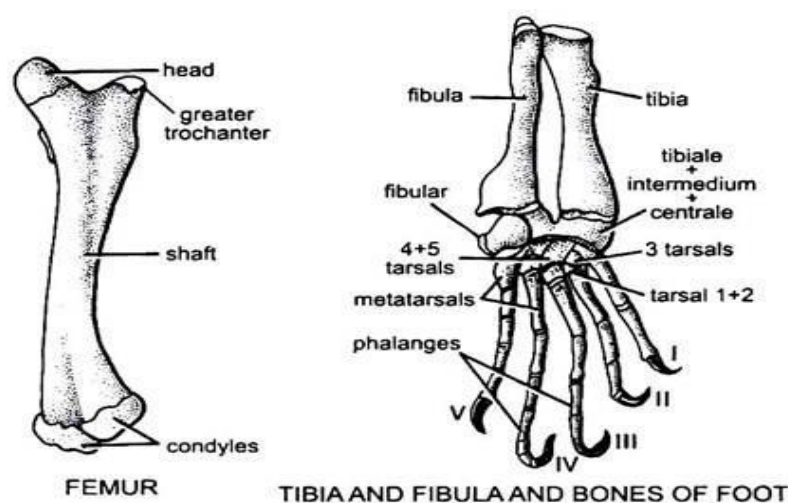


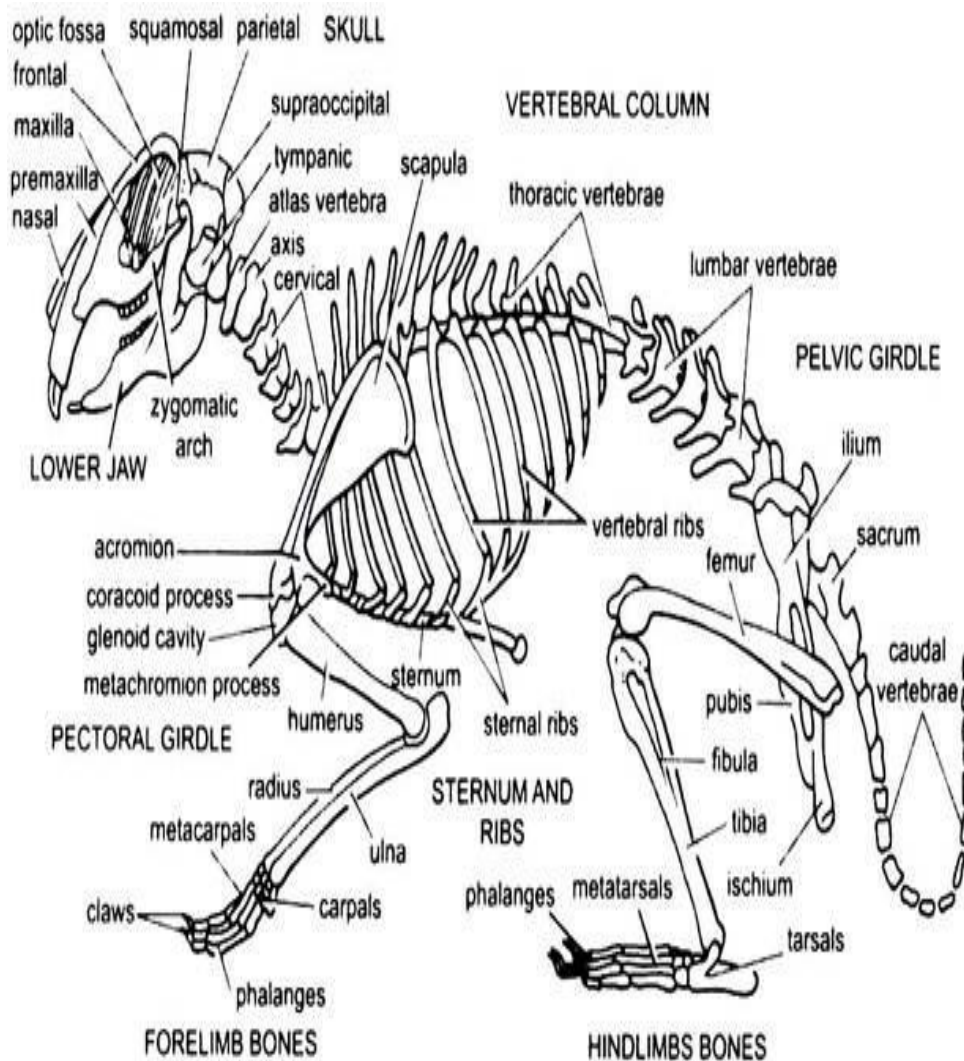
Figure 2.14a - Femur, 14b- Tibia and Fibula(bones of hindlimb and foot)

References:

- 1.https://en.wikipedia.org/wiki/Monitor_lizard
- 2.https://www.notesonzoology.com/wp-content/uploads/2017/07/clip_image004-84.jpg
- 3.https://www.notesonzoology.com/wp-content/uploads/2017/07/clip_image004-84.jpg
- 4.https://www.notesonzoology.com/wp-content/uploads/2017/07/clip_image004-84.jpg
- 5.https://www.notesonzoology.com/wp-content/uploads/2017/07/clip_image004-84.jpg
- 6.https://www.notesonzoology.com/wp-content/uploads/2017/07/clip_image004-84.jpg
- 7.https://www.notesonzoology.com/wp-content/uploads/2017/07/clip_image004-84.jpg
- 8.https://www.notesonzoology.com/wp-content/uploads/2017/07/clip_image004-84.jpg

2.3 SKELETON STUDY OF RABBIT (ORYCTOLAGUS)

The articulated endoskeleton of rabbit is mainly consists of bone and cartilaginous part is very less. Like those of other vertebrates, the skeleton of rabbit can also be divided into two parts: (i) The axial skeleton is present along the longitudinal axis of the body and made up of the bones of skull, the vertebral column, the ribs and the sternum. (ii) The appendicular skeleton lies at right angle to the longitudinal axis of the body and consists of the bones of limbs (forelimbs and hindlimbs) and the girdles (Pectoral and Pelvic Girdle). The complete endoskeleton of *Oryctolagus* is shown in Figure-1. In this unit we will study the articulated (fused) endoskeleton of rabbit.



Figur-2.3.1: Complete fused endoskeleton of Oryctolagus.

1. AXIAL SKELETOL :

A .SKULL:The skull of the rabbit can be divided into: (i)Cranium which surround the brain(ii) Sense capsules (olfactory, auditory and orbital) closely attached with the cranium(iii)Visceral skeleton includes the upper and lower jaws and hyoid apparatus the (Figure-2 and 3).

Characteristics of mammalian skull:

- Mammals are advanced vertebrate since there is a general tendency to increase in the size of the brain, the skull has a short posterior cranial part for lodging the brain and the long anterior facial part consists of mainly the jaws. In higher mammals the facial part lies below the cranial part.

- Skull is dicondylic, i.e., 2 occipital condyles. Each exoccipital bears an occipital condyle.
- The number of bones in the skull is much reduced, many of them are articulate intimately so that their separating boundaries are determined only by the sutures.
- Skull is Tropibasic (*skull* with a narrow base and close-set orbits). A vertical interorbital septum is found in between two orbits. Cranium does not extend into orbital region.
- The food passage is completely separated from the nasal passage due to the development of a palate which is formed by the fusion of premaxillae, maxillae and palatines.
- A zygomatic arch on both side of the skull is made by squamosal, jugal and maxillary bones.
- The auditory capsules are formed by the fusion of periotic and tympanic bone, which forms a swollen tympanic bulla.
- The articular and quadrate bone of the jaws become separated and remain free, and form malleus and incus respectively (two ear-ossicles of the three). Stapes makes the columella.
- Otic , prootic, epiotic and opisthotic bones, are articulated to form a single periodic

bone. Dental formula of rabbit is = $i \frac{2}{1}, c \frac{0}{0}, pm \frac{3}{2}, m \frac{3}{3} = 28$

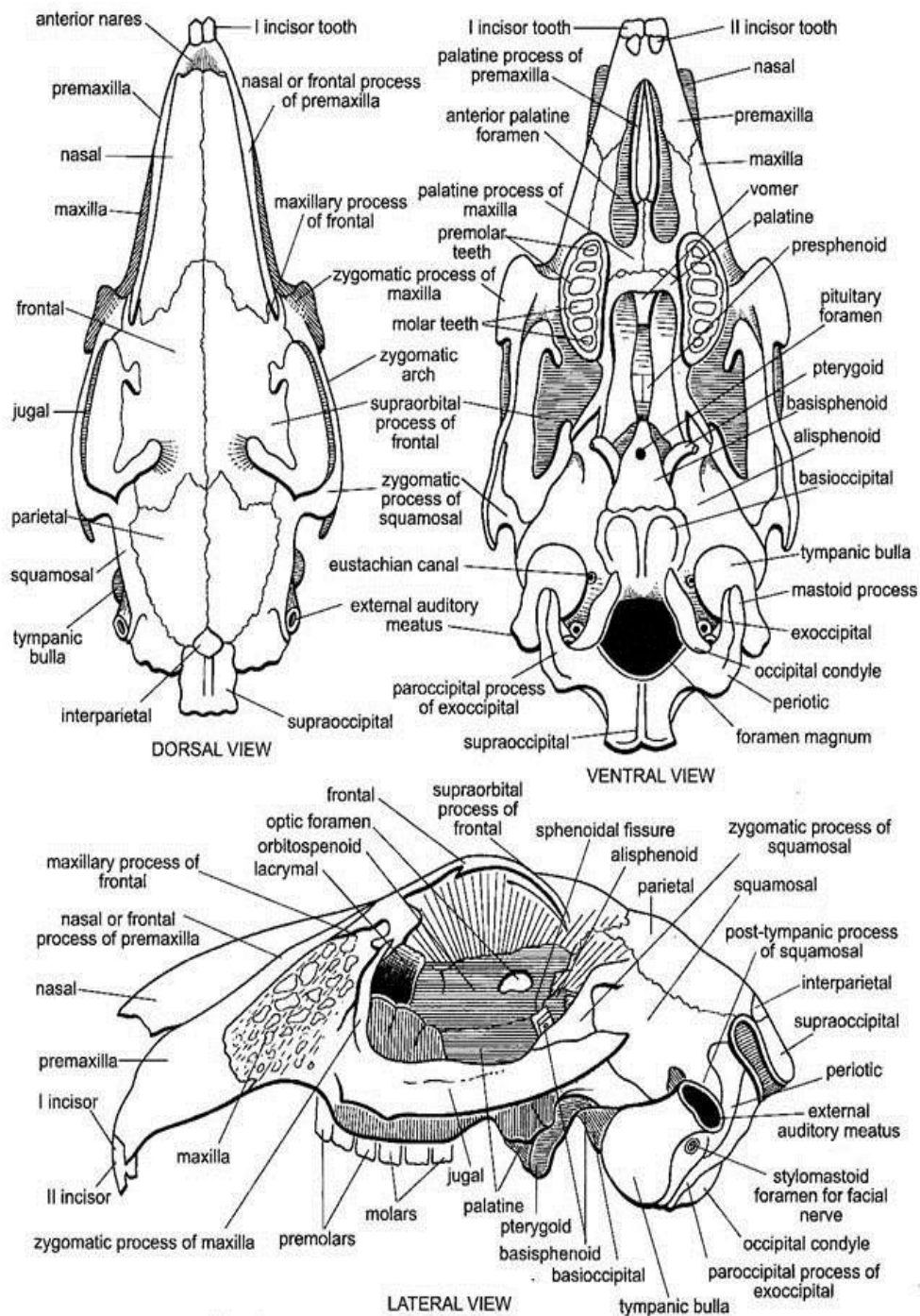


Figure-2.3.2 Skull of *Oryctolagus*. (A) Dorsal View (B) Ventral View (C) Lateral View

(a) **Cranium:** The cranium consists of various bones and be kept into three segments, a posterior occipital compartment, middle parietal compartment and anterior frontal compartment.

- Turbinal bones are very much folded thus, increases the olfactory surface of nasal compartment.
- Only a single bone called dentary makes one half of the lower jaw.
- Jaws suspensorium is craniostylic type, i.e., dentary bone fused with the cranium by squamosal.
- Prefrontal, postfrontal, parasphenoid and quadratojugal bone are lacking. Pterygoids bone is scale-like.
- Premaxillae, maxillae and dentaries carries the thecodont teeth (teeth embedded in sockets). Teeth are diphyodont (milk and permanent) and heterodont (different types). Canines teeth are absent in place of canine a space, called diastema is found.

(a) Cranium: The cranium consists of various bones and be kept into three segments, a posterior occipital compartment, middle parietal compartment and anterior frontal compartment.

(i) Occipital Segment:

Occipital segment is the hindermost (posterior) part of the cranium. It consists of four cartilaginous bones completely articulated with each other and encloses a large passage, the foramen magnum, through which spinal cord comes out. The bone making the dorsal margin of the foramen magnum is flat shield-like square-shaped called supraoccipital, the ventral boundary is marked by a flat bone called basic occipital, and the lateral boundaries are marked by a pair of exoccipitals bone. Each exoccipital carries a conspicuous oval or a somewhat long occipital condyle and also gives off a downwardly directed paroccipital process which is situated in close contact with postero-ventral surface of tympanic bulla off a supraoccipital bone fuses in front with the parietals bone, and on lateral sides with the squamosals and periotics bone.

(ii) Parietal Segment:

It is present anteriorly of occipital segment. On lateral sides, both are separated from each other by auditory capsules and squamosals bone. It comprises five bones, a triangular basisphenoid bone on the ventral-mid side, alisphenoids on lateral sides and two parietals and an interparietal bone on the dorsal side.

- **Basisphenoid and Alisphenoid:**

Basisphenoid is a median triangular, flat and cartilaginous bone. Its apex joins anteriorly with the presphenoid and its broad posterior end is attached with the basioccipital by a thin cartilaginous plate.

Dorsal surface of basisphenoid has a depression called the sella turcica, in which pituitary gland is lodged. Basisphenoid also carries a pituitary foramen at about its middle. Basisphenoid laterally fuses with the alisphenoids bones. The alisphenoids are broad wing-like and tightly united with the basisphenoid.

Each alisphenoid is produced below into a bi-laminated process called the pterygoid process, connected with the palatine bone and bounded in front by a slit-like structure called sphenoidal fissure (foramen lacerum anterius) which opens into the cranial cavity.

- **Interparietal:**

It is a small, median wedge-like, triangular bone which is on the dorsal side in between parietals and supraoccipital bone.

- **Parietal:**

The parietal bones are a pair of thin, slightly arched bones and protecting the brain dorsolaterally. Both the parietals are tightly fused with each other by a suture along the mid-dorsal line. They remain separated from alisphenoids by the squamosal bone. Each parietal bone gives rise to a ventral process from its posterior outer border which extends beneath the squamosal bone.

- **Squamosal:**

It is roughly a rectangular bone located on ventral to parietal on either side. Outer surface of squamosal is produced into a strong zygomatic process which makes the posterior part of zygomatic arch. It anteriorly unites with jugal bone in the formation of a complete zygomatic arch. Below the root of the process is a hollow glenoid fossa for articulation with the condyle of mandible is found. Squamosal from its posterior side gives rise to a slender process called the post-tympanic process, which becomes applied to the outer surface of the petrous bone.

(iii) Frontal Segment:

This segment also consists of five bones, a presphenoid ventrally, two orbitosphenoids one on either side and two frontals dorsally.

- **Presphenoid and Orbitosphenoids:**

Presphenoid bone makes the floor of the frontal region of cranium. It is a thin, median, small bone situated in front of the basisphenoid bone and attached with it by a cartilage. The presphenoid bone makes the lower and anterior margin of the optic foramen. Orbitosphenoid bones are attached with the lateral sides of the presphenoid bone. These form the sides of the frontal region.

- In rabbit orbitosphenoids are partially articulated and form a thin, vertical median interorbital septum, which encloses the optic foramen. These bones form the lateral wall of cranium and orbits. Orbitosphenoids fused with palatine in front, with frontals above and behind with the squamosals and alisphenoid bone.
- **Frontal:** The frontals are strong, large bones and protect the brain from the dorsal and lateral sides. Both the frontals are fused with each other by a suture along the mid-dorsal line. Outer middle part of each frontal forms a strong ridge over the orbit called supra-orbital process. Frontals fuse posteriorly with the parietals and anteriorly with the nasals. A slender maxillary process arises from the anterior side of each frontal passing in between the premaxilla and maxilla bone. On the ventral side each frontal bone fuses with the orbitosphenoid bone.

(iv) Ethmoidal Region:

It is located anterior to the cranial cavity and is not well separated from olfactory capsules. It has a single bone that is mesethmoid. It is a median vertical bone which extends progressively forwards and downwards in front of presphenoid bone. The two olfactory chambers are separated from each other by nasal septum. Posterior part of mesethmoid makes a narrow bony plate called cribriform plate, which makes the anterior boundary of the brain case. It is cracked by small foramina through which olfactory nerve fibers enter the cranial cavity.

b. Sensory Capsules:

Sensory capsules are olfactory containing the organs of smell, auditory containing organs of hearing and orbits for eyes. These are closely fused with the cranium.

(i) Olfactory Capsules:

Nasal:

Roof of olfactory compartment is formed by two flat bones called the nasals which fused with each other in the mid-dorsal line. Each nasal has on its inner surface a very thin, hollow process known as the nasoturbinal. Anterior end of each nasal makes the upper margin of external nostril. Each nasal fused laterally with the premaxilla.

Vomer: Two vomers are long slender articulated bones making the floor of olfactory capsules. These dorsally fuses with ventral (inferior) edge of the mesethmoid (nasal septum). Vomers bears delicate lateral wings.

Turbinals : Each nasal or olfactory compartment or cavity remain separated from other cavity by a median septum, partly cartilaginous, partly bony by the mesethmoid, consists of turbinals or turbinate bones of its side. These are ethmoturbinals, maxilloturbinal and nasoturbinal respectively.

(ii) Auditory Capsules: The auditory capsules are closely fused with the postero-lateral region of the cranial region of the skull. Each capsule is formed by the fusion of two bones namely, the periotic and tympanic, and surround the internal ear.

Periotic:

Each periotic is an irregular cartilaginous bone formed by the fusion of prootic, epiotic and opisthotic bones. It is located in between squamosal and occipital segment and externally visible forming a bulge and perforated in the adults.

The periotic consists of two parts:

- An internal, bony, hard, petrous part and
- An outer posterior porous mastoid part which is turned downwards into a mastoid process which is closely applied to the posterior side of tympanic.

Petrous part carries two apertures—an anterior fenestra ovalis and another posterior fenestra rotunda. It also carries a ventral rounded swelling called the promontory for lodging the cochlea.

Tympanic:

It is a flask-shaped membrane bone attached to the outer surface of the petrous bone. Its lower, flask-shaped swollen part is called tympanic bulla. It surrounds the tympanic cavity of middle ear containing three ear ossicles arranged linearly-the malleus, incus and stapes. The neck of the flask makes the external auditory meatus closed at the base by the tympanic membrane. Tympanic on its posterior side possesses a stylomastoid foramen for the facial nerve.

(iii) Orbits: The orbits are located on the sides of the frontal segment of the cranial region. The two orbits are separated by a median bony inter-orbital septum. Each orbit has a median wall formed of dorsal frontal which projects above the orbit as supra-orbital ridge, median ventral orbitosphenoid, alisphenoid and ethmoid bones. The outer side of the orbit is covered or (protected) by the zygomatic arch and the lower side of the orbit is unossified.

(c) Visceral Skeleton: Visceral skeleton consists of upper and lower jaws and hyoid apparatus.

(i) Upper Jaw:

Upper jaw consists of premaxillae, maxillae, jugals, pterygoids and palatines bones. These are closely attached with the cranium and olfactory capsules.

Premaxillae: These are large bones and make the front (anterior) part of the upper jaw. Both the premaxillae unite in front in the median line. Each premaxilla ventrally carries two sockets for incisor teeth. Each premaxilla also carries two processes-a nasal process extending backward up to frontal in between nasal and maxilla; a palatine process (ventral) which joins with its fellow of other side in the mid-ventral line and both extend up to palatine processes of maxillae.

Maxilla:

Maxilla is a large, irregular-shaped bone forming the larger part of the upper jaw and side of the face. There are 6 sockets on the ventral surface of maxillae for the cheek teeth. Each maxilla

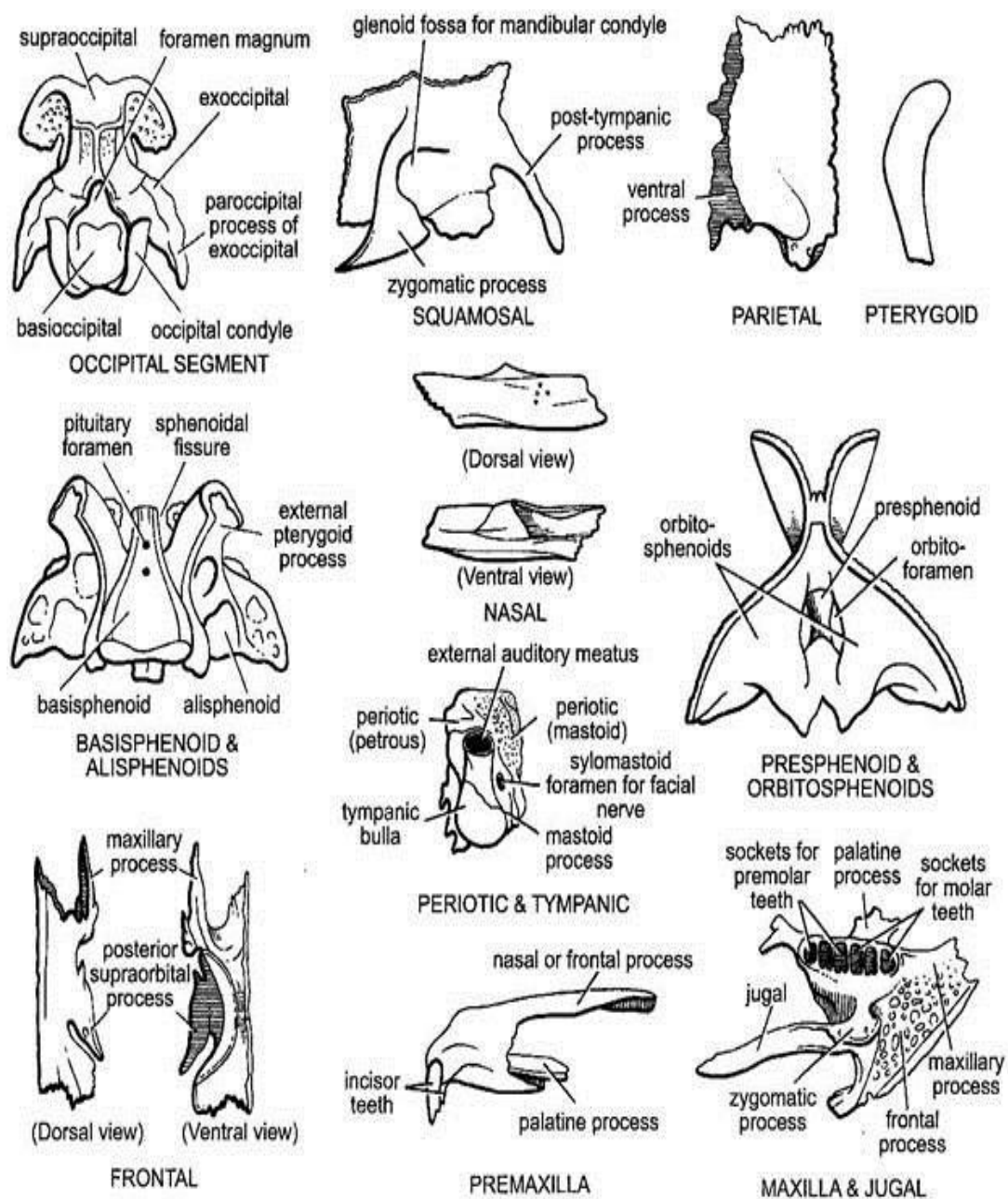


Figure-2.3.3: Rabbit. Loose bones of skull.

Maxilla:

Maxilla is a large, irregular-shaped bone forming the larger part of the upper jaw and side of the face. There are 6 sockets on the ventral surface of maxillae for the cheek teeth. Each maxilla gives off a number of processes. A median flat palatine process is given out from the ventral surface of each maxilla. Both the palatine processes are fused by a suture in the middle line forming the anterior part of hard palate.

A flat stout process from the outer surface of each maxilla is known as the zygomatic process. It passes backwardly and joins with a similar forwardly directed process of the squamosal, thus, making the zygomatic arch. Each maxilla anteriorly gives off a maxillary process which joins with the premaxilla.

Palatine: The palatines are thin, more or less vertically situated bones in the mid-ventral side. Both palatines form an inner process in front, which join together to form the posterior part of hard palate. Each palatine posteriorly fuses with the alisphenoid and pterygoid bone and surrounds a pterygoid fossa between it and basisphenoid.

Pterygoid:

The pterygoids are small, irregular, bony plates located behind the palatines and joined with the pterygoid process of alisphenoids behind.

Jugal:

Molar or jugal is a laterally compressed bone which extends in between zygomatic processes of maxilla and squamosal. It forms the larger part of the zygomatic arch.

(ii) Lower Jaw:

The lower jaw comprises of two halves (rami) which are united in front by the mandibular symphysis. Each ramus is made up of a single bone, called dentary or mandible. Each dentary has a horizontal part which having the sockets for the attachment of teeth like incisors, premolars and molars, and a gap without teeth, called the diastema. The posterior vertical or ascending part of dentary carries the articular surface or condyle for fusion with the glenoid cavity of squamosal. In front of the condyle is the compressed coronoid process. On the postero-lateral surface of the mandible is present a slight depression known as mesenteric fossa, in which large masseter muscles are attached.

With the medial side of coronoid process the temporal muscle is attached. The posterior, lower border of the dentary gives off a rounded and inwardly directed angular process. Dentary has an inferior dental or mental foramen on the outer anterior surface of dentary and on the inner side the mandibular foramen is present.

(iii) Hyoid: In rabbit the hyoid is bony and consists of a small stout thick body, known as basihyal, occurs transversely between the two halves of mandible and bears two pairs of cornua or horns. The small anterior cornua or ceratohyals are located below the tongue and

consists of a series of small bones namely, ceratohyal, epihyal, stylohyal and tympanohyal. The last one is fused with the tympanic and periotic bones. The long posterior cornua directed posteriorly and consists of a single thyrohyale.

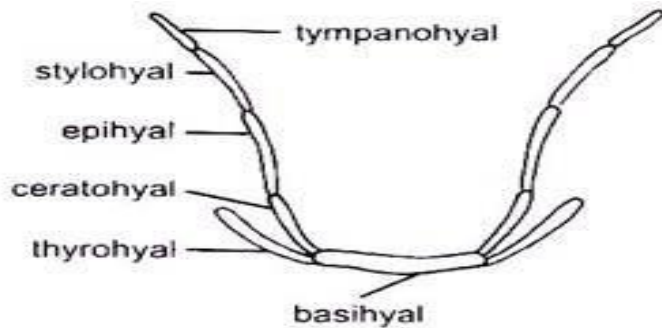


Figure-2.3.4: Rabbit. Hyoid arch

B. VERTEBRAL COLUMN :

The vertebral column of rabbit, like that of birds and lizards, divided into the following five regions and the vertebrae are known as according to the region viz, cervical vertebra etc.. The total number of vertebrae in rabbit is about 45-47.

(a) Cervical (b) Thoracic (c) Lumbar (d) Sacral (e) Coccygeal or caudal

Vertebral formula of rabbit: $C_7, T_{12-13}, L_{6-7}, S_4, Cd_{15}$ where C, T, L, S, Cd stand for cervical, thoracic, lumbar, sacral and caudal respectively. Vertebral column of mammals is distinguished from other vertebrates in the following respects.

Important Characteristics of Mammalian Vertebrae:

- The centra are more or less flattened on both the surfaces, i.e., amphiplatyan type. The centra on either side, is provided with small bony plate called epiphysis.
- A thin epiphysial cartilage divides the centrum and epiphysis in the embryonic condition, which later become fused with the centrum. Thus, in adults epiphysial cartilage is disappear.
- In between the adjacent centra are present intervertebral discs of central portion of the intervertebral disc is known as nucleus pulposus, which represents the remnant notochord. The discs are shock-absorbing structure and probably represent the hypocentrum.

(a) Cervical Vertebrae:

There are seven cervical vertebrae in rabbit, first and the second are highly modified called atlas and axis respectively. Remaining 3rd to 7th are more or less alike and known as typical cervical(Figure-5).

(i)Atlas Vertebra: It is ring-like without any solid centrum and zygapophyses. It consists of a large neural arch but a reduced neural spine .The centrum is, however, present in the embryonic condition which later fuses with the axis vertebra and known as odontoid process. The neural canal is large and divided into two regions in living condition.

The upper part is the neural canal for the passage of spinal cord and lower part is covered by the odontoid process of the axis. For articulation with the occipital condyles of skull the two large concave occipital facets are present in the anterior face of the atlas. This atlanto-occipital joint helps in movements of the head in sagittal plane, as in nodding the head. For the attachment of muscles that hold and rotate the head and neck, the transverse processes originating from the sides.these transverse process are broad, long and wing like.

The enlarged flattened cervical ribs, perforated basally by the vertebralarterial canals. A pair of lateral and a mid-ventral articular facet is located on the posterior face of the atlas for the odontoid process of axis.

(ii) Axis Vertebra:

The second cervical vertebra is axis, it is also called epistropheus vertebra. Its neural spine is high, laterally compressed, ridge like and elongated antero-posteriorly. Its centrum possesses a peg-like odontoid process in the anterior face which is developmentally the centrum of atlas. This process makes the atlanto-axial joint, which allows the rotation of the skull and atlas on the axis.

This movement is promoted by a pair of smooth articular surfaces on the anterior face of the axis one on either side of the odontoid process. The transverse processes are short and broken basally by vertebralarterial canals for vertebral artery. Zygapophyses are absent but a pair of post-zygapophyses are found.

(iii) Typical Cervical Vertebra:

A typical cervical vertebra is wide and has a small flattened centrum, small neural spine and large neural arch. Pre-and post-zygapophyses are large and well developed. Transverse

processes are bifurcated into dorsal and ventral lamellae cracked basally by a foramen transversaria or vertebral arterial canal. The cervical ribs are much reduced and more or less incorporated in the vertebra. The reduced ribs and transverse process provide surface for the attachment of neck muscles. 3rd to 6th cervical vertebrae are similar in structure but the 7th cervical differs from others because it has a more elongated neural spine, its transverse processes simple and imperforate and in the presence of a small concave semilunar facet at the posterior edge of the centrum for the articulation of thoracic ribs.

(b) Thoracic Vertebrae and ribs:

The thoracic vertebrae are 12-13 and each vertebra has a well-developed centrum with a neural arch, long neural spine and pre- and post-zygapophyses. The transverse processes are short and stout. Near its extremity each vertebra bears a small smooth articular surface or tubercular facet for the tubercle of a rib. On the anterior and posterior borders of each vertebra is a little semilunar facet, the capitular facet, located at the meeting point of the centrum and neural arch.

The neural spines of the anterior thoracic vertebrae are more or may be less straight and directed backwards. Posterior 4 or 5 thoracic vertebrae are slightly different from the anterior thoracic vertebrae. They bear longer and stout centrum, short neural spines and reduced transverse processes with no tubercular facets. Zygapophyses are quite distinct. Capitular facets are located near the anterior of centrum and neural spine is directed upward. Metapophyses is situated on the anterior end of neural arch and anapophysis is located on the posterior end of neural arch below post-zygapophyses respectively (Figure-6).

Ribs:

In rabbit 12 or 13 pairs of thoracic ribs are found fused with the thoracic vertebrae. Each rib is a bony curved rod and divided into a dorsal longer bony vertebral rib and a ventral smaller cartilaginous sternal rib. Vertebral part is double headed (bipartite), the heads are called tuberculum and capitulum which fuse with the transverse process and with the demi-facets on the centra of two adjacent vertebrae respectively. The sternal part of the rib fuses with the sternum. The sternal parts of all the thoracic ribs, except the last five, join the sternum below and are known as true ribs. The last three or four ribs are without sternal parts and they are not connected with the sternum anteriorly and, hence, called floating ribs.

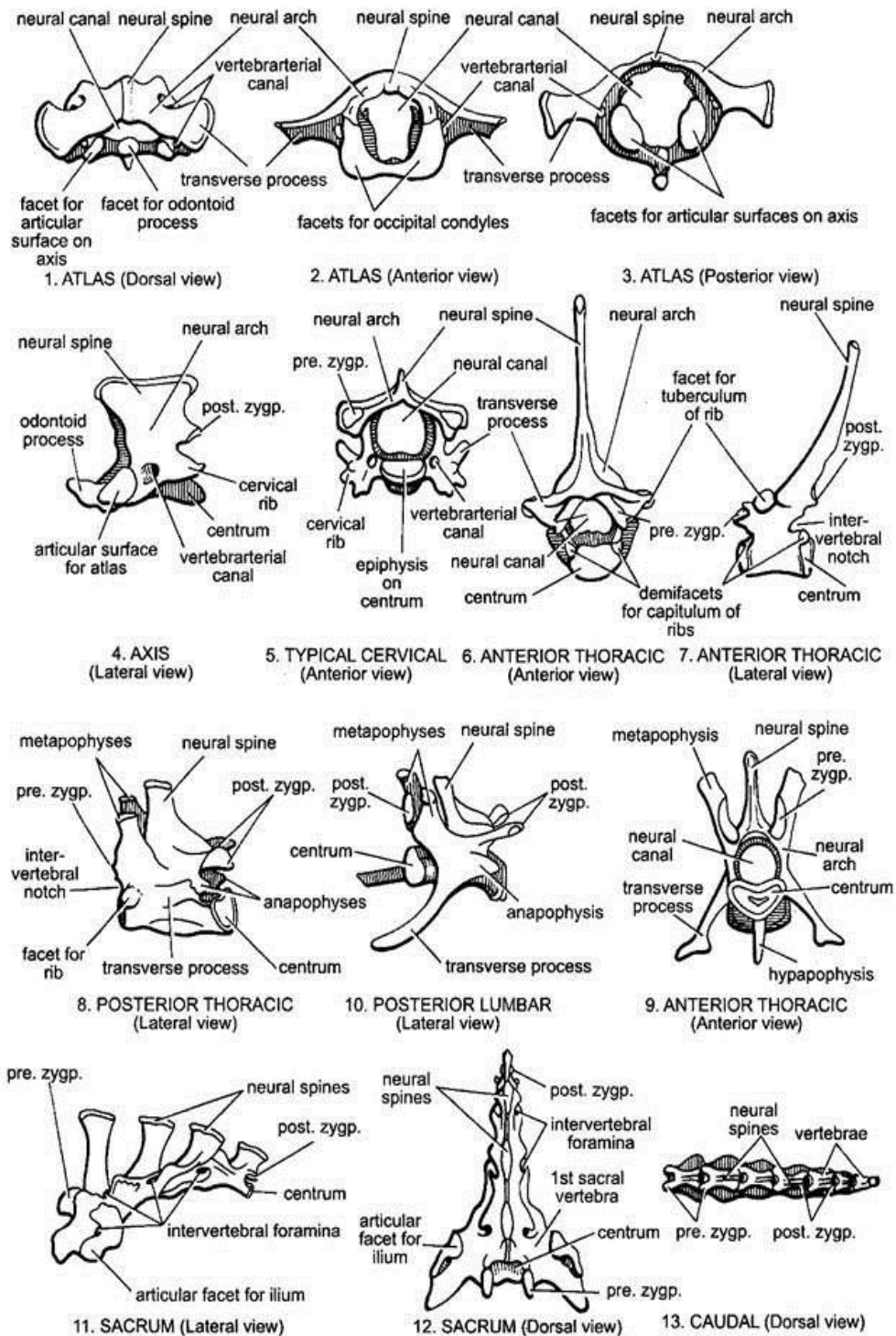


Figure-2.3.5: Loose vertebra of rabbit.

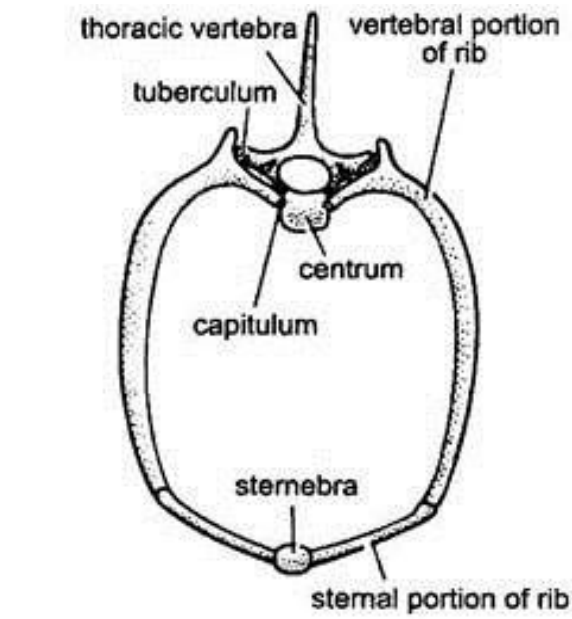


Figure 2.3.6: Rabbit. Thoracic Vertebra with ribs.

tuberculum and capitulum which fuses with the transverse process and with the demi-facets on the centra of two adjacent vertebra respectively. The sternal part of the rib fuses with the sternum. The sternal parts of all the thoracic ribs, except the last five, join the sternum below and are known as true ribs. The last three or four ribs are without sternal parts and they not connected with the sternum anteriorly and, hence, called floating ribs.

(c) Lumbar Vertebrae^[3] :The lumbar vertebrae is large with a coelous centrum. There are 7 lumbar vertebrae out of which the first 2 are called anterior lumbar vertebrae and remaining 5 are called posterior lumbar vertebrae.

(i) Anterior lumbar vertebrae^[4]: Each anterior lumbar has a large, stout, strongly built centrum, a neural arch surrounding a broad neural canal and neural spine which is well developed and forwardly directed. The transverse processes are large, distally expanded, directed downwards and forwards along with pre- and post-zygapophyses.

There are two pairs of bony processes known as mammillary processes, i.e., metapophysis is located at the anterior end of neural arch and sloping forward. Beneath metapophysis, lies the median pre-zygapophysis; anapophysis is present at the posterior end of neural arch beneath the post-zygapophysis and it is a small backwardly directed process. Beneath the centrum, called hypapophysis, each anterior lumbar also has a median ventral.

(ii) Posterior Lumbar:

From 3-7 are called posterior lumbar vertebrae. Structurally these resemble the anterior lumbar but in place of hypapophysis only a small ridge is present in its place. Hypapophysis is absent.

(d) Sacrum (Sacral vertebrae):

In the sacral region of rabbit there are 4 vertebrae which fused together to form a compound bone called sacrum but only the first fuses with ilium of the pelvic girdle. However some osteologists supposed that out of these four vertebrae constituting sacrum, only first vertebra is the sacral vertebra and the remaining three vertebrae are the anterior caudals.

Each vertebra of the sacrum have a long neural spine, tubercle-like projections on the upper side showing the presence of zygapophyses, and intervertebral foramina. The first vertebra is the largest and has flat, large stout transverse processes, probably fused sacral ribs. These articulate with the ilia of pelvic girdle the junxtaposition is called sacro-iliac joint. Hypapophyses and anapophyses lacking and the metapophyses are relatively small. The sacro-iliac joint provides strength to the pelvic girdle and the vertebral column

(e) Caudal vertebrae and Sternum: There are 16 caudal vertebrae in rabbit. Only the anterior caudal vertebrae having a well-developed neural spines, neural arches and zygapophyses. These processes reduced gradually until the last vertebrae (terminal vertebrae) near the end of the tail is only left in the form of cylindrical centrum. The transverse processes are absent in caudal vertebrae. The muscles associated to the anterior caudal vertebrae provide movements of the tail in many planes.

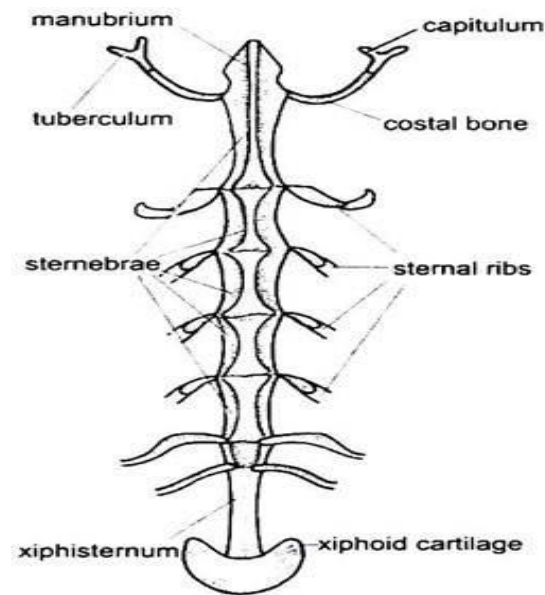


Figure-2.3.7: Sternum of rabbit:

Sternum: The thorax of rabbit is bounded mid-ventrally by the sternum which comprises five elongated bony pieces called sternabrae. Thus, the sternabrae together makes the main body of the sternum known as mesosternum. The first anterior most sternebra is the longest and known as manubrium or presternum. It is produced ventrally into a keel. The first pair of sternal ribs articulate with it in the middle. Sixth sternebra is comparably smallest and the last one is long and slender. Except first rib, all the sternal ribs called xiphisternum terminating into an expanded xiphoid cartilage which attached at the intersternbral junctions (Figure-7).

2.APPENDICULAER SKELETON:

(A) PECTORAL GIRDLE:

It consists of two separate halves or rami. Each half of the pectoral girdle is known as innominate. It is situated dorsal to the anterior thoracic ribs in between the forelimbs, it provide support and strength to forelimbs and from ventral side it protects the soft parts of the body . Thus one half of the pectoral girdle is formed of a broad, more or less triangular bony plate, called scapulo-coracoid and a small clavicle bone.

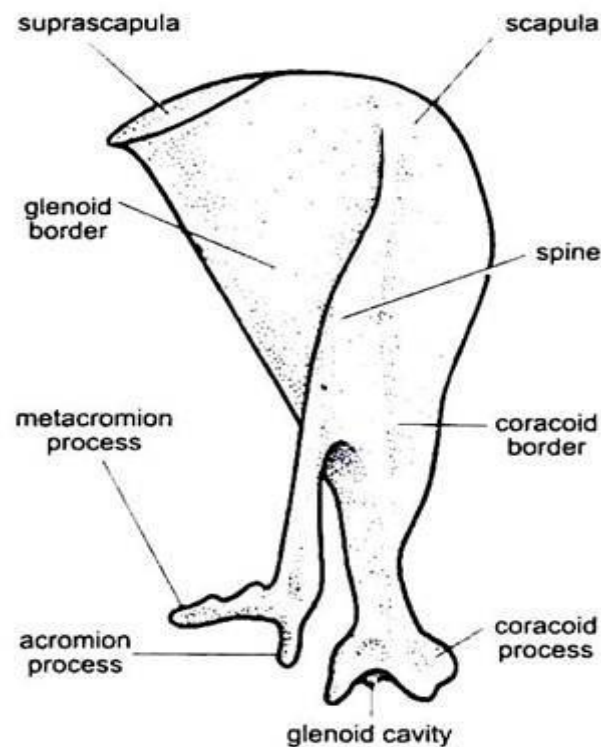


Figure-2.3.8 : Pectoral girdle of rabbit (Right half).

Scapulo-Coraciod: Scapulo-Coracoid bone mainly formed of scapula which is a flat, thin and more or less triangular . Its outer surface possess a prominent ridge known as spine which divides its surface into antero-dorsal and postero-dorsal region to which muscles are attached . The spine terminates ventrally into an expanded knob-like structure called acromion process which posteriorly bears backwardly directed metacromion process.

The apex of scapulo-coracoid is directed downwards and forwards terminates bellow into a concave glenoid cavity for the head of humerus. The rudimentary caracoid process which is a small hook like, present above the glenoid cavity (Figure-8). The suprascapula is in the form of a cartilaginous thin strip located along the dorsal or vertebral border of the scapula. Clavicle extending between the acromion processes and manubrium of the sternum it is a thin, slightly curved bone.

(B) PELVIC GIRDLE:

The pelvic girdle is also contains two equal halves (os-innominate). Both the halves are fused with each other mid-ventrally by pubic symphysis which makes the girdle stout and strong. Girdle is situated in the pelvic region between the two hindlimbs. Each half or os-

innominatum is comprises three bones, the ilium, ischium, and pubis as usual in other vertebrates except pisces. All these bones are fused together to form a single hip bone.

The ilium is antero-dorsal longest bone, it possess a rough, flat articular surface roughly at the middle for the fusion with sacrum. The anterior and dorsal edge of the ilium is approaches to iliac-crest. The ilium extends posteriorly up to the acetabulum. The postero-dorsal part of the os-innominate is made by the ischium. The posteriormost part of ischium is broad and projects outer side into a ischial tuberosity.

The pubis is a narrow bone and forms the ventro- median portion of innominate. Both the pubes meets with each other on the mid-ventral line and form a pubic-symphysis. The pubis directly does not take part in the formation of acetabulum, because a cotyloid bone is present in between the acetabulum and pubis. In between the ischium and pubis a big obturator foramen is present which is always covered by the obturator membrane and muscles for lifetime. Acetabulum is made by the ilium and ischiam on both sides of the girdle and into it, the head of humerus articulates.

C. FORELIMB BONES (Figure-10):

(i)Humerus:

The humerus is the bone of the upper-arm ,which is a long bone having a proximal large rounded head for the for the fusion with glenoid cavity of scapula. Just near the head at the proximal end of huemrus i a bicipital groove in between the two tuberosities (greater and lesser) for the attachment of muscles is provided.

The below the head the anterior surface of the humerus has a projection called deltoid ridge for the attachment of muscles. The distal end of the humerus has a pulley-like trochlea for the fusion with ulna.

Just above trochlea two fossae are present(depressions)-anterior smaller is called coracoid fossa and posterior larger is known as olecranon fossa. Both the fossae linked with each other through a supra-trochlear foramen.

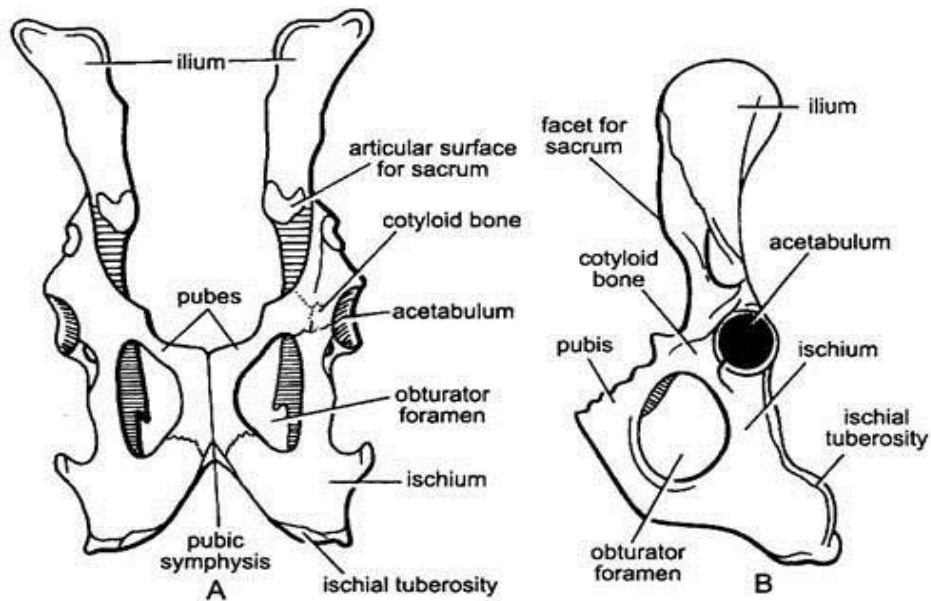


Figure-2.3.9 :Rabbit.A-Complete girdle in ventral view, B-Left half.

(ii)Radius and Ulna:

The bones of the forearm are radius and ulna which are closely fused with each other at the two ends, so that they cannot move over each other.

The ulna is the long bone and its proximal end bears a prominent projection known as the olecranon process. It is situated towards outer side of ulna. It fuses with the olecranon fossa of humerus.

Olecranon process is basally notched called the sigmoid notch into which the trochlea of humerus remains fit .

The radius is the smaller bone than ulna and located towards the inner side of radius bone. The radius and ulna are distally provided with epiphysis and articulate with the wrist bones.

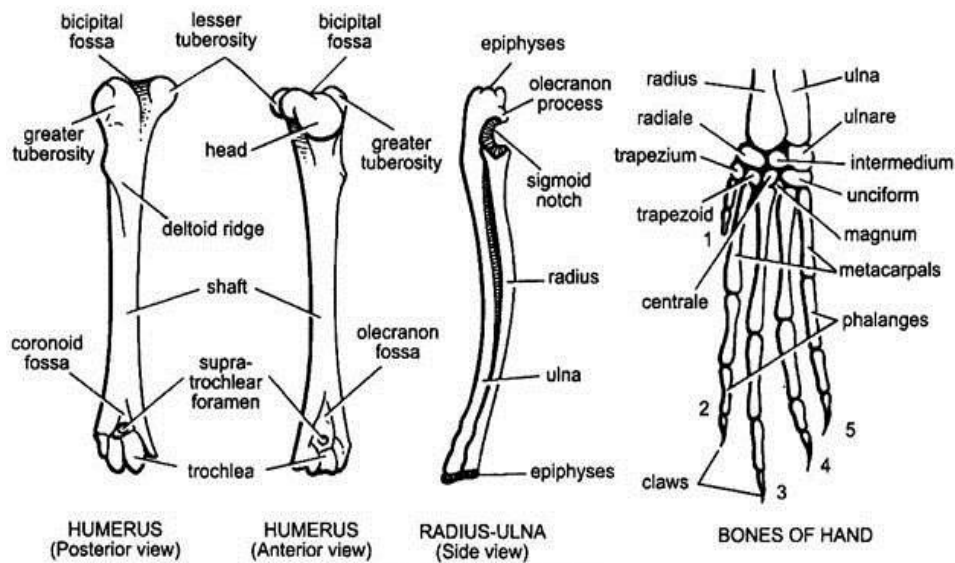


Figure-2.3.10 : Rabbit. Bone of forelimb

(D) HINDLIMB BONES (Figure-11):

(i) Femur:

Femur is also called thigh bone, which is a long bone having a flattened proximal end. Its flattened proximal end possesses a rounded smooth head towards the inner side for the articulation with the acetabulum. The three trochanters are also borne by the proximal end of the femur for the attachment of muscles. The first or greater trochanter is located above the head, the second smaller trochanter is lodged below the head, while the third trochanter is located below the larger trochanter. The deep groove called digital fossa lies below the head and greater trochanter.

The main body of the femur or shaft terminates distally into a pair of expanded condyles surrounding the intercondylar groove for the fusion with tibio-fibula. On the anterior side of intercondylar groove a patellar groove is also present into which the patella bone moves. These condyles are provided with articular facets for the fusion with the tibia.

(ii) Tibio-Fibula:

The shank of the hindlimb is having a long stout and straight tibia and a small slender fibula bones. The fibula is a reduced slender bone fused with tibia distally and its proximal end remains free. The proximal end of these bones is having a proximal epiphysis which fuses with the condyles of the femur. Tibio-fibula fused distally with the bones of the ankle or

tarsus. On the proximal dorsal end of tibia a cnemial crest is present whose two depressions fuses with two condyles of femur.

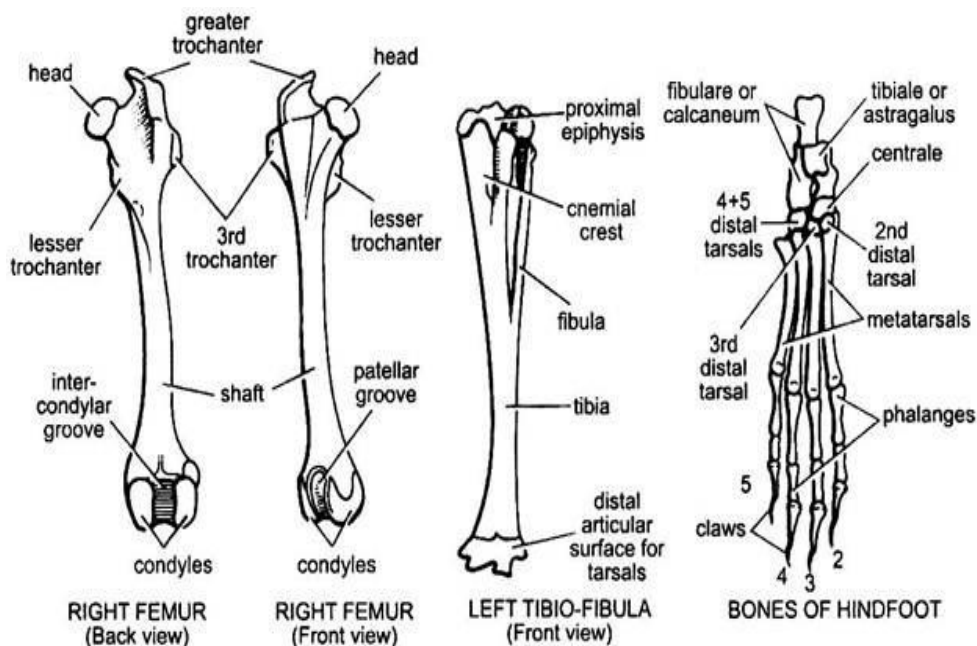


Figure-2.3.11: Rabbit. Bones of hindlimb

(ii) **Bones of Foot:** The ankle of rabbit is made up of six tarsals which are arranged in three rows. The first proximal row consists of two tarsals, a tibiale and intermedium, both are fused and forms the astragalus located on the preaxial side.

(iii) The other largest is the calcaneum which is produced into a process behind its union with the tibio-fibula. The astragalus bears a pulley-like surface for the fusion with tibia. The middle row has a single bone called centrale, just in front of astragalus. The distal row consists of three tarsals which are mesocuneiform, ectocuneiform and cuboid respectively.

The bones of sole or foot are in the form of 4 long metatarsals (the first is absent). Unlike forelimb only four digits or toes are present, each comprises three phalanges. The last phalanx of each digit bears a claw. Hallux (first toe) is

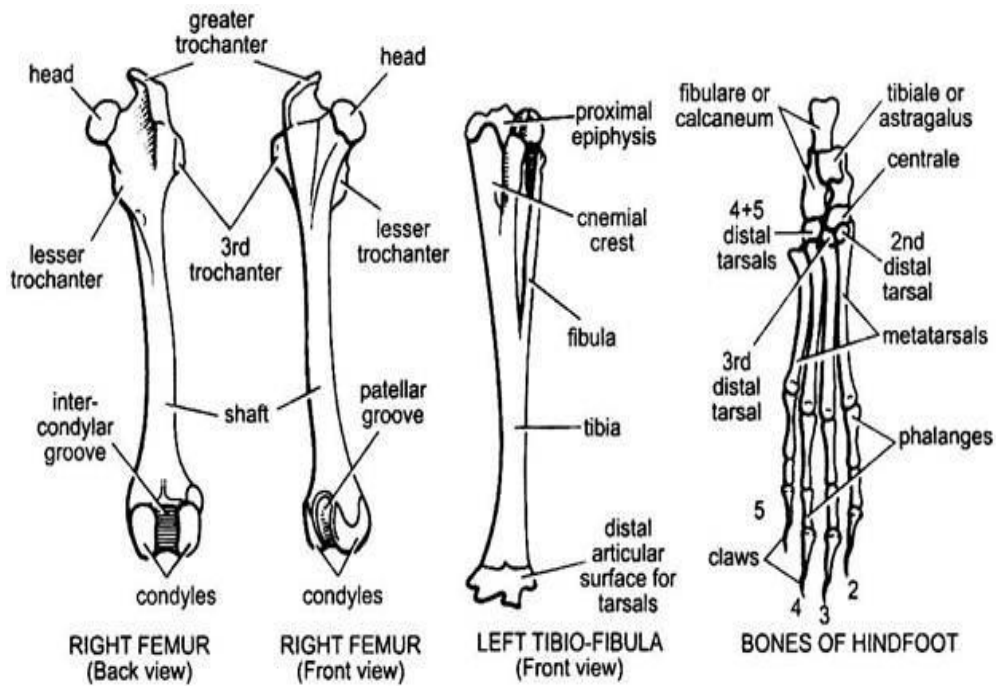


Figure-2.3.11: Rabbit. Bones of hindlimb.

References:

1. <https://www.notesonzoology.com/rabbit/endoskeleton/endoskeleton-of-rabbit-with-diagram-vertebrates-chordata-zoology/7690>.
2. <https://www.notesonzoology.com/rabbit/endoskeleton/endoskeleton-of-rabbit-with-diagram-vertebrates-chordata-zoology/7690>.
3. egyankosh.ac.in/bitstream/123456789/57541/1/Exercise%20%20Rabbit%20Skeleton.pdf.
4. <https://www.notesonzoology.com/rabbit/endoskeleton/endoskeleton-of-rabbit-with-diagram-vertebrates-chordata-zoology/7690>.

2.4 SKELETON STUDY OF SNAKE:

The endoskeleton consists primarily of the skull, vertebrae, and ribs, with only vestigial remnants of the limbs.

1. SKULL: The skull of a snake is a very complex structure, with numerous joints to allow the snake to swallow prey far larger than its head (Figure-1).

The typical snake skull has a solidly ossified braincase, with the separate frontal bones and the united parietal bones extending downward to the basisphenoid bone, which is large and extends forward into a rostrum extending to the ethmoidal region. The nose is less ossified, and the paired nasal bones are often attached only at their base. The occipital condyle is either trilobate and formed by the basioccipital and the exoccipitals, or a simple knob formed by the basioccipital. The supraoccipital bone is excluded from the foramen magnum. The basioccipital may bear a curved ventral process or hypapophysis in the vipers.

(i) Prefrontal bone: The prefrontal bone is situated, on each side, between the frontal bone and the maxilla, and may or may not be in contact with the nasal bone.

(ii) Postfrontal bone: The postfrontal bone, usually present, borders the orbit behind, rarely also above, and in the pythons a supraorbital bone is intercalated between it and the prefrontal bone.

(iii) The Premaxillary bone: It is single and small, and as a rule connected with the maxillary only by ligament.

The paired vomer is narrow.

(iv) Palatine and Pterygoid bone: These are long and parallel to the axis of the skull, the latter diverging behind and extending to the quadrate or to the articular extremity of the mandible; the pterygoid is connected with the maxillary by the ectopterygoid or transverse bone, which may be very long, and the maxillary often emits a process towards the palatine, the latter bone being usually produced inwards and upwards towards the anterior extremity of the basisphenoid.

(v) Quadrate bone: Is usually large and elongate, and attached to the cranium through the supratemporal (squamosal).

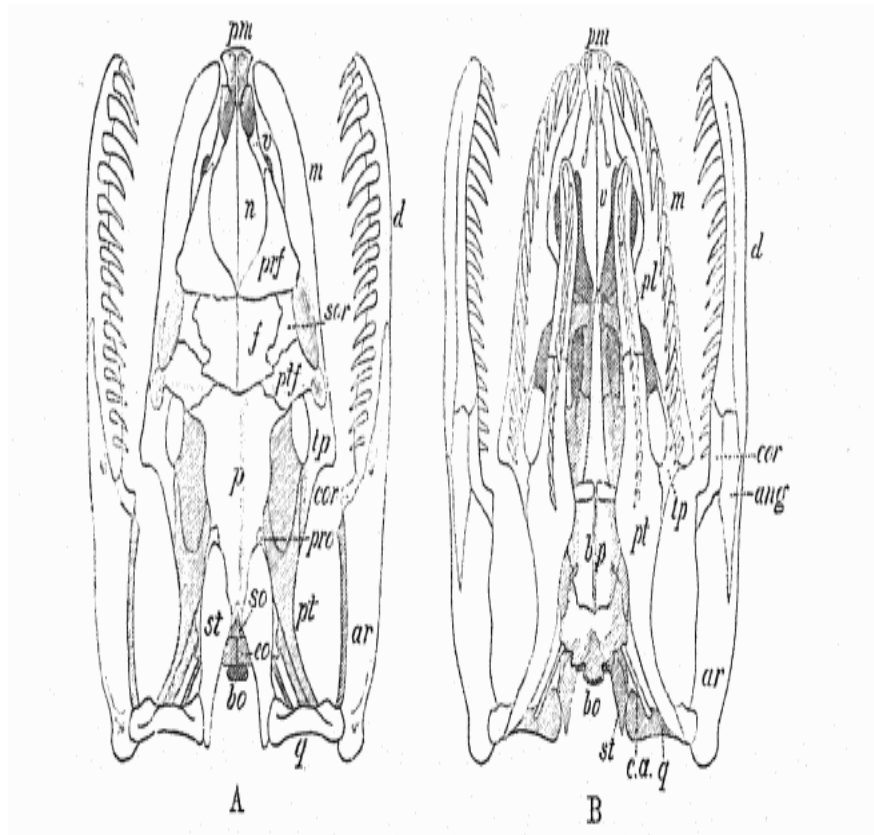


Figure-2.4.1: Skull of *Python reticulatus*. (A) Upper view (B) Lower view

Ang= Angular, ar=Articular, bo=Basiooccipital, bp=basisphenoid, ca=Columella auris, cor= Coronoid, d=Dentary, eo=Exooccipital, f=frontal, m =Maxillary, n=Nasal, p= parietal, pl=palatine, pm=Premaxillary, Prf= Prefrontal, pro=prootic, pl=Pterygoid, ptf= Postfrontal, q=Quadrate, so= Supraoccipital, sor= Supraorbital, st=supratemporal (Squamosal), tp=Transpalatine, v= Vomer

In rare cases, (*Polemon*) the transverse bone is forked, and articulates with two branches of the maxilla.

The quadrate and the maxillary and palatopterygoid arches are more or less movable to allow for the distension required by the passage of prey, often much exceeding the size of the mouth. For the same reason, the rami of the lower jaw, which consist of dentary, splenial, angular, and articular elements, with the addition of a coronoid in the boas and a few other small families, are connected at the symphysis by a very extensible elastic ligament.

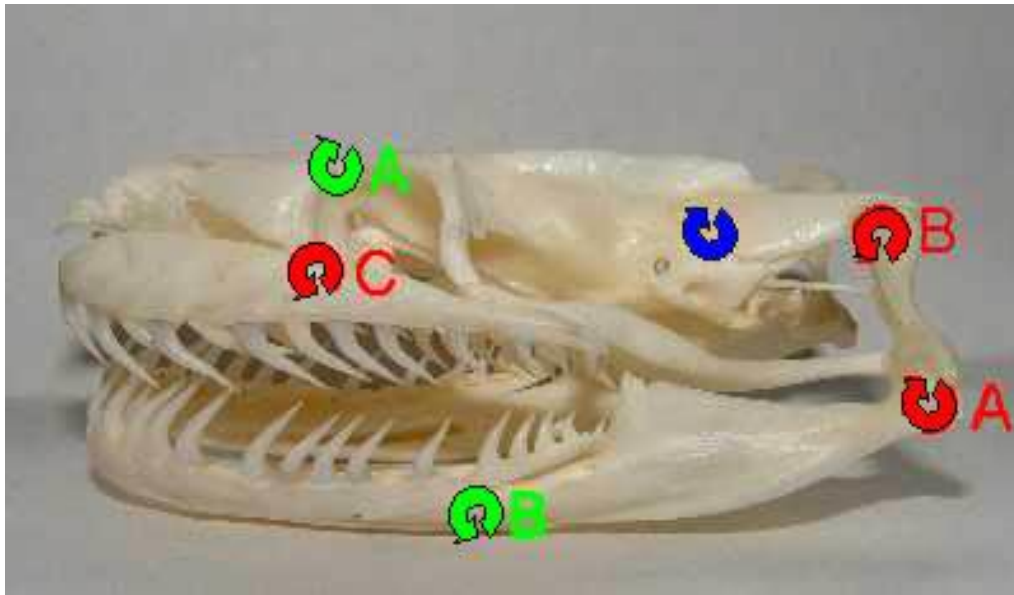


Figure-2.4.2: Lateral view of the skull of a Burmese python, with visible kinetic joints labeled. Red = highly mobile, green = slightly mobile, blue = immobile

(vi) **Hyoid apparatus :** It is reduced to a pair of cartilaginous filaments situated below the trachea, and united in front. There are various modifications according to the genera. A large hole may be present between the frontal bones and the basisphenoid (*Psammophis*, *Coelopeltis*); the maxillary may be much abbreviated and movable vertically, as in the Viperidae; the pterygoids may taper and converge posteriorly, without any connection with the quadrate, as in the Amblycephalidae; the supratemporal may be much reduced, and wedged in between the adjacent bones of the cranium; the quadrate may be short or extremely large; the prefrontals may join in a median suture in front of the frontals; the dentary may be freely movable, and detached from the articular posteriorly.

The deviation from the normal type is much greater still when we consider the degraded wormlike members of the families Typhlopidae and Glauconiidae, in which the skull is very compact and the maxillary much reduced.

In the former this bone is loosely attached to the lower aspect of the cranium; in the latter it borders the mouth, and is suturally joined to the premaxillary and the prefrontal. In both the transverse bone and the supratemporal are absent, but the coronoid element is present in the mandible.

Joints of the snake skull: The various joints in skull of Python are given in figure-2

- **Red A:** the joint between the mandible and quadrate. It is analogous to the joint in mammal jaws.
- **Red B:** the joint between the quadrate and the supratemporal. It is highly mobile in most directions, allowing a wider gape (i.e., the snake can open its mouth wider) and greater jaw flexibility.
- **Red C:** the joint between the prefrontal and maxilla. It allows the maxilla to pivot in the plane of the photograph, and while it does not increase gape, it does facilitate the complex action by which the snake draws prey into its mouth.
- **Green A:** the joint between the frontal bone and nasal bone. It allows the nose to upturn slightly, increasing gape and assisting in swallowing.
- **Green B:** allows the lower jaws to bow outwards, further increasing the gape.
- **Blue:** the joint between the supratemporal and parietal. Immobile, except for *Dasypeltis*.

(vi) Snake dentition:

In most snakes, teeth are located on the dentary of the lower jaw, the maxilla, the palatine bone and the lateral pterygoid plate. The latter form an "inner row" of teeth that can move separately from the rest of the jaws and are used to help "walk" the jaws over prey. Several snake lineages have evolved venom which is typically delivered by specialized teeth called fangs located on the maxilla.

1.1 Skull of poisonous, mildly poisonous and non poisonous snakes:

Most snakes can be placed into one of four groups, based on their teeth, which correlate strongly with venom and lineage.

(a) Aglyphous Snakes: These snakes (*lacking grooves*) have no specialized teeth; each tooth is similar in shape and often size. When teeth vary in size, as in some bird eaters, they do not vary in shape. Most aglyphous snakes are non-venomous; some, like *Thamnophis*, are considered mildly venomous (figure-3).

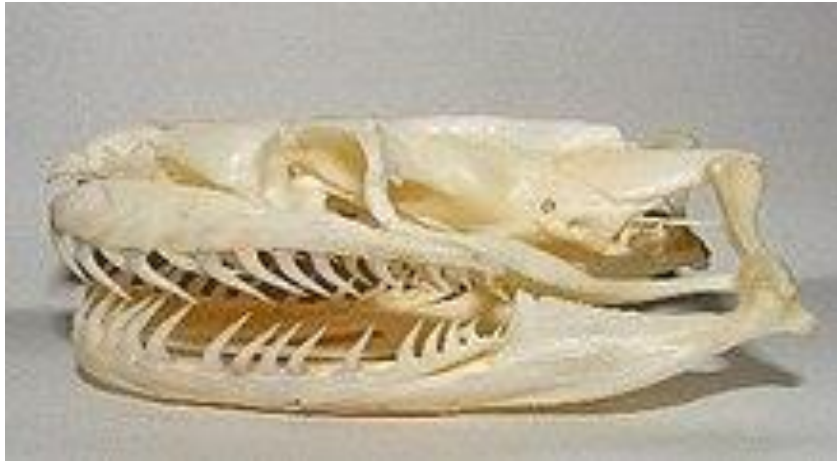

Figure-2.4.3: An aglyphous snake. A Burmese python skull (Python bivittatus)

(b) Opisthoglyphous Snakes: Opisthoglyphous ("rearward grooves") snakes possess venom injected by a pair of enlarged teeth at the back of the maxillae, which normally angle backward and are grooved to channel venom into the puncture. Since these fangs are not located at the front of the mouth, this arrangement is vernacularly called "rear-fanged". In order to envenomate prey, an opisthoglyphous snake must move the prey into the rear of its mouth and then penetrate it with its fangs, presenting difficulties with large prey although they can quickly move smaller prey into position. The opisthoglyphous dentition appears at least two times in the history of snakes.^[1] The venom of some opisthoglyphous snakes is strong enough to harm humans; notably, herpetologists Karl Schmidt and Robert Mertens were killed by a boomslang and a twig snake, respectively, after each underestimated the effects of the bite and failed to seek medical help. Opisthoglyphous snakes are found in the family Colubridae (Figure-4).



Figure-2.4.4: An opisthoglyphous snake. A hognose snake skull (Heterodon nasicus)

(c)Proteroglyphous Snakes:Proteroglyphous snakes (forward grooved) have shortened maxillae bearing few teeth except for a substantially enlarged fang pointing downwards and completely folded around the venom channel, forming a hollow needle. Because the fangs are only a fraction of an inch long in even the largest species these snakes must hang on, at least momentarily, as they inject their venom.^[2] Some spitting cobras have modified fang tips allowing them to spray venom at an attacker's eyes. This form of dentition is unique to elapids (Figure-5).



Figure-2.4.5:A proteroglyphous snake. A king cobra skull (Ophiophagus hannah)



Figure2.4.-6: A solenoglyphous snake. A rattlesnake skull (Crotalus sp.)

Exceptions:

A few snakes do not conform to these categories. *Atractaspis* is solenoglyphous but the fangs swing out sideways, allowing it to strike without opening its mouth, perhaps allowing it to hunt in small tunnels. Scolecophidia (blind burrowing snakes) typically have few teeth, often only in the upper jaw or lower jaw.

2. VERTYEBRAE AND RIBS:

There are 100–450 vertebrae in the body and 10–205 vertebrae in the tail.^[5] The vertebral column consists of an atlas (composed of two vertebrae) without ribs; numerous precaudal vertebrae, all of which, except the first or first three, bear long, movable, curved ribs with a small posterior tubercle at the base, the last of these ribs sometimes forked; two to ten so-called lumbar vertebrae without ribs, but with bifurcate transverse processes (lymphapophyses) enclosing the lymphatic vessels; and a number of ribless caudal vertebrae with simple transverse processes. When bifid, the ribs or transverse processes have the branches regularly superposed.

The centra have the usual ball and socket joint, with the nearly hemispherical or transversely elliptic condyle at the back (procoelous vertebrae), while the neural arch is provided with additional articular surfaces in the form of pre- and post-zygapophyses, broad, flattened, and overlapping, and of a pair of anterior wedge-shaped processes called zygosphenes, fitting into a pair of corresponding concavities, zygantrum, just below the base of the neural spine. Thus the vertebrae of snakes articulate with each other by eight joints in addition to the cup-and-ball on the centrum, and interlock by parts reciprocally receiving and entering one another, like the mortise and tenon joints.

The precaudal vertebrae have a more or less high neural spine which, as a rare exception (*Xenopholis*), may be expanded and plate-like above, and short or moderately long transverse processes to which the ribs are attached by a single facet. The centra of the anterior vertebrae emit more or less developed descending processes, or haemapophyses, which are sometimes continued throughout, as in *Tropidonotus*, *Vipera*, and *Ancistrodon*, among European genera.

In the caudal region, elongate transverse processes take the place of ribs, and the haemapophyses are paired, one on each side of the haemal canal. In the rattlesnakes the seven or eight last vertebrae are enlarged and fused into one (figure-7).



Figure 2.4.-7: Vertebrae in snake:

3. VESTIGIAL LIMBS:

No living snake shows any remains of the pectoral arch, but remains of the pelvis are found in (Figure-8)

- Boas and Pythons: a long ilium, attached to the lower branch of the first bifurcate transverse process of the lumbar vertebrae, bearing three short bones, the longest of which, regarded as the femur, terminates in a claw-like pelvic spur which usually appears externally on each side of the cloaca.
- Leptotyphlopidae: ilium, pubis, and ischium, and rudimentary femur, the ischium forming a ventral symphysis.
- Aniliidae
- Typhlopidae: a single bone on each side.



Figure 2.4.-8: Vestigial limb of snake(Boelens python)and their bones inside anal spure

(4)Difference between poisonous and non-poisonous snake:

Poisonous Snakes:

- Body colour generally bright.
- Neck constricted.
- Head long, triangular, and wide due to the presence of poison glands on two sides of the head.
- In majority, a hood is present.
- Tail abruptly tapering except in sea snakes.
- Head shield very large.
- The scales on the dorsal surface of the trunk are smaller but spinal scales are large and hexagonal.
- The ventral surface is covered with large transverse plates. No small scales are usually visible from below. All poisonous snakes must have broad plates on the belly but snakes having broad plates are not always poisonous.
- Teeth are not uniform (Figure-9). The maxillary teeth are large and called 'fangs.' Fangs are grooved or with a canal.

Non-poisonous Snakes:

- Body colour not so bright.
- Neck un-constricted.
- Head usually narrow and elongated.
- Hood usually absent.
- Tail gradually tapering.
- Head shield small.
- The scales are large and usually nine in number.

- The dorsal scales are large but spinals are smaller and not hexagonal.
- Ventral surface is covered either with small scales or small scales are visible on both sides of the transverse plate below.
- 10. The teeth are uniform and solid (Figure-9)
- 11. Poison glands absent.

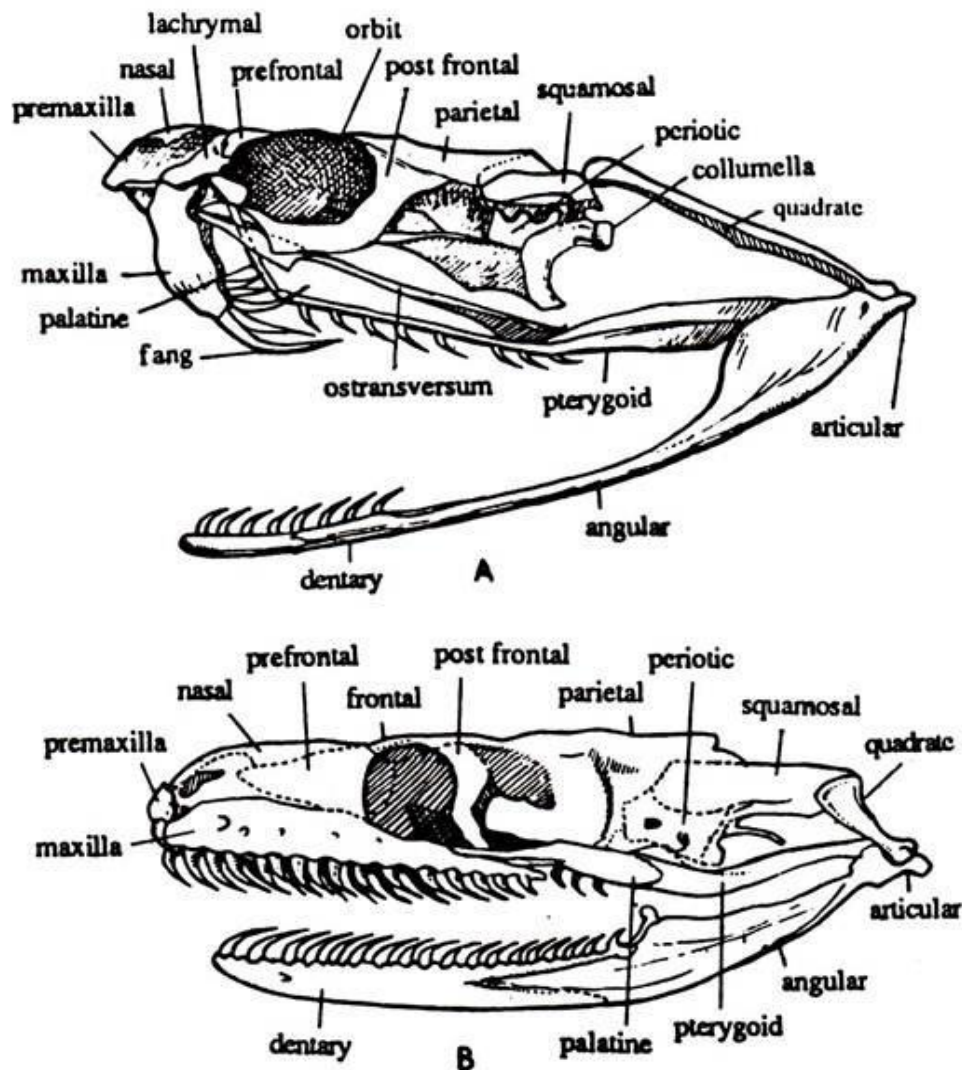


Figure – 2.4.9: Snakes; Skull and Mandible. (A) Poisonous and non-poisonous snake

• References:

- George Albert Boulenger. *The Snakes Of Europe*, 2nd edition. London: Methuen & Co., Ltd., 1913.

1. Bruna Azara, C. (1995). "*Animales venenosos. Vertebrados terrestres venenosos peligrosos para el ser humano en España*". *Bol. SEA* 11: 32-40.
2. LD50 for various snakes.
3. Rose, Walter; The reptiles and amphibians of southern Africa; Pub: Maskew Miller, 1950
4. Engelmann, Wolf-Eberhard. Snakes (No. 05352). Publisher Bookthrift 1982. ISBN 978-0896731103
5. <https://www.britannica.com/animal/snake/Form-and-function>.

2.5 STUDY OF SKULL OF GALLOS (FOWL)

The endoskeleton of Gallus or Fowl is quite light and completely bony and contains no marrow. They are pneumatic and filled with air. The endoskeleton consists of usual two divisions, viz., the axial skeleton and the appendicular skeleton.

The axial skeleton makes the thin axis of the body and consists of the skull, vertebral column, sternum and ribs. The appendicular skeleton includes the bones of the limbs (forelimbs and hindlimbs) and girdles (pectoral and pelvic girdle) by which they are connected to the axial skeleton. Here we will do study about skull bones (palates) of *Gallos domesticus*

The skeleton of backbone and limb girdles allows transferring the weight of the body on the wings or on the legs. For this purpose there are two plate-like girders called the sternumsynsacrum, curved in opposite directions (Figure-1).

A. AXIAL SKELETON:

1. Skull ^[1]: The skull of fowl consists of: (a) cranium (b)sense capsules (c)visceral skeleton including the upper and lower jaws and hyoid apparatus (Figure-2). These structures consist of small bones called palates.

Characteristics of Skull:

- The skull is large but very light due to pneumatic bones.
- There has been a complete fusion of bones so that it has no sutures, but it is not deviated from the reptilian type of skull.
- Number of bones in skull are comparatively reduced than other vertebrate.
- Jaw bones are modified into a toothless beak.
- skull have a single occipital condyle (monocondylic).
- Cranium is rounded and large for accommodation of well-developed brain.
- Cranium is tropibasic means it does not extend forward into orbital region (tropibasic).
- A thin membranous interorbital septum separates the large orbits .
- Jaw suspensorium is autostylic i.e upper jaw connected directly to the cranium.

- In the skull of fowl, palate is schizognathous (short vomers and palatines meet together).

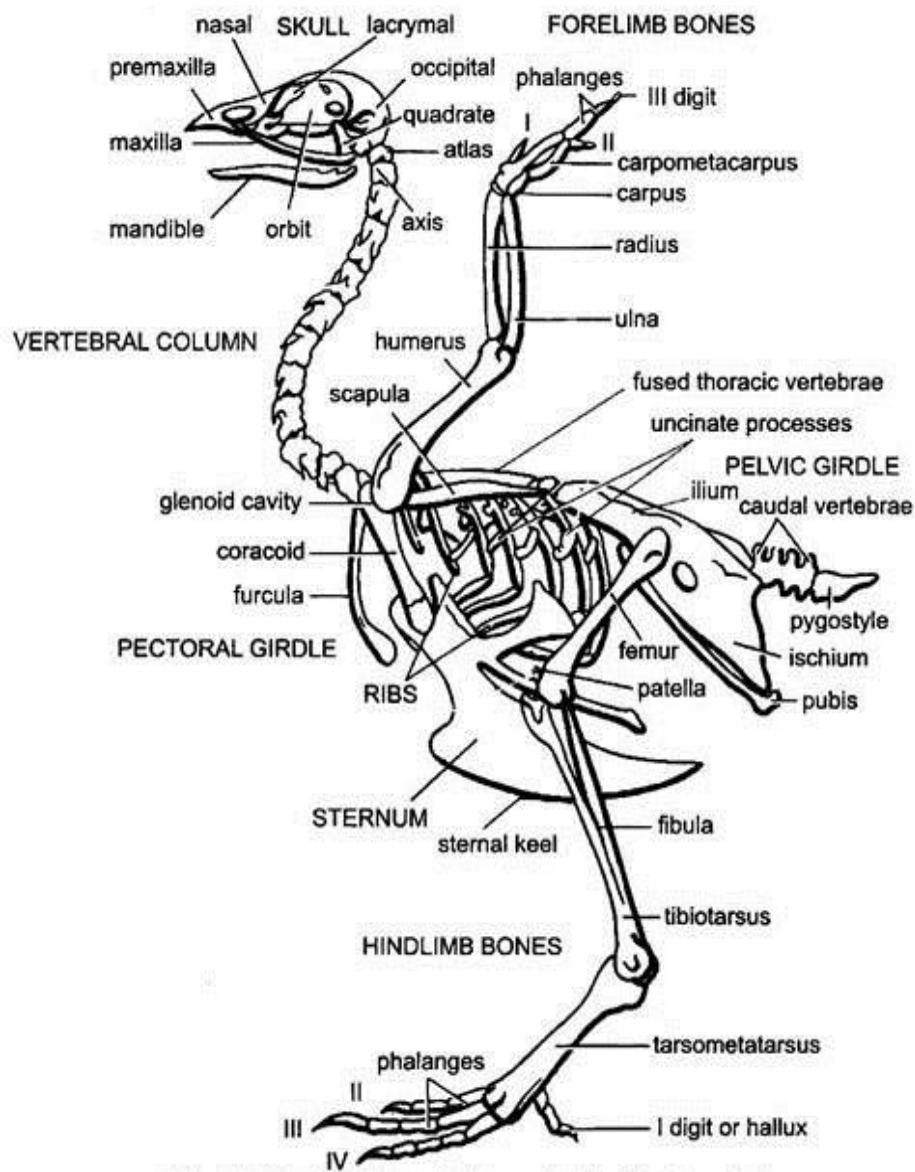


Figure-2.5.1: Complete and fused endoskeleton of Fowl.

(a) Cranium (brain box): It surrounds the brain. Further cranium is divided into the following sub-regions:

(i) Occipital Region: Occipital region is the posterior part of the skull. As usual like other vertebrates It consists of bones, basioccipital (basal), the two occipitals (lateral sides) and the supraoccipital (above), all of which surrounds a large rounded opening called foramen

magnum. Just below the foramen magnum is a single rounded occipital condyle present, mainly formed by the basioccipital. The supraoccipital frontally joins the two parietal bones.

(ii) Parietal Region: It is situated in front of the occipital region. Its roof is formed by two square-shaped fused parietal bones. The lateral sides of parietal region are formed by the squamosals and alisphenoids bones and the floor by a large basisphenoid bone.

The basisphenoid bone Ventrally is covered over by a paired broad membrane bone called the basitemporal or parasphenoid. The basisphenoid progresses forward, by a slender parasphenoid rostrum which represents the anterior area of parasphenoid. Each squamosal takes growth outward and forward into a zygomatic process. The squamosal is tied up the tympanic cavity and tightly connected to other bones of cranium..

(iii) Frontal Region:

It is situated anterior to parietal region. A pair of large frontal bones makes the roof of the frontal region. The posterior lateral end of each frontal region is dragged out into a strong zygomatic or post-orbital process which attached with the zygomatic process of the squamosal bone. The alisphenoid bones are continued forward into the orbitosphenoids makes the sides of the frontal region, while the base of frontal region is formed by a poorly developed presphenoid bone situated above the parasphenoid rostrum.

(b) Sense Capsules:

These are closely fused with the cranium and holds the various sense organs viz; sense capsules include auditory, optic and olfactory capsules:

(i) Auditory Capsules: A pair of auditory capsules, surrounding the organs of hearing, is connected behind one on either lateral side of the occipital region of the skull. A prootic bone forms the major part of each auditory capsule (The small opisthotic bone of early embryo fuses with the exoccipital bone and the epiotic with the supraoccipital bone).

(ii) The tympanic cavity present as a large cup in the middle ear on each posterior lateral side of the skull surrounded by the squamosal above and the basitemporal bone below. The tympanic cavity consists of a tympanic membrane connected just within its prominent outer edge, and its inner edge a slender rod-like called columella which is made of bone and cartilage, and its outer part a tri-radiate cartilage is called extra-columella.

(iii) The three rays of extra columella are called the supra- stapedial, extra-stapedial and infra-stapedial. There are several openings within the tympanic cavity two of these lie about the middle of the cavity. The upper one is fenestra ovalis and fenestra rotunda is lower one.

The inner end of columella auris adjusted into the fenestra ovalis, while its outer end touches the tympanic membrane. The tympanic cavity communicates with the mouth through an eustachian canal, the posterior funnel-shaped opening of eustachian canal lies in the anterior ventral part of the tympanic cavity. The eustachian canal goes forwards and inwards between the basitemporal and the basisphenoid bone and meets with its fellow of the opposite side to open by a common median aperture in the roof of the posterior part of the mouth cavity.

(ii) Optic Capsules:

The two orbits are very large to accommodate the relatively massive eyes. They are separated from one another by a narrow vertical partition, the inter-orbital septum, which is formed by a mesoethmoid together with presphenoid, parasphenoid rostrum and orbitosphenoids. Each orbit is bounded anteriorly by the frontal and large lacrymal, dorsally by the frontal and posteriorly by the post-orbital process of frontal and alisphenoid bone.

The lacrymal bone is produced below in a curved pointed process hanging freely. The orbit is incomplete ventrally . The interorbital septum is broken by many openings. In the posterior part of orbita large median optic foramen lies. It actually perforates the orbito-sphenoid and communicates the two orbits with each other.

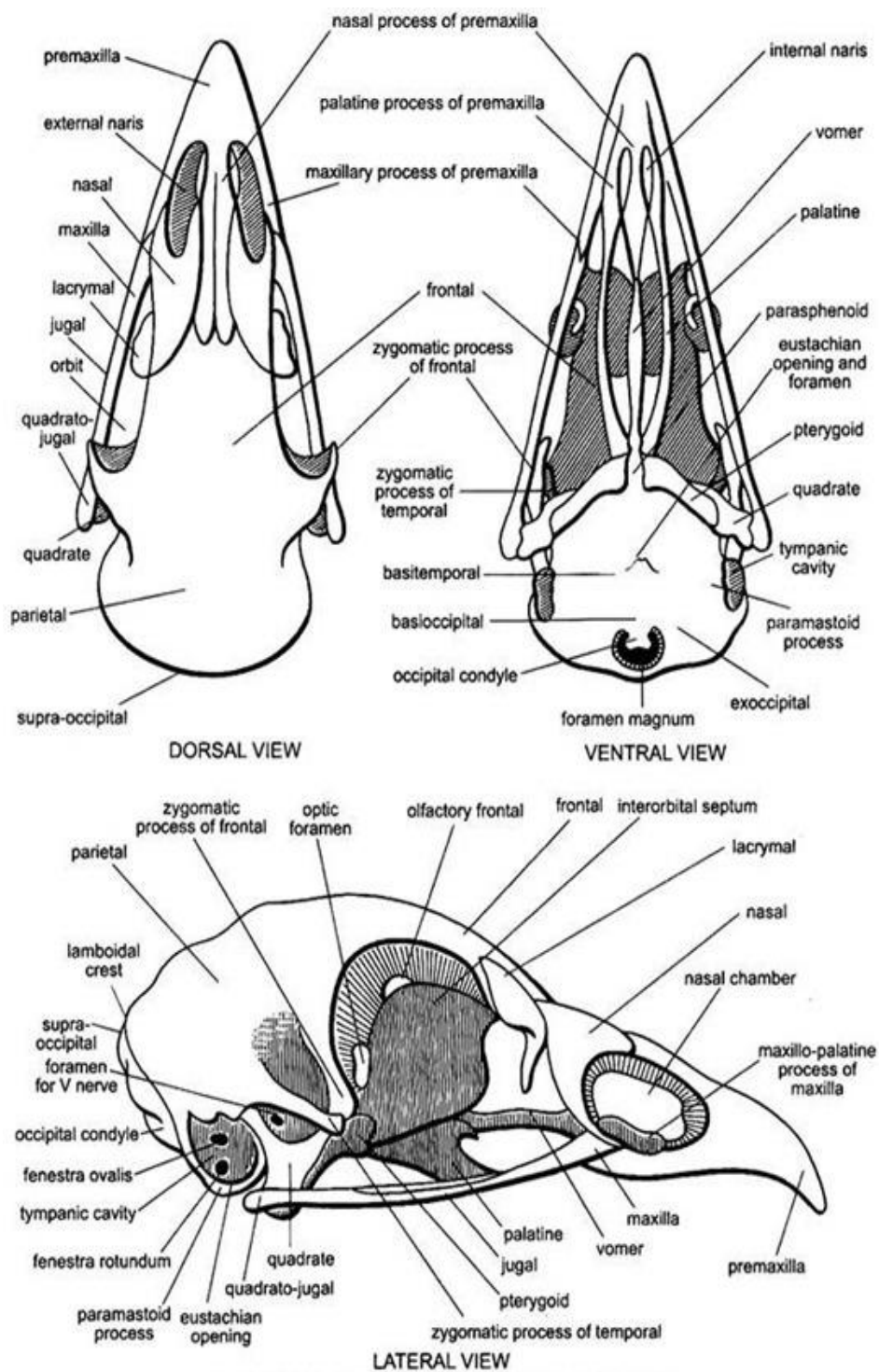


Figure-2.5.2: Skull of fowl: Dorsal, Ventral and Lateral view

(iii) Olfactory Capsules:

The olfactory capsules are greatly reduced with poor sense of smell and present in front of cranium. made up of cartilage. turbinates are also comparatively poorly developed. The nasals are in the form of a pair of thin, triangular plate-like bones making the roof and sides of the nasal chambers.

Each nasal drawn out three processes, a posterior process joining with the frontal and also with lachrymal bone. Other two anterior processes making the posterior margin of the external nares and fusing with the process of premaxilla. The two vomers teeth fuse into a small, median, slender bone, situated in continuation with the parasphenoid rostrum at the base of nasal chambers, and separating the two nasal chambers equally at the base..

(b)Visceral Skeleton:

Like other tetrapods the visceral skeleton of fowl consists of upper jaw, lower jaw and hyoid apparatus. Jaws are not toothed and form boundaries of the mouth gape. The tongue is supported by Hyoid apparatus.

(i) Upper Jaw:

In each side of upper jaw forms two bony arcades- the outer arcade or sub orbital bar or infra-orbital arcade comprises of premaxilla, maxilla, jugal and quadrato- jugal and the inner arcade or palato-pterygo-quadrato bar is formed by pterygoid , palatine and quadrate bone.

Premaxillae:

Premaxillae are fused in front into a large triradiate bone which practically makes the whole of the upper beak.

Posteriorly it is produced into three paired processes:

- The nasal processes which are longest, run backwards closely along the inner side of nasals to unite the mesethmoid and frontals constituting the upper margin of the external nares.
- The maxillary processes run backwards and slightly outwards constituting anterior part of the upper jaw.

- The inner palatine processes are the smallest, run horizontally backwards below maxillae and ultimately join with palatines (Figur-3). They form the anterior part of roof of palate (buccal cavity).

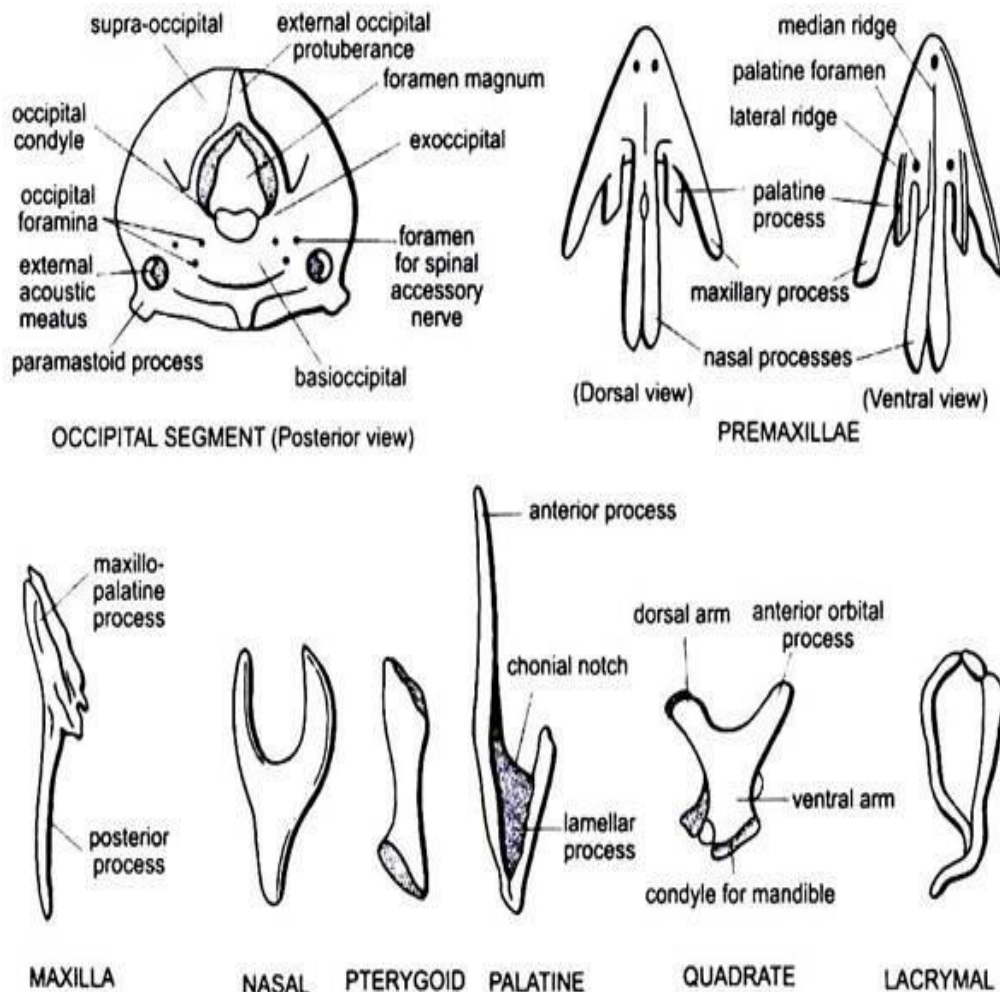


Figure-2.5.3: Fowl. Loose or disarticulated bones of skull.

Maxilla:

Maxilla is a slender rod-shaped bone. Its anterior end united with maxillary process of maxilla and incomming into spongy maxillo-palatine process. The slender posterior end of maxilla is ontinued backwards by a slender jugal and quadrato-jugalto the quadrate. The posterior zygomatic process of the maxilla makes the anterior part of the zygomatic arch outer arcade or infraorbital arcade or suborbital bar (Figure-3).

Jugal:

The jugal bone is a very slender rod which forms the middle part of the sub-orbital bar situauetd dorsally upon the other two components of the bar namely maxilla and quadrato-jugal.

Quadrato-Jugal:

The quadrato-jugal is also a rod-like slender bone and makes the posterior part of the sub-orbital bar. Its hind most end is thickened and fusing with quadrate bone.

Quadrate:

The quadrate is a triradiate bone articulating by two facets on its otic process with the roof of the tympanic cavity. Its dorsal arm articulates with the squamosal bone just above the anterior margin of the tympanic cavity. Its ventral arm makes a condyle for articulation with the mandible. On the outer side, condyle also fuses with the quadrato-jugal bone and on the inner side with the pterygoid bone. Its orbital process (anterior arm) runs forward parallel to the pterygoid and ends blindly (Figure-3).

Pterygoid:

It is a short and stout, rod-shaped bone. It is located obliquely behind the palatine bone between the presphenoid rostrum and quadrate bone of its own side. It articulates behind with the quadrate bone and in front with the parasphenoid rostrum and palatine bone (figure-4).

Palatine:

It is slender bony bar situated in front of parasphenoid rostrum. Anteriorly it is connected with the processes of premaxilla and maxilla. Its posterior end articulates with pterygoid. Posteriorly it is also drained inwards into a broad lamella, the sides of which connected with the rostrum (figure-4).

(ii) Lower Jaw:

The V-shaped lower jaw consists of two halves or rami which are long laterally compressed and are tightly united in front. Each ramus consists of five bones, i.e., one replacing bone called the articular, and four investing bones namely the angular, supra-angular, dentary and splenial, developing around a cartilaginous bar, Meckel's cartilage. All these bones are fused with each other.

Articular bone constitutes the posterior expanded part of each ramus. On the dorsal surface it carries an elongated mandibular condyle for the fusion with the quadrate bone. Posteriorly it is produced into a medial and angular process. Angular is a slender bone and located beneath the articular along the lower inner posterior third border of each ramus.

Supra-angular forms the dorsal part of about one-third of the posterior upper part of ramus. It bears a coronoid process. Dentary is the largest bone and makes approximately the complete anterior or front half of the ramus. Anteriorly it is fused with its counterpart of the other side making the mandibular symphysis. It is devoid of teeth. Splenial is a thin splint-like bone situated on the inner surface of the middle part of ramus.

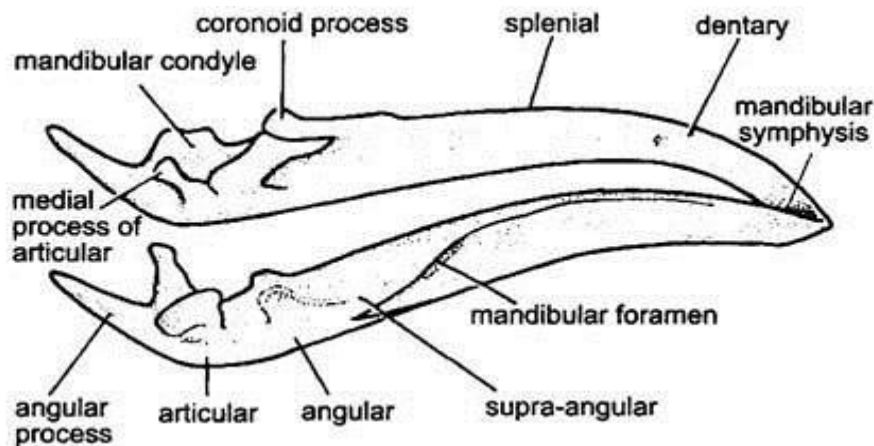


Figure-2.5.4: Frog. Mandible

(iii) Hyoid Apparatus:

Hyoid apparatus is situated the floor of the mouth and it supports the tongue (Figure-5). It consists of three bones- an anterior entoglossal or glossohyal or ceratohyal , a median bony basihyal and a posterior urohyal . Entoglossal carries a cartilaginous process in its front. Entoglossal gives off a pair of backwardly directed short anterior cornua which serve as free ends of ceratohyals.

A pair of long backwardly directed posterior cornua or thyrohyals originates from the junction of basihyal and urohyal. Each thyrohyal consists of two rod-like pieces called the proximal ceratobranchial and distal epibranchial respectively.

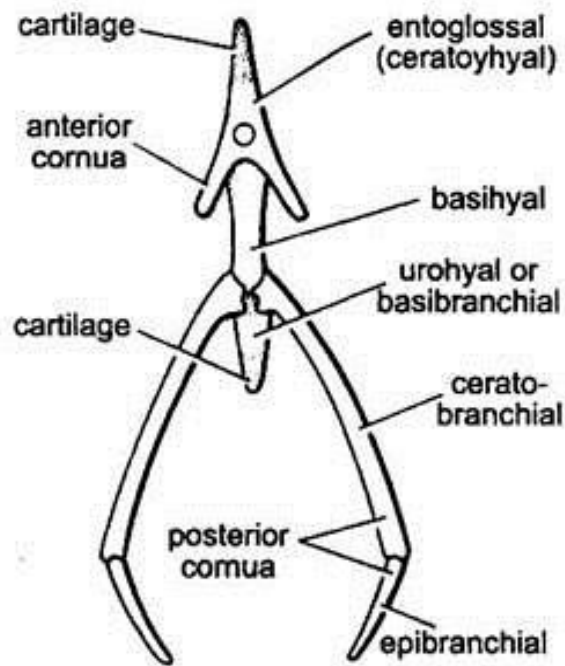


Figure-2.5.5: Hyoid Apparatus of fowl:

2. TYPES PALATES IN BIRDS (SMALL BONES OF SKULL) . The skull bones of (palates) birds are divided in 4 categories by Huxley (1877). This classification was based on the relations of vomer, palatines, pterygoids and maxillo-palatine processes (Figure-6).

(i) Palaeognathous or Dromaeognathous Palate:

This type of palate is characteristic of Ratitae, such as the ostrich, rhea, kiwi and tinamous, etc.

- In this type of palate the vomer is large behind connected with the palatines.
- Palatines do not fuse with the parasphenoidal rostrum, because the vomer intervenes between the two.
- Maxillo-palatine processes are small and do not meet with one another or with the vomer.
- Basipterygoid processes of basisphenoid are well developed and they fuse with the hinder part of the pterygoids.
- Pterygoids are immovably fixed to vomer and like in reptilians. This type of palate is primitive and occurs in the Palaeognathae.

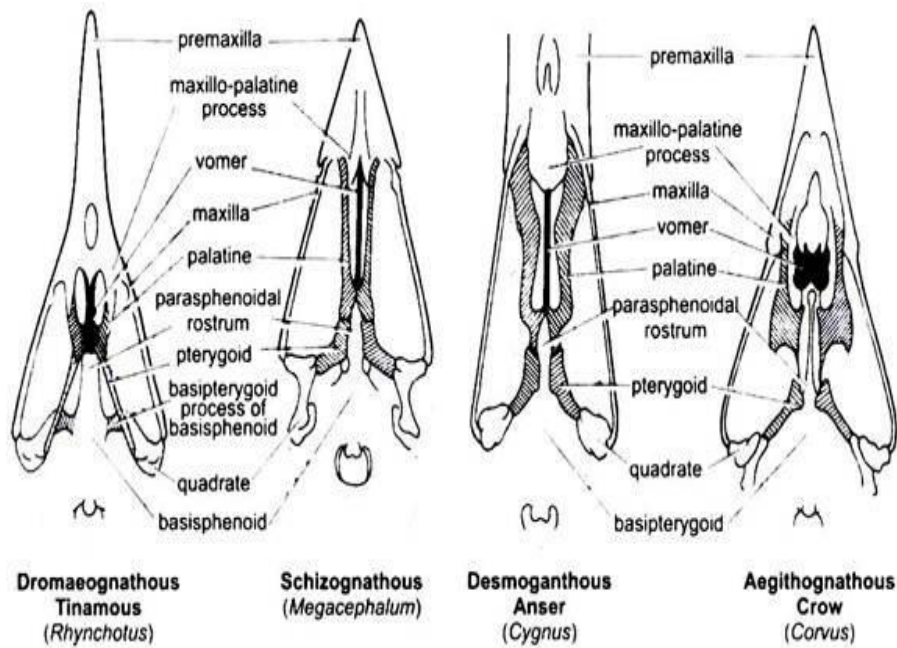


Figure 2.5.6: Skull palates in birds.

(ii) Schizognathous Palate:

This type of palate is common in a variety of birds, such as pigeons, gulls, fowls, plovers, woodpeckers, cranes, woodpeckers, trogons, etc.

- Vomer is small and pointed in front, or absent.
- Palatines and pterygoids fused with the parasphenoidal rostrum at the point where they join one another.
- Maxillo-palatine processes do not fuse with each other or with the vomer.
- Basipterygoid processes may be completely absent or small and originating from the base of the rostrum.
- Pterygoids are movably articulated.

(iii) Desmognathous Palate:

This type of palate is common in most of the wading and swimming birds such as herons, storks, ducks and geese, birds of prey, parrots, cuckoos, etc.

- Vomer is often useless or very small or may be disappears in the skeleton. When present, it is always narrow, slender and tapers to a point in front.
- Palatines and pterygoids bones fused with the rostrum.

- Maxillo-palatines are large and connected with one another across the middle line, often forming a flat, spongy palate to the vomer ventrally .
- Basipterygoid processes are absent.
- In parrots, a specific desmognathous type of sliding palate found so that the lower jaw depression automatically raises the upper jaw.

(iv) Aegithognathous Palate:

This type of palate resemble with schizognathous type of palate. It is found in passerine birds such as bulbuls, crows, swifts , etc. The vomer is short and broad and shortened instead of being pointed in front. The vomer is deeply cleft embracing the rostrum posteriorly.

Importance of Palate in Classification:

There are, however, marked differences in the structure of the palatal region of skull in birds which provides an important character for their classification. The living birds are classified in two suborders- Palaeognathae and Neognathae. The Palaeognathae or Ratitae are (all the flightless birds). They have a dromaeognathous palate in skull having the large vomer is posteriorly extended p, so that the two palatines do not fuses with each other and with the rostrum.

On the other hand, in Neognathe or Carinatae in which all modern flying birds are kept, they have a neognathous palate with three subtypes (schizognathous, desmognathous and aegithognathous), in all of them vomer is small or absent, so that the palatines meet the rostrum.

Reference:

1. <https://www.notesonzoology.com/birds/fowl/endoskeleton-of-fowl-or-gallus-with-diagram-chordata-zoology/8077>.
2. <https://www.notesonzoology.com/essay/birds-essay/birds-compilation-of-essays-on-birds-vertebrates-chordata-zoology/8019>.

Summary:

The study of skeleton of vertebrates, both living and extinct is important from the point of view of comparative anatomy. It is fortunate that the skeletal structures have been preserved as fossils and this is because they are hard and because of their peculiar chemical composition. Much of the fossil evidence available is therefore of skeleton and mostly of head skeleton. This has helped in tracing not only vertebrate evolution but: also trends in evolution. Because of the skeletal evidence it has been possible to trace the evolution of groups like birds and mammals and particularly of man. A knowledge of skeleton is a must for an understanding of the phylogeny of vertebrate groups and their interrelationships. Skeletal system is the only system that provides an Overview of structural changes that have occurred in vertebrates. The head skeletal is the most informative part because it completely reflects th; divergent changes that have occurred during evolution of vertebrates. There is a common ancestral pattern of bone and their arrangement from which the living vertebrates have evolved.

Chondrocranium is the cartilaginous fore-runner of the skull bone. It shows variations in the form during different stages of development since it changes its functions at different ages of the animal. Similarly the stiff rigid rod like notochord which appeared in the early chordates to provide stability and rigidity to the body got replaced by a segmented vertebral column to provide mobility. The folds of skin which helped provide steering capacity to vertebrate locomotion became replaced by paired appendages. These have become variously modified to suit the different modes of life adapted by the vertebrates.

2.8 Terminal questions:

1.Name the two types of skeleton found in animals.

.....

2. Mention the two types of endoskeletal structures found in vertebrates.

.....

3. Fill in the blanks in the following sentences by selecting an appropriate word from those given in the brackets after each sentence:

a) The skeleton of the head is known as (vertebral column, pelvic girdle, skull)

b) Cranium encloses and protects the (eye, heart, brain)

c) The brain within the cranium is in contact with the spinal cord through an aperture found at the hind end of the cranium (fenestra ovalis, foramen magnum, external nares).

d) The vertebra with concavity in front and convexity behind is called type (amphicoelous, procoelous, opisthocoelous).

e) The bone humerus of the upper arm articulates with the pectoral girdle at cavity (glenoid, acetabulum, zygapophysis).

f) Radio-ulna a composite bone is found in (rat, bat, frog).

4. Names of some bones are given in column A and the part of the skeleton in which these bones occur in column B. Match them.

Column A

a. Parietal

b. Vomer

c. Maxilla

d. Dentary

Column B

A. Pectoral girdle

B. Cranium

C. Olfactory capsule

D. Upper jaw

e. Clavicle

E. Pelvic girdle

f. Pubis

F. Lower jaw

5. State whether the following sentences are true (T) or false (F).

a. Cranium is a part of the vertebral column.

b. Jaws are derived from the visceral skeleton.

c. Axis is the name of the first vertebra.

d. The bone in thigh segment of the hind limb is femur.

e. Glenoid cavity is found in the pelvic girdle.

f. Deltoid ridge is found on the humerus.

6. Mention the names of bones bearing teeth in the skull of
frog.....

7. The different segments of the fore limb and hind limb of vertebrates are given in list A. The names of bone occurring in the limbs are given in the subsequent list B. Select the appropriate bone and write it against the segments of the limbs.

List A

Fore Limb : a. upper arm

b. lower arm

c. Wrist

d. palm/hand Hind limb:

e. Thigh

f. Shank

g. Ankle

h. Foot

List B -

Tarsal, Carpal, Humerus, Femur, Radius, Tibia, Fibula, Ulna, Metatarsals, Metacarpals

Answers:

1 A. (a) iii (b) iv (c) i (d) ii

B. (i) front, behind (ii) Amphicoelous (iii) Heterocoelous, saddle (iv) flat, depressions.

2. (a) F (b) F (c) T (4 T (e) T (9 F (g) F (h) T

3. (a) palaeontological (b) digits (c) synsacrum (d) ancestry (e) hyoid (f) brain

4 Exoskeleton and Endoskeleton

5. Cartilaginous and bony

6 a. skull; b. brain; c. foramen magnum; d. procoelous; e. glenoid; f. frog

7. a & B; b & C; c & D; d & F; e & A; f & E

8 a. false b. true c. false d. true e. false f. true

9. Premaxilla, Maxilla and Vomer

10. Column A Column B a. humerus b. Radius and Ulna c. Carpals d. Metacarpals e. Femur f. Tibia and Fibula g. Tarsals h. Metatarsals.

UNIT 3: STUDY OF PERMANENT SLIDES OF PROTOCHORDATES AND CHORDATES

CONTENTS

3.1 Objectives

3.2 Introduction

3.3 Study of permanent slides

3.3.1 Protochordates

3.3.2 Chordates

3.4 Summary

3.5 Terminal Questions and Answers

3.1 OBJECTIVES

Study of different permanent slides of protochordates and chordate.

3.2 INTRODUCTION

Phylum Chordata has been divided into two groups: Protochordates and Vertebrata. The Protochordates is derived from words, protos- first, chorda- cord. They are great phylogenetic significance. It shows first sign of vertebrate formation. This group includes the lowly-organized members of phylum chordata. Protochordates is classify into three kinds of sub phyla based on the type of notochord they possess.i) Hemichordata ii) Urochordata iii) Cephalochordata.

3.3 STUDY OF PERMANENT SLIDES

3.3.1 PROTOCHORDATES

1) Amphioxus

1. T.S of *Amphioxus* through oral hood

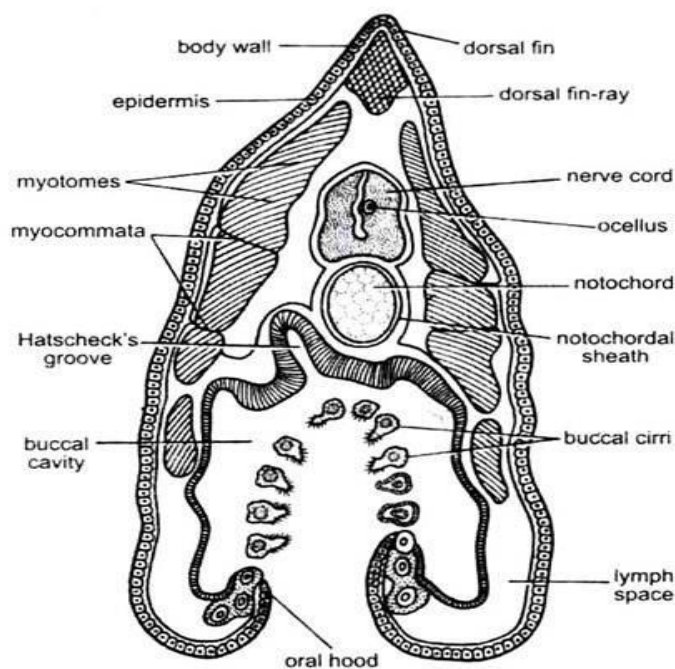


Fig.3.1 T.S. of Amphioxus through oral hood

Comments:

1. Body wall comprises single layer of **epidermis**.

2. On the dorsal surface **dorsal fin** having the **dorsal fin ray** is present.
3. **Myotomes** separated by **myocommata** are present on both the sides in the dorsal half portion of the section.
4. Dorsal tubular **nerve cord** containing **ocellus** lies below the dorsal fin.
5. **Notochord** composed of vacuolated cells, is enclosed in the notochordal sheath and lies below the nerve cord.
6. The oral hood enclosed a large buccal cavity.
7. Several sections of the buccal cirri are seen in the buccal cavity.

2. T. S of *Amphioxus* through anterior-pharynx

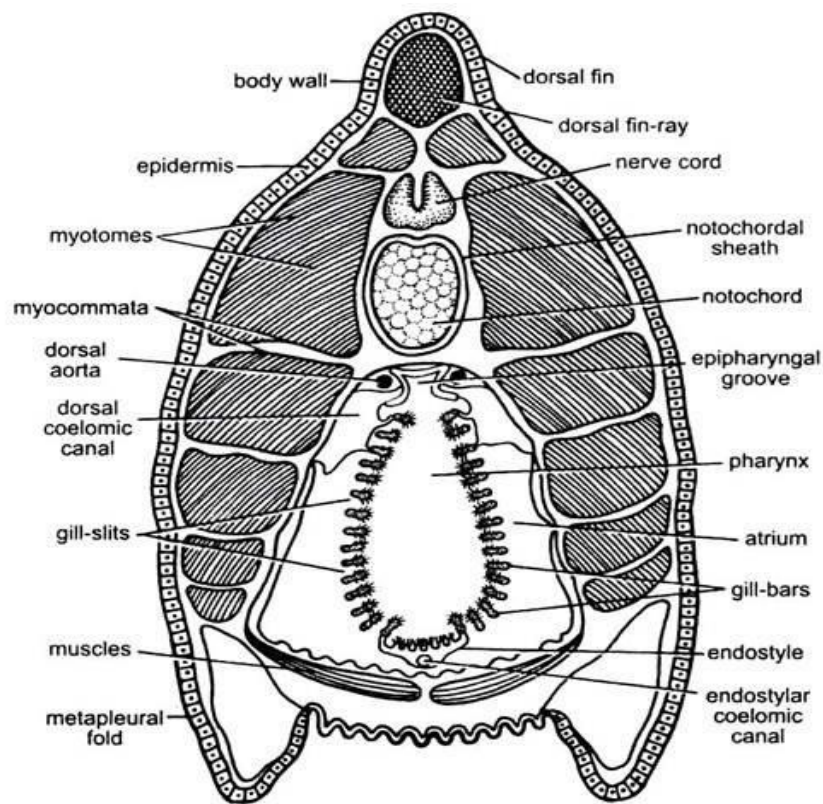


Fig.3.2 T.S. of *Amphioxus* through anterior pharynx

Comments:

1. Body wall is formed of epidermis which is composed of a single layer of single layer of simple columnar epithelium.
2. Dorsal fin containing the dorsal fin ray lies at the dorsal surface.
3. **Myotomes** and **myocommata** of both the sides alternate with each other.
4. Dorsal tubular nerve cord is present below the dorsal fin.

5. Notochord comprising of vacuolated cells is surrounded by notochordal sheath and lies below the nerve cord.
6. The pharynx is perforated by several gill-slits which on either side separated by primary and secondary gill-bars.
7. The dorsal aortae are present, one on either side of the epipharyngeal groove.
8. The coelom appears as dorsal coelomic canals on either side of the epipharyngeal groove. Parts of coelom are also present in the endostyle and in metapleural folds.
9. The metapleural folds are present on the ventral side.

3. T.S Amphioxus through posterior- pharynx showing testes and liver diverticulum

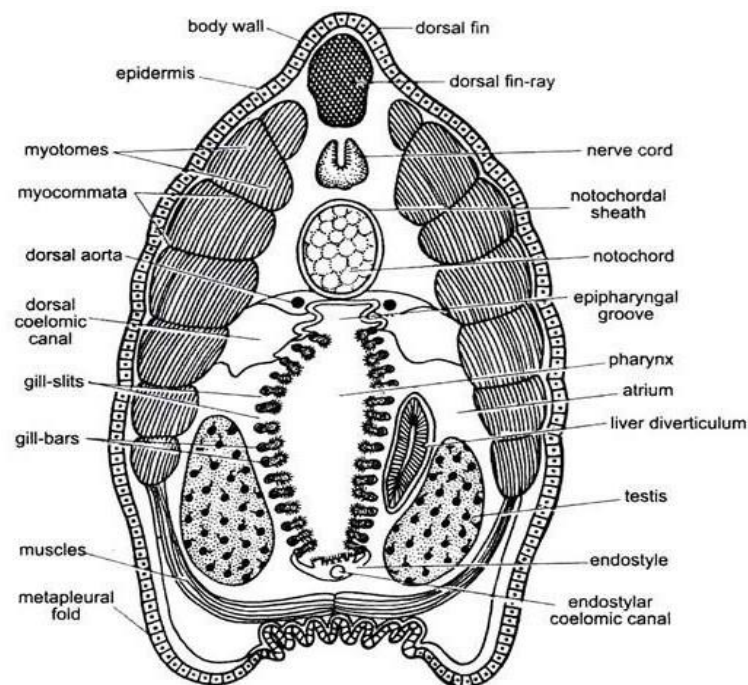


Fig. 3.3 T.S. of Amphioxus through posterior pharynx showing testes and liver diverticulum

Comments:

1. Body wall is formed of epidermis which is composed of single layer of simple columnar epithelium.
2. Dorsal fin having the dorsal fin ray is present on the dorsal surface.
3. **Myotomes** separated by **myocommata** are present on both the sides.
4. **Nerve cord** contains a central canal and lies below the dorsal fin ray.
5. **Notochord** composed of vacuolated cells and surrounded by notochordal sheath, lies below the nerve cord.

6. The pharynx is perforated by numerous **gill-slits**.
7. The atrium is present around the pharynx.
8. The liver **diverticulum** lies on the right side of the pharynx.
9. The testes, one pair in the section, lie in the atrium on both the sides of the pharynx.

4. T.S. Amphioxus through posterior-pharynx showing ovaries and liver- diverticulum

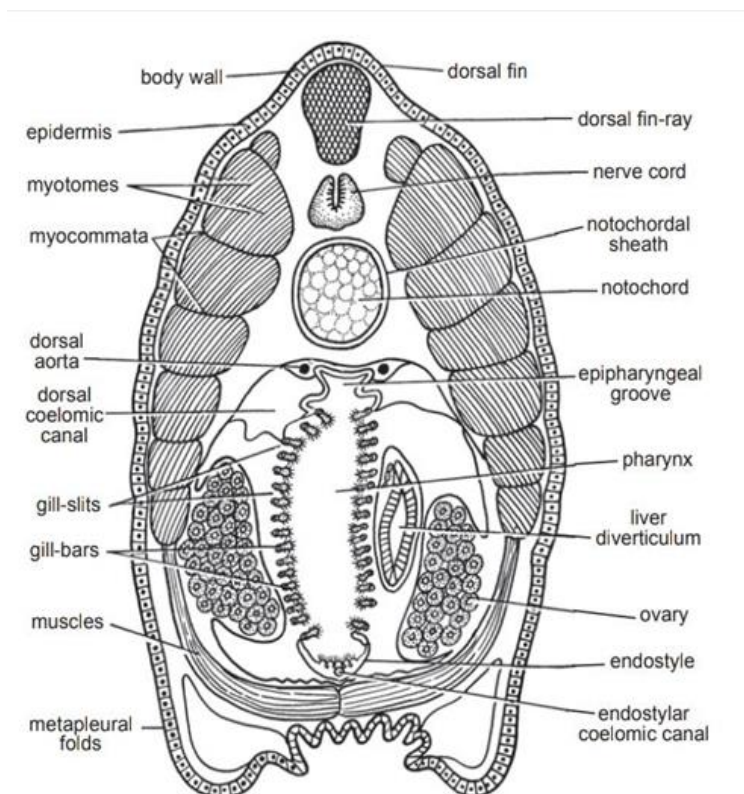


Fig.3.4 T.S. of Amphioxus through posterior region of pharynx showing liver-diverticulum and ovaries

Comments:

1. Body wall is formed of epidermis which is composed of single layer of simple columnar epithelium.
2. Dorsal fin having the dorsal fin ray is present on the dorsal surface.
3. **Myotomes** separated by **myocommata** are present on both the sides.
4. **Nerve cord** contains a central canal and lies below the dorsal fin ray.
5. **Notochord** composed of vacuolated cells and surrounded by notochordal sheath, lies below the nerve cord.
6. The pharynx is perforated by numerous **gill-slits**.
7. The atrium is present around the pharynx.
8. The liver **diverticulum** lies on the right side of the pharynx.

9. The **ovaries** contain several ova.
10. On both sides two **metapleural folds** are present.

5. T.S. of *Amphioxus* through atriopore

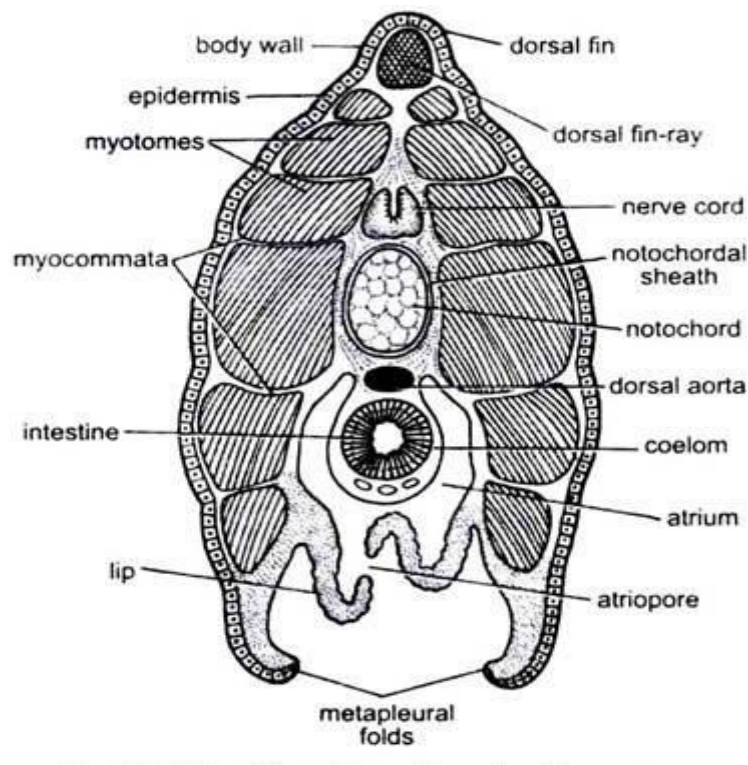


Fig.3.5 T.S. of Amphioxus through atriopore

Comments:

1. Body wall is formed of epidermis which is composed of single layer of simple columnar epithelium.
2. **Myotomes** and **myocommata** of both the sides alternate with each other.
3. **Dorsal fin** having the **dorsal fin ray** is present on the dorsal surface.
4. Dorsal tubular nerve cord lies in between the myotomes of both the sides below the dorsal fin ray.
5. Notochord comprising of vacuolated cells is surrounded by notochordal sheath and lies below the nerve cord.
6. Single median dorsal aorta is seen ventral to the notochord.
7. The coelom is reduced and surrounds the intestine;
8. The intestine is circular and lies in the centre of section.

9. The atrium which occupies the ventro-lateral part of the coelom, opens ventrally by an atriopore between a pair of thickened lips.

6. T.S. of Amphioxus through anal region

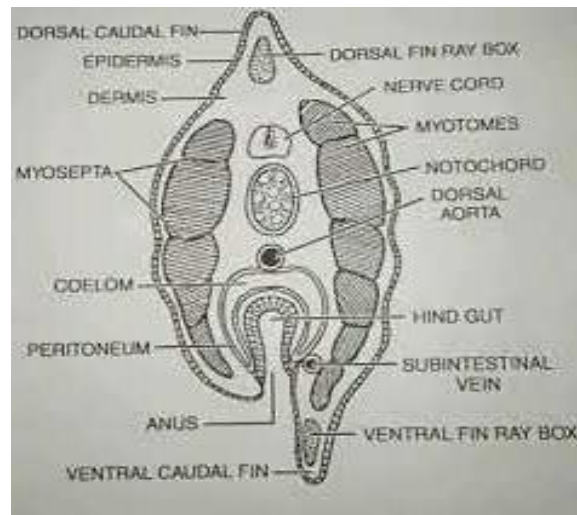


Fig.3.6 T.S of Amphioxus through anal region

Comments:

1. Body wall comprises single layer of **epidermis**.
2. **Dorsal fin** containing **dorsal fin –ray** is present on the dorsal surface.
3. **Myotomes** separated by **myocommata** are present on both the lateral sides reaching down the ventral side.
4. Dorsal tubular nerve cord lies below the dorsal fin ray.
5. Notochord comprising of vacuolated cells is enclosed by notochordal sheath, lying below the nerve cord.
6. Dorsal aorta lies just below the notocord.
7. Coelom is reduced and surrounds the intestine dorsally as well as laterally.
8. Anus lies on the left side of the ventral fin.
9. Ventral fin is well developed.
10. The atrium and metapleural folds are absent.

7. T.S. of Amphioxus through caudal region

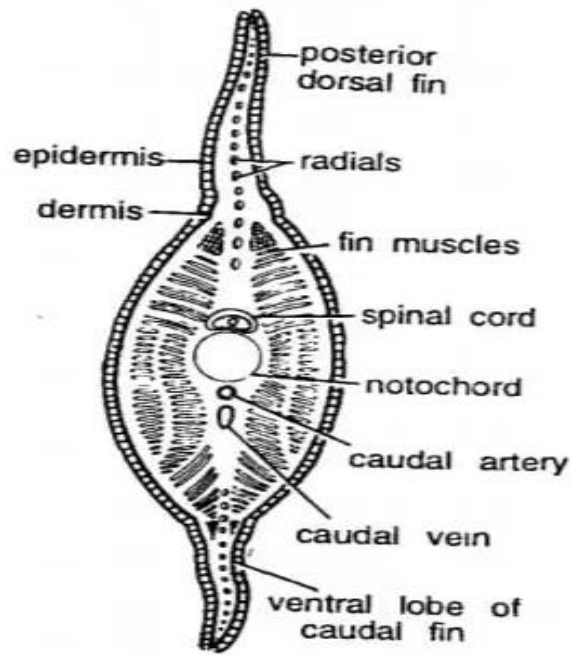


Fig.3.7 T.S. of *Amphioxus* through caudal region

Comments:

1. Body wall comprises single layer of epidermis which is composed of simple columnar epithelium.
2. Dorsal and ventral fins containing the respective fin rays are also present.
3. **Myotomes** separated by **myocommata** are present on both the sides.
4. Dorsal tubular nerve cord lies below the dorsal fin ray.
5. Notochord is surrounded by myocommata sheath and composed of vacuolated cells. It occupies the central portion of the section.
6. The intestine, coelom and atrium are wanting.
7. Metapleural folds are fold are also absent.

8. Velum of *Amphioxus* (Whole mount)

Comments:

1. Velum of *Amphioxus* is a ventical transverse partition lying at the hinder of the vestibule or buccal cavity.
2. It is composed of velar - ring, sphincter and velar – tentacles.
3. The velar- ring is quite a thick layer around the velar tentacles.
4. The sphincter composed of circular muscle fibres and controls the working of velar-tentacles.

5. The velar-tentacles having sensory papillae are 10-12 in number arising from the velar- ring and projecting into the enterostome.
6. The **enterostome** is the opening of the velum in the vestibule.
7. The velum acts as a sieve in the filtration of food particles.

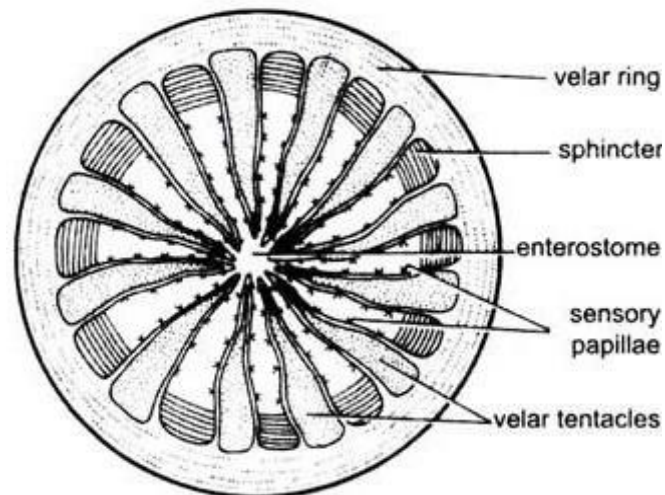


Fig.3.8 Velum of Amphioxus

9. Oral hood of Amphioxus (Whole mount)

Comments:

1. The **oral hood** guards the buccal cavity or vestibule of *Amphioxus*.
2. It is composed of numerous oral cirri and a central cavity.
3. The **oral cirri** are long processes, 10-12 in number arising from the wall of the vestibule.
4. Each oral cirri contains a skeletal- rod and bears small sensory papillae on its outer surface.
5. The vestibule is thick and muscular.

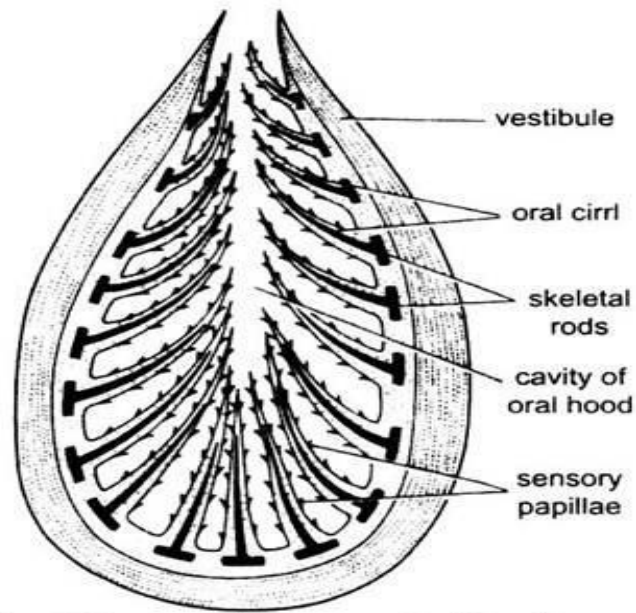


Fig.3.9 Oral hood of Amphioxus

II) *Balanoglossus*

10. T.S. of proboscis of *Balanoglossus*

Comments:

1. Body wall is composed of single layer of epidermis.
2. Nervous layer intra- epidermal because it lies below the epidermis.
3. A basement membrane is present just below the nervous layer.
4. The proboscis coelom is very much reduced due to development of radiating bands of connective tissue and muscle fibres.

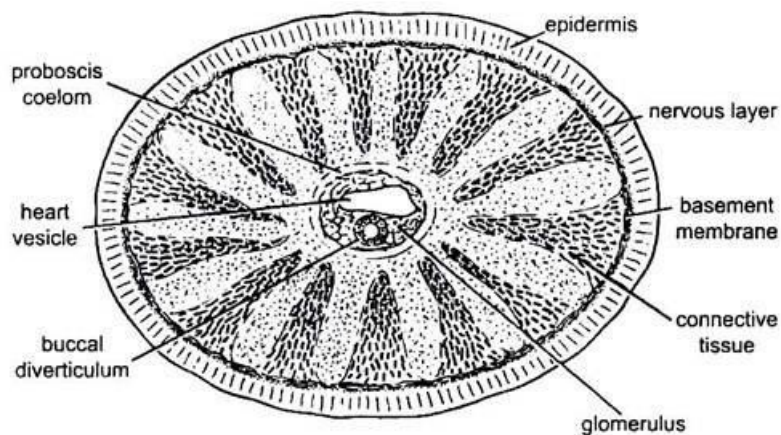


Fig.3.10 T.S of proboscis of Balanoglossus

5. In the centre of the section there is a central complex.
6. The central complex includes the **buccal diverticulum**, **glomerulus** and **heart vesicle**.

11. T.S

collar of *Balanoglossus*

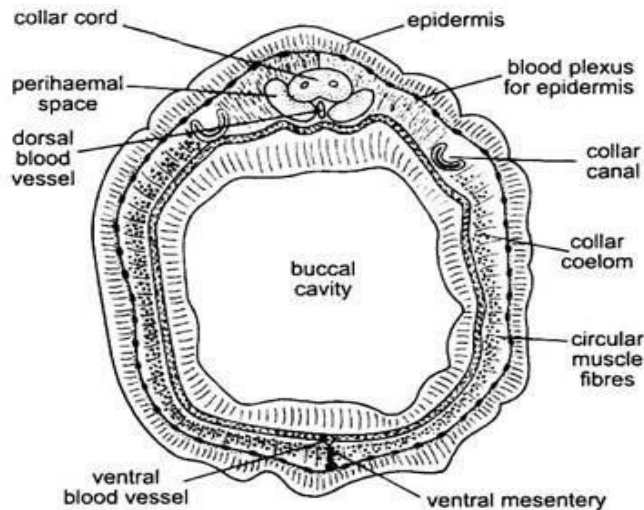


Fig.3.11 T. S. of collar of Balanoglossus

Comments:

1. Body wall is composed of **epidermis**.
2. Epidermis is provided with blood plexus on its inner side.
3. Below the epidermis lies the **collar coelom** divided by the dorsal and ventral mesenteries.
4. The collar coelom is filled by the connective tissue.
5. In the dorsal portion a **collar cord**, **dorsal blood vessel** and two **perihaemal spaces** are present.
6. Two **collar canals** are present in the dorsal portion.
7. **Ventral blood vessel** lies above the ventral mesentery.
8. Circular **muscle fibres** form a layer lining the collar coelom.
9. Spacious buccal cavity lined with epithelium is present in the center.

12. T.S. of branchiogenital region of *Balanoglossus*

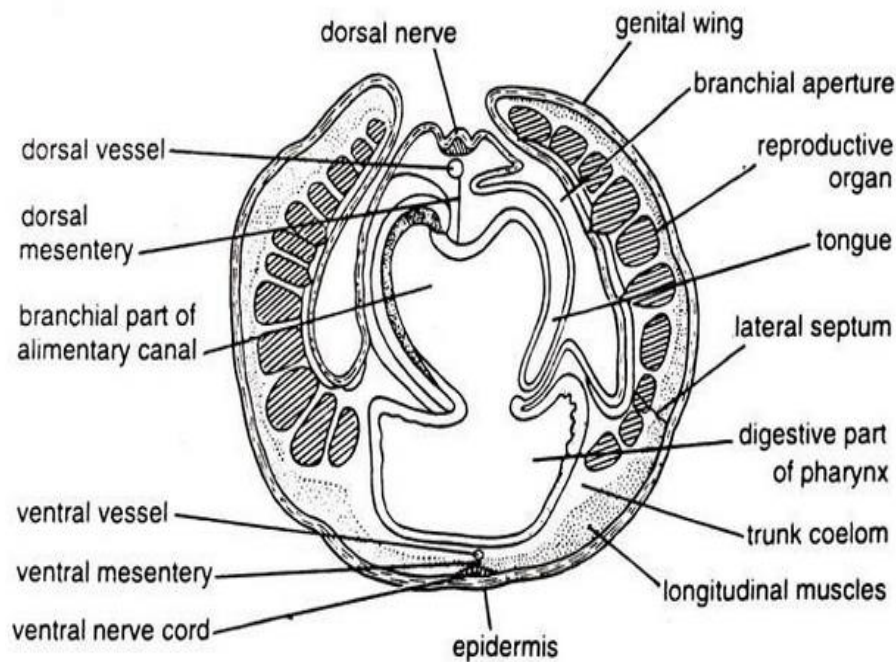


Fig.3.12 T.S. of branchiogenital region of Balanoglossus

Comments:

1. Outer layer is of skin without distinction of epidermis and dermis.
2. A pair of genital wings is present.
3. The genital wings contain numerous gonads arranged in series along its inner lining and blood vessels.
4. Pharynx is seen in the center. It is divided into an upper portion, the **pore- pharynx** for respiration and lower portion the **digestive- pharynx**.
5. The pore-pharynx communicates to the outer side by lateral branchial aperture.
6. **Dorsal blood vessel** and **dorsal nerve cord** lie above the pore-pharynx.
7. **Ventral blood vessel** and **ventral nerve cord** lie below the digestive-pharynx.
8. The **gonads** are lined with epithelium.
9. Two **branchial vessels** are seen at the junction of pore-pharynx and digestive-pharynx.

13. T.S. of post-hepatic intestine of *Balanoglossus*

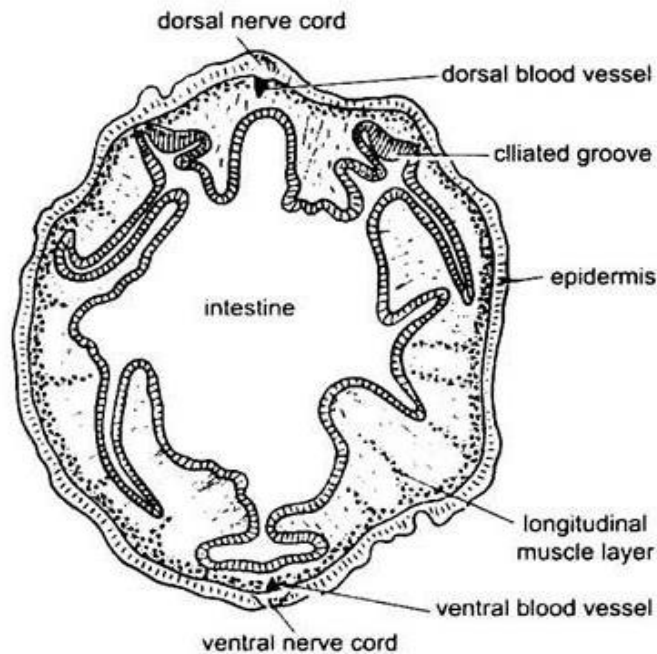


Fig.3.13 T.S. of post-hepatic intestine of *Balanoglossus*

Comments:

1. Epidermis is the outermost layer and consists of single layer of cells.
2. On the dorsal side dorsal nerve cord and dorsal blood vessel are seen.
3. Intestine has a pair of dorso-lateral ciliated grooves on either side.
4. In the center a large lumen of intestine having numerous grooves is present.
5. Intestine is lined by a single layer of flattened epithelial cells.
6. On the ventral side ventral blood vessel and ventral nerve cord are present.
7. Several layers of longitudinal muscle fibres are present between the epidermis and the wall of the intestine.

3.3.2 CHORDATES

I) Slides of fishes

14. T.S. *Scoliodon* through the olfactory region

Comment:

1. The outermost surface is covered by integument bearing the numerous placoid scales.

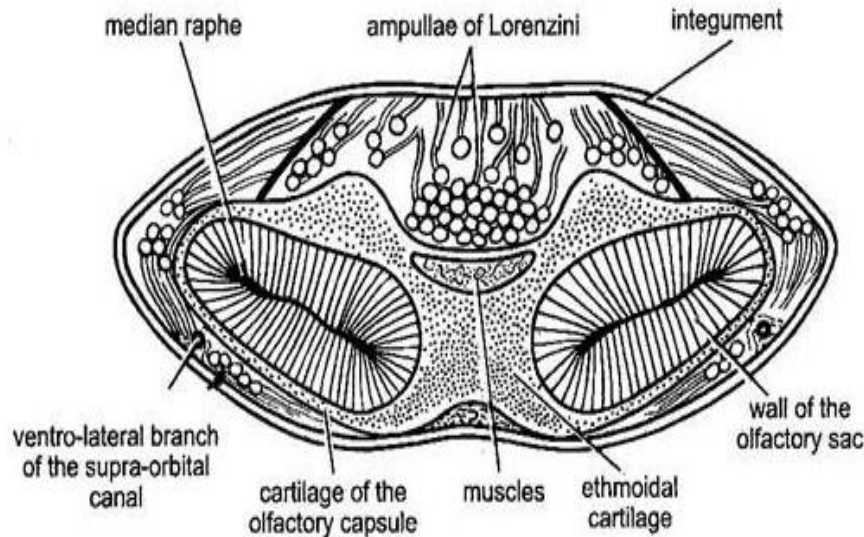


Fig.3.14 T.S. of Scoliodon through olfactory region

2. On the lateral side of the section, two ellipsoidal and large structures thesection of olfactory sacs are seen.
3. Each olfactory sac is covered externally by a thin membrane and is lodged on each side into cartilaginous **olfactory capsule**.
4. The epithelium of folds consists of olfactory receptor cells intermixed with stiff supporting cells.
5. The central portion of the section is occupied by ethmoidal cartilage.
6. Numerous ampullae of Lorenzini are present above the ethmoidal cartilage and on the lateral sides of the cartilage of olfactory capsules.

15. T.S. of Scoliodon through the branchial region

Comments:

1. The outer surface is covered by integument comprising the epidermis.
2. Well developed myotomes separated by myocommata are seen in the dorsal half portion.

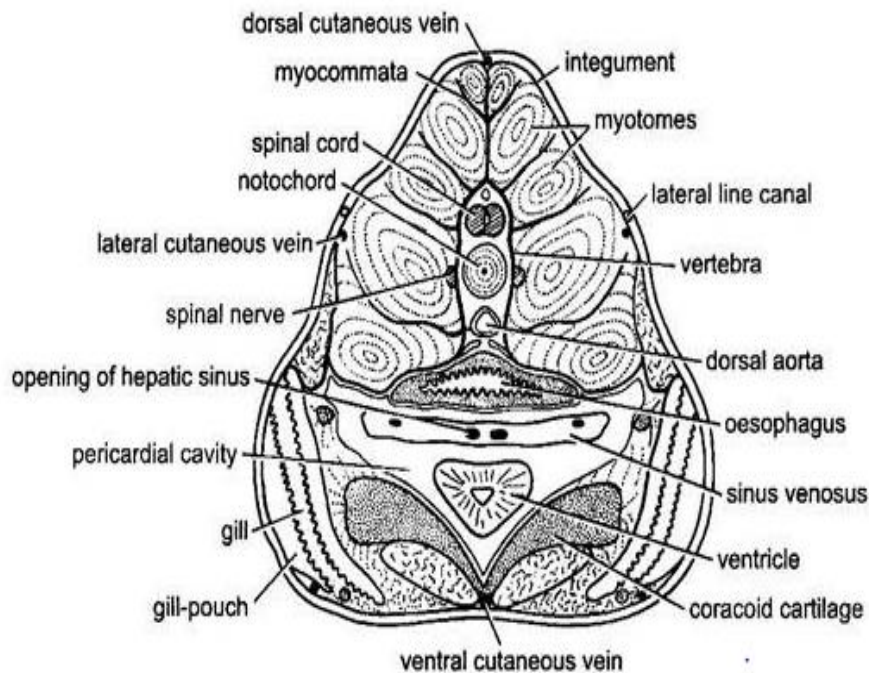


Fig.3.15 T.S. of *Scoliodon* through branchial region

3. The myotomes have concentrically arranged muscle lamellae and myocommata composed of connective tissue.
4. In the median line in between the myotomes of both the sides lies the cartilaginous vertebra having the spinal cord in the neural canal.
5. Just below the vertebra lies the dorsal aorta.
6. Below the dorsal aorta lies thick walled oesophagus.
7. Pericardial cavity contains a narrow sinus venosus and a small triangular ventricle.
8. Coracoid cartilages are seen below the pericardium.
9. On either side of the pericardial cavity and coracoids cartilages in seen an obliquely placed gill between two gill-pouches.

16. T.S. of *Scoliodon* through stomach and liver

Comments:

Transverse section of *Scoliodon* passing through the stomach and liver region shows the following structures:

1. The outer surface is covered by the integument comprising the epidermis and dermis.
2. Well developed myotomes separated by myocommata are seen in the dorsal half portion.

3. The myotomes have concentrically arranged muscle lamellae and the myocommata comprised of the connective tissue.

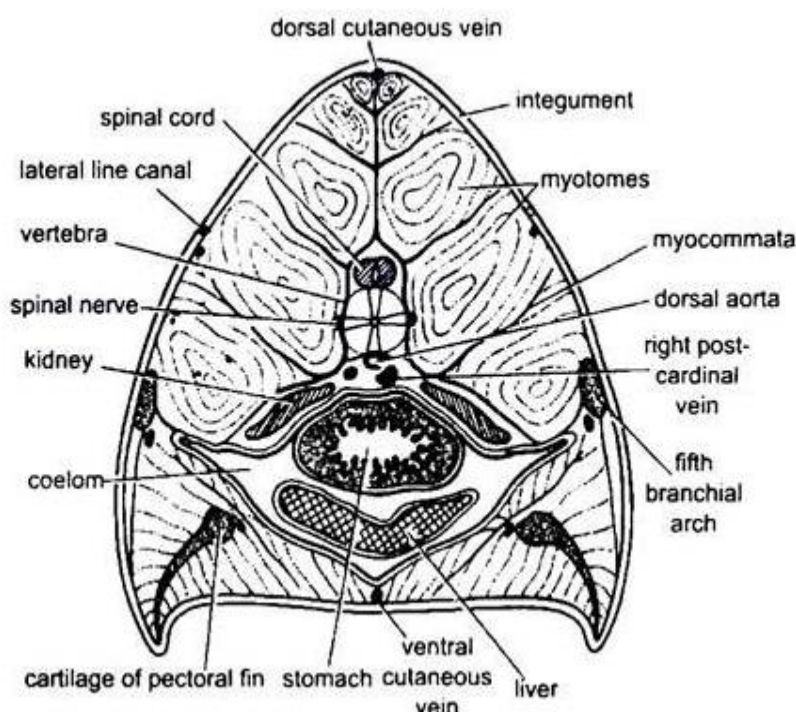


Fig.3.16 T.S. of Scoliodon through stomach and liver

4. In the median line in between the myotomes of both the sides lies the vertebra enclosing the spinal cord.
5. Just below the vertebra lies the dorsal aorta.
6. A spacious coelomic cavity lined by coelomic epithelium is seen in the ventral portion.
7. Coelom contains the stomach and liver.
8. The stomach has a large lumen and numerous villi.
9. The sections of two lobes of liver are seen below the stomach.
10. Above the coelomic cavity two kidneys separated by posterior cardinal veins are seen.
11. Cartilages of pectoral fins are seen on both the lateral sides in the ventral portion.

17. T.S. of *Scoliodon* through the intestine

Comments:

1. The outer surface is covered by the integument.
2. The myotomes are well developed separated by the myocommata.

3. The myotomes have concentrically arranged muscle lamellae and the myocommata are made up of connective tissue.
4. In between the myotomes, in the median line lies the vertebra enclosing the **notochord** and the **spinal cord**.
5. **Dorsal aorta** having **cardinal** veins on its lateral sides, lies below the vertebra.
6. Below the dorsal aorta lies the kidney. Kidney is more or less inverted V- shaped in structure.

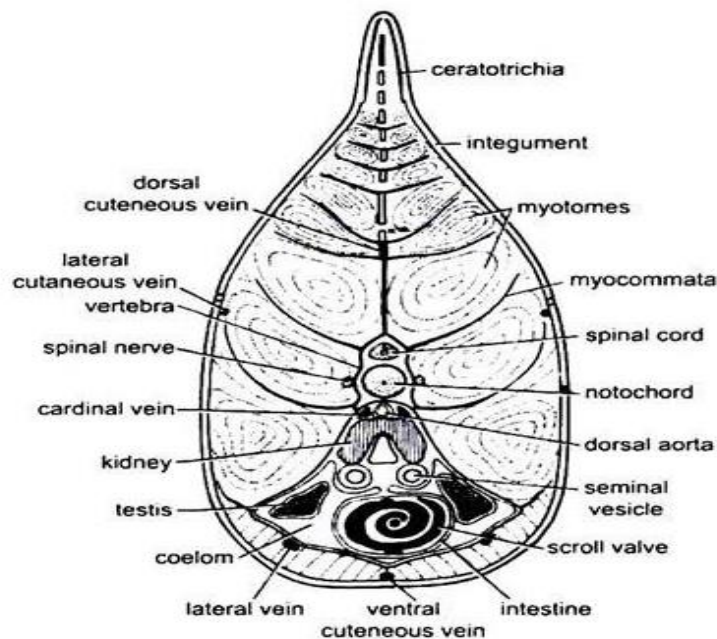


Fig.3.17 T.S. of Scoliodon through the intestine

7. The outer surface is covered by the integument.
8. The myotomes are well developed separated by the myocommata.
9. The myotomes have concentrically arranged muscle lamellae and the myocommata are made up of connective tissue.
10. In between the myotomes, in the median line lies the vertebra enclosing the **notochord** and the **spinal cord**.
11. **Dorsal aorta** having **cardinal** veins on its lateral sides, lies below the vertebra.
12. Below the dorsal aorta lies the kidney. Kidney is more or less inverted V- shaped in structure.
13. Just below the kidney lies the hollow seminal vesicle in the male and uterus in the female.

14. The intestine lies in the centre below the seminal vesicles.

15. In the male testes lie on either side of the intestine and in female ovary lies towards the right side.

18. T.S. of Scoliodon through the base of pelvic fin of male and female

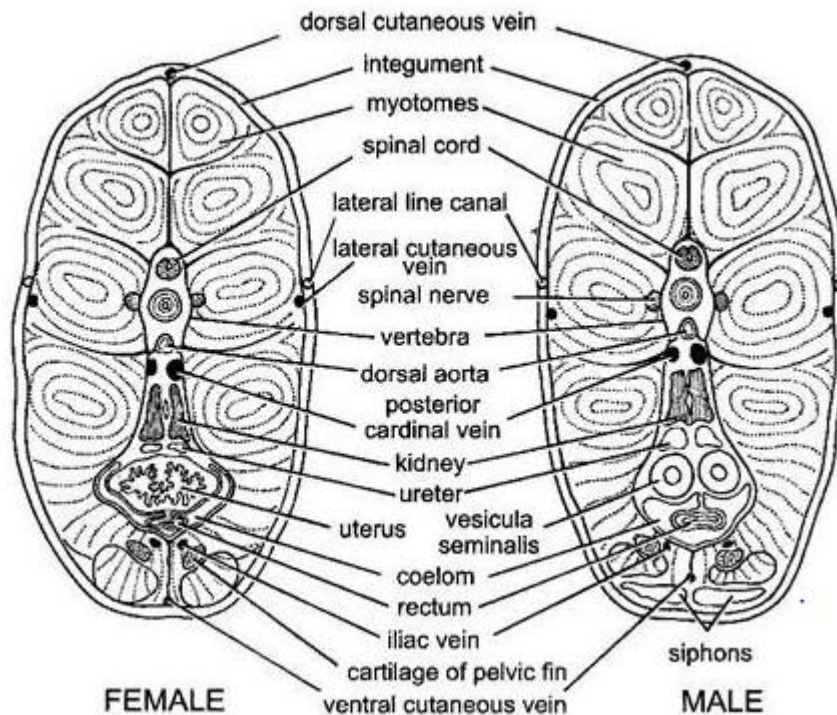


Fig.3.18 T.S. Scoliodon through the base of pelvic fin of male and female

Comments:

1. The outer surface is covered by the **integument**.
2. The **myotomes** are well developed and separated by the **myocommata**.
3. The myotomes have concentrically arranged muscle lamellae and the myocommata are made up of connective tissue.
4. In the median line in between the myotomes lies the vertebra enclosing the notochord and **spinal cord**.
5. **Dorsal aorta** lies below the vertebra.
6. Two **posterior cardinal** veins lie below the dorsal aorta.
7. Kidneys and ureters also lie below the posterior cardinal veins.
8. In the female two uteri fused together to form a single uterus occupying the major ventral portion.

19. Ampulla of Lorenzini

Comments:

1. Each ampulla is made up of **ampullary sac**.
2. Each ampullary sac consists of eight to nine radially dilated chambers arranged round a central core, the centrum.
3. Each ampullary sac is connected with a long tubule which opens at the surface of the head through a pore known as external aperture.
4. All the groups of ampullae are innervated by the nerve branches of ophthalmicus superficialis, buccalis and hyomandibularis.
5. The ampullae lie together in clusters looking like bunches of grapes.
6. The ampullae of Lorenzini are thermoreceptors (temperature receptors) of sharks and rays and are present on the dorsal surface of the head.

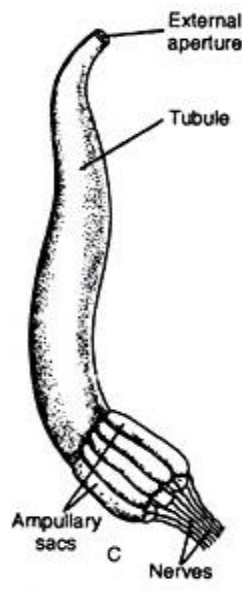

Fig.3.19 Ampulla of Lorenzini

20. Placoid scale of Scolidon (whole mount)

Comments:

1. Placoid scales are arranged in regular oblique rows, covering the entire surface of the body and form the exoskeleton of the shark.
2. Placoid scales are small pointed and tri-radiate denticies found embedded in the dermal layers of the skin.

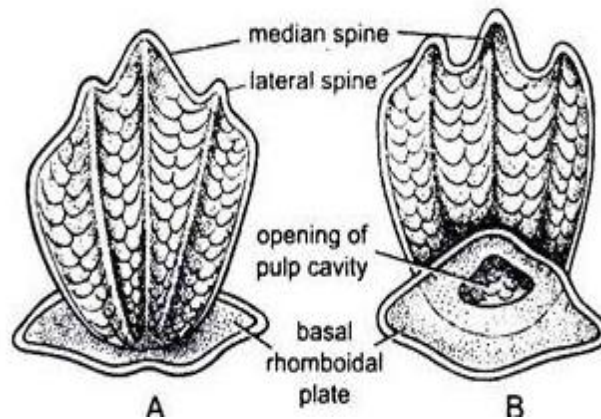


Fig.3.20 Placoid scale of Scoliodon. A. Dorsal view B. Ventral view

3. A typical placoid scale consists of a diamond-shaped or rhomboidal basal plate having plate having an opening of the pulp cavity and flat trident spine.
4. The basal plate is formed of atrabecular calcified tissue, the cement.
5. The spine is composed of hard calcareous substance, the dentine which is coated externally with hard and dense enamel.
6. The pulp cavity contains the vascular connective tissue, pulp containing numerous odontoblasts, blood vessels, nerves and lymph chambers.
7. Placoid scales are found in sharks, rays and skates.

21. Cycloid scale (whole mount)

Comments:

1. Cycloid Scales are found in teleosts and dipnoi.
2. These are soft and dermal plates.
3. Each cycloid scale is roughly circular and flattened.

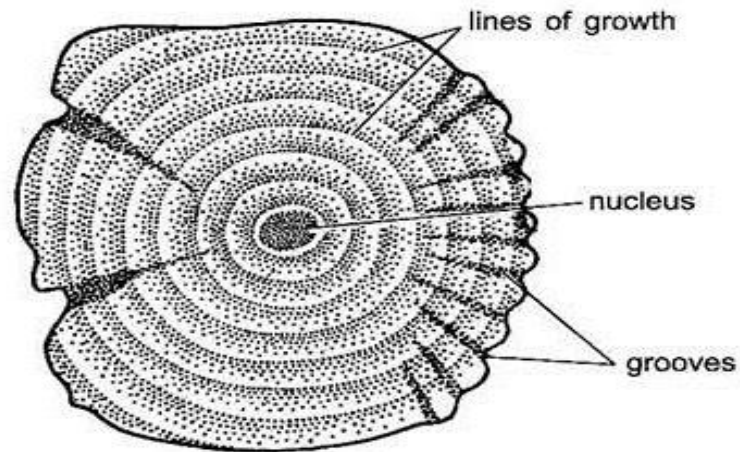


Fig.3.21 Cycloid scale

4. Each scale is composed of a central nucleus and numerous lines of growth.
5. The anterior border is more or less rounded and remains exposed.
6. The posterior part of the scale is having numerous longitudinal grooves for sucking the nourishment from the skin.
7. Pulp cavity and dentine are entire absent.
8. Cycloid scales are derivatives of the ganoid scales in which ganoin and cosmine layers and bone cells are lost.

22. Ctenoid scale (whole mount)

Comments:

1. Ctenoid scales are commonly found in teleosts and actinopterygian fishes.
2. These are soft and dermal plates.
3. Each ctenoid scale is flat and rather oval in shape.
4. Each ctenoid scale is composed of a central nucleus and numerous lines of growth.

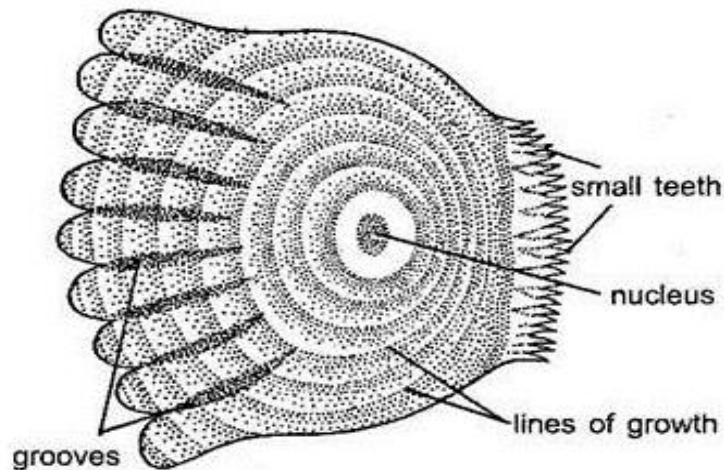


Fig.3.22 Ctenoid scale.

5. The anterior free border bears numerous small teeth like structure.
6. Numerous longitudinal grooves are present on the posterior border and as such these grooves are used for sucking the nourishment from the skin.
7. Pulp cavity and dentine are entirely absent.
8. Ctenoid scales are derivatives of ganoid scales in which ganoin, cosmine layers and bone cells are lost.

II) Slides of Amphibia

23. V. S. of skin of frog

Comments:

Vertical section of skin of frog shows the following histological structure:

1. The skin consists of two distinct principal layers, the other epidermis and inner dermis.
2. The epidermis is made up of outer stratum of flattened horny cells arranged in several layers which is cast off as squamous epithelium and an inner layer of stratum Malpighi.
3. The dermis consist of connective tissue which is differentiated into two distinct layers, i.e., outer spongy layer and inner compact layer.
4. The spongy layer is composed of an areolar tissue and contains mucous glands, melanophores, blood vessels, nerve fibres and lymph spaces, etc.
5. Mucous glands are flask-shaped, opening on the surface of the skin. They originate from the stratum Malpighi and their body lies in dermis.

6. Melanophores are colour pigments present in the dermis and imparting characteristic colour to the frog.

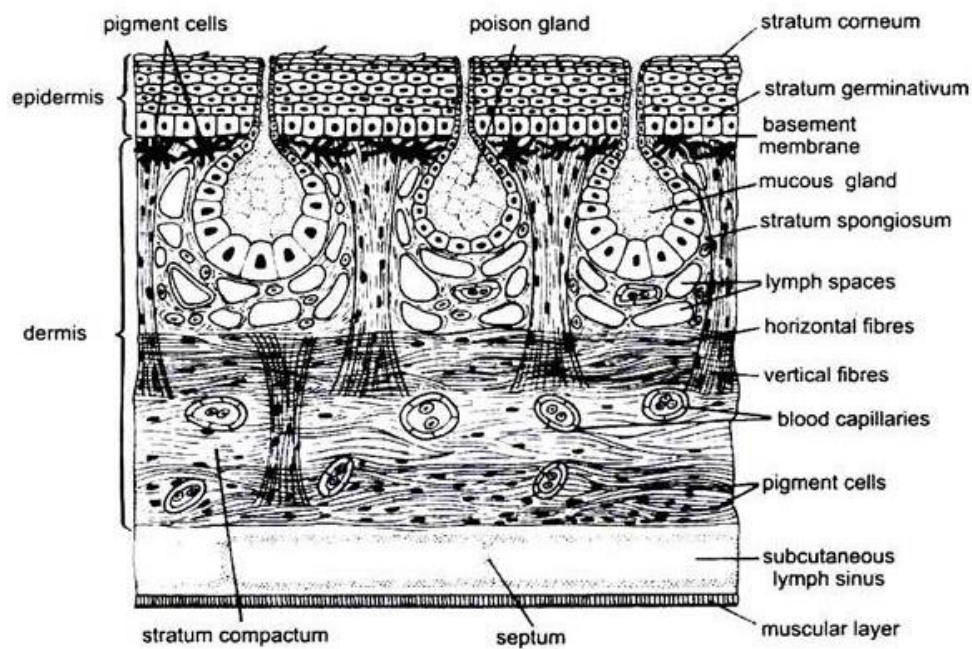


Fig.3.23 V.S. of skin of frog.

7. The compact layer is made up of compact fibrous connective tissue having horizontal and vertical strands.

8. The outer most covering of the skin is mucous layer which makes it slimy and slippery.

24. T.S. oesophagus of frog

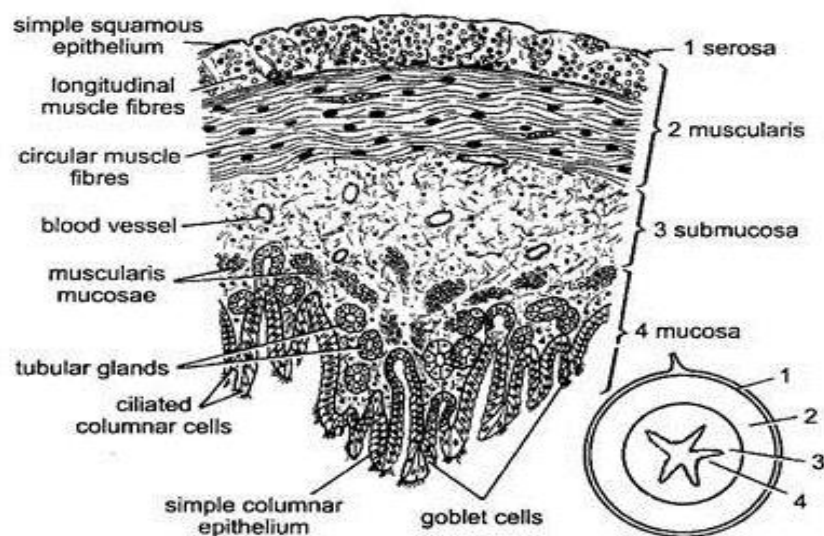


Fig.3.24 T.S. Oesophagus of frog

Comments:

Transvers section of oesophagus of frog shows the following structures:

1. It is composed of usual four layers i. e., serosa, muscularis, submucosa and mucosa.
2. The serosa is thin and made up of a single layer of peritoneal cells.
3. The muscularis, the muscle fibres of which are arranged in two layers an outer longitudinal and inner circular layer.
4. The outer longitudinal muscle layer is thin inner circular muscle is thick.
5. Submucosa lies below the muscular layers. It is composed of thick and broad layer of loose connective fibres.
6. Submucosa contains spotted blood vessels in its layer.
7. The mucosa consists of simple columnar cells.
8. The muscularis mucosa is in the form of scattered patches of muscle fibres and lie below the submucosa.
9. The mucosa also contains simple branched tubular glands. Several cross sections of tubular glands are seen in the connective tissue of mucosa.

25. T.S. of stomach of frog

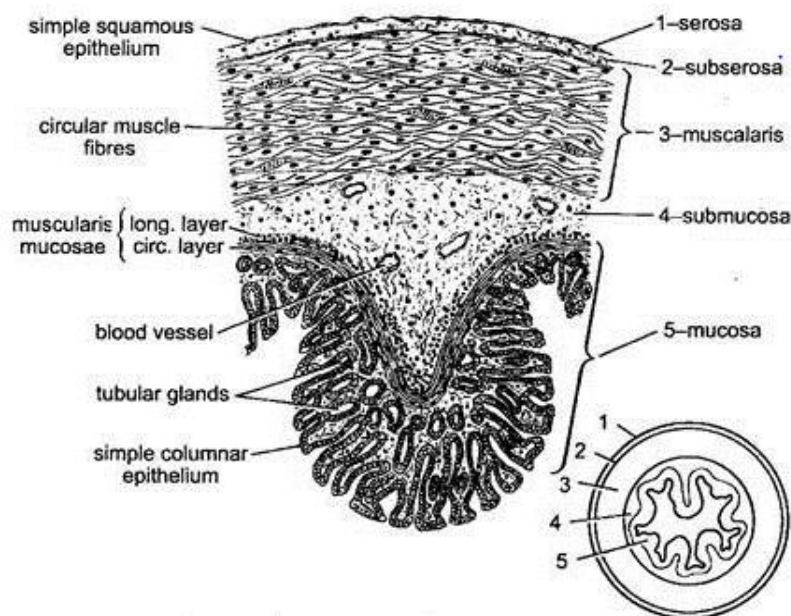


Fig.3.25 T.S. of stomach of frog

Comments:

Transvers section of stomach of frog shows the following structures:

1. It is composed of five layers, i.e., serosa, subserosa, muscularis, submucosa and mucosa.
2. The serosa is thin and made up of a single layer of peritoneal cells.
3. The muscularis, the muscle fibres of which are arranged in two layers, an outer longitudinal and inner circular layer.
4. The muscularis consists of a thick and prominent layer of circular muscle fibres.
5. The submucosa lies below the circular muscle fibres and made up of loose connective tissue fibres containing blood vessels.
6. The muscularis mucosa is well developed and lies below the submucosa. It consists of an outer longitudinal layer and inner circular layer.
7. The mucosa is the innermost layer and consists of simple columnar epithelium. It gives rise to simple and branched tubular glands.
8. The tubular or gastric glands open into the lumen of stomach through narrow ducts and secrete pepsin and HCL.

26. T.S. of intestine of frog

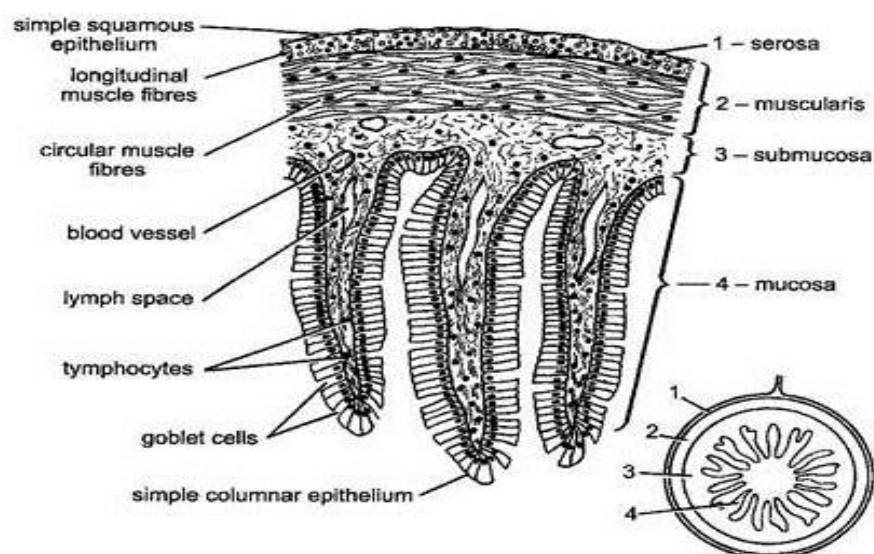


Fig.3.26 T.S. intestine of frog

Comments:

1. It consists of the usual four layers, serosa, muscularis, submucosa and mucosa.
2. The serosa is very thin and made up of single layer of peritoneal cells.
3. The muscularis consists of two layers, an outer thin layer of longitudinal muscle fibres and an inner thick layer of circular muscle fibres.

4. The submucosa consists of loose connective tissue fibres and contains lymph spaces and blood vessels.
5. The mucosa is folded into numerous simple folds or villi.
6. The mucosa is made up of single layer of simple columnar epithelium which is formed of absorptive cells and goblet cells.
7. Muscularis mucosa and tubular glands are ntirely absent.
8. The numerous folds or villi of mucosa increase the maximum absorptive surface.

27. T.S of rectum of frog

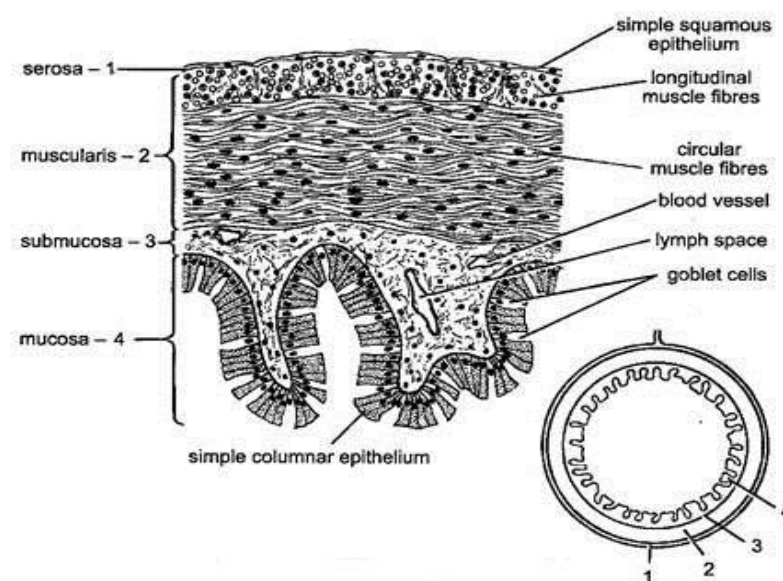


Fig.3.27 T.S. of rectum of frog

Comments:

1. It consists of usual four layers, ie., **serosa, muscularis, submucosa and mucosa.**
2. The **serosa** is very thin and made up of single layer of peritoneal cells.
3. The muscularis consists of two layets, an outer layer of **longitudinal muscle fibres** and an inner layer of **circular muscle fibres.**
4. Both the layers of longitudinal and circular muscle fibres are much thicker than that of the intestine.
5. The sub mucosa is made up of loose connective tissue and contains numerous blood vessels, capillaries and lymph spaces.
6. The layer of submucosa is more extensive than that of intestine.

7. The mucosa is thrown up into numerous smaller folds than that of intestine and therefore, the lumen of rectum is much wider in addition to its original much larger diameter.
8. The mucosa is made up single layer of simple columnar epithelium containing numerous goblet cell.

28. T.S. of liver of frog

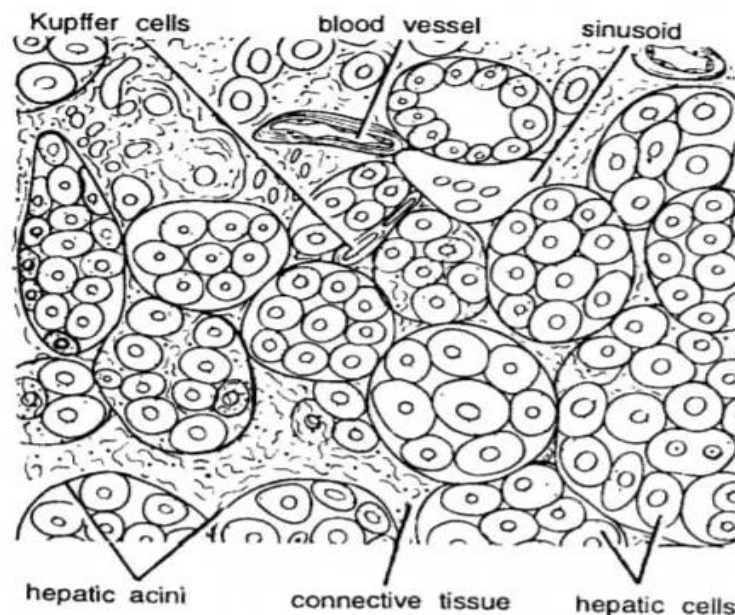


Fig.3.28 T.S. of liver of frog

Comments:

1. It is a compound tubular gland.
2. It consists of a large number of hepatic acini which appear in section lined by hepatic cells.
3. The hepatic acini are made up of granular columnar hepatic cells surrounding bile canalicule in the centre.
4. Each hepatic cell contains a prominent nucleus and granular cytoplasm which indicates its secretory nature.
5. The bile canalicule unite to form the bile ductules and these in turn unite to form bile duct.
6. Blood capillaries and sinusoids or blood spaces are seen among the acini which are formed by the breaking down of the hepatic cells.

7. The structure of the liver helps it in taking the mon-osaccharides from the blood of the hepatic portal vein and in secreting the bile which is drained through the bile duct.

29. T.S. of pancreas of frog

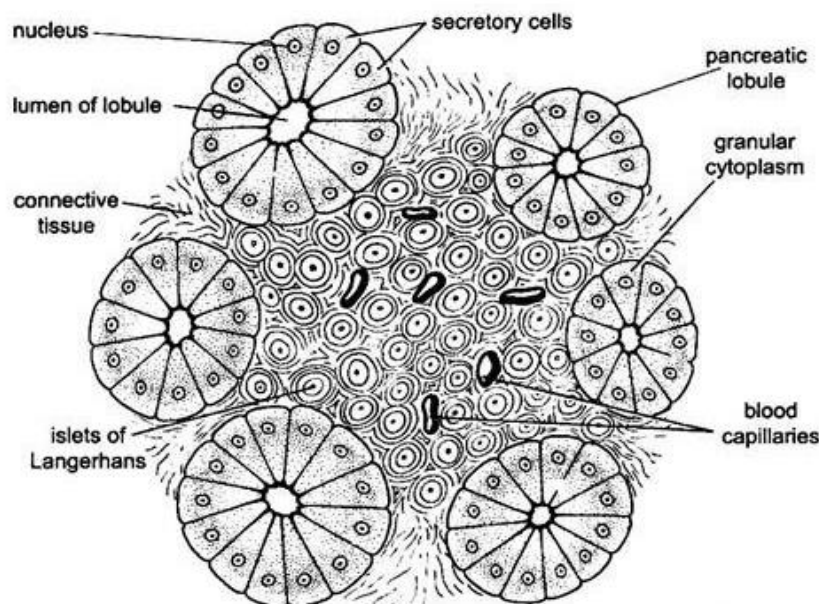


Fig.3.29 T.S. of pancreas of frog

Comments:

Transverse section of pancreas of frog shows the following histological structures:

1. It is a much branched and graps- bunch like gland.
2. It consists of a series of pancreatic lobules.
3. The lobules are bounded by connective tissues.
4. Each lobule consists of a cluster of secretory cells enclosing a very narrow central lumen.
5. Between the pancreatic lobules there are scattered groups of cells which stain paler and are known as **islets of Lanerhans**.
6. **Islets of Lanerhans** are small prism-shaped cells without lumen.
7. Blood vessels are found in and around the islets of Lanerhans.
8. The function of pancreas is dual because it produces exocrine as wellas endocrine secretions.
9. Pancreatic juice contains three digestive enzymes such as amylopsin, trypsin and lipase.

30. T.S of spleen of frog

Comments:

1. The outermost covering which surrounds the spleen is fibrous capsule made up of fibrous tissues.
2. The fibrous capsule sends trabeculae to divide the spleen into lobules.
3. Each splenic lobule is composed of splenic pulp containing splenic nodes, red and white pulps and blood vessels.
4. The spleen has several functions which are as follows:
 - i) It destroys the erythrocytes when they are in the moribund condition.
 - ii) It forms the leucocytes.
 - iii) It produces a secretion which activates the protein enzymes of the pancreas.
 - iv) It also produces the antibody.

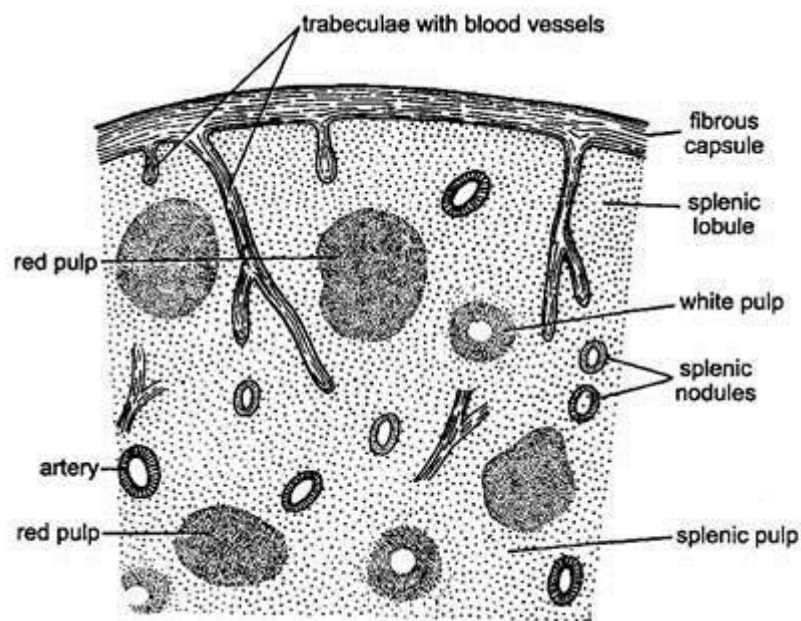


Fig. 3.30 T.S. of spleen of frog

31. T.S. of lung of frog

Comments:

Transverse section of lung of frog shows the following histological structures:

1. The outer wall of the lung is peritoneum consisting of connective tissue which contains some elastic fibres.
2. The peritoneum is covered externally by squamous epithelium.

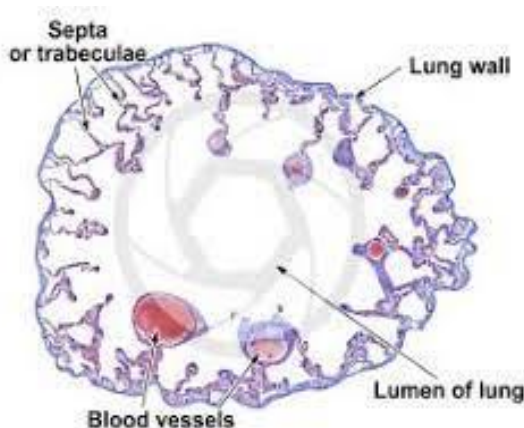


Fig.3.31 T. S. lung of frog

3. The central cavity of lung is partly divided into numerous chambers or alveoli separated from each other by partitions or trabeculae.
4. The trabeculae are lined partly divided by a thin, flattened simple squamous epithelium and partly by a ciliated columnar epithelium on the outer edges.
5. The walls of the trabeculae are richly supplied with blood vessels and capillaries.
6. Numerous bundles of muscle fibres are present within the trabeculae.
7. The respiratory surface is increased by the presence of trabeculae and alveoli.

32. T.S. of kidney of frog

Comments:

Transverse section of kidney of frog shows the following histological structures:

1. The outermost layer covering the kidney is peritoneum.
2. The uriniferous tubules are numerous and seen in various shapes and sizes.
3. The uriniferous tubules are lined by glandular and ciliated epithelium.
4. The Bowman's capsules are cup-shaped, double walled structures.
5. There are afferent and efferent arterioles forming tufts or knots in the Bowman's capsules.
6. The tuft of blood vessels, formed within the Bowman's capsules, is known as glomerulus.
7. The sections of renal artery, renal vein and renal portal vein are also seen.

8. The chief function of kidney is to remove certain non gaseous waste matter like urea, uric acid and certain salts (phosphates and sulphates) that are brought to them from different parts of the body.

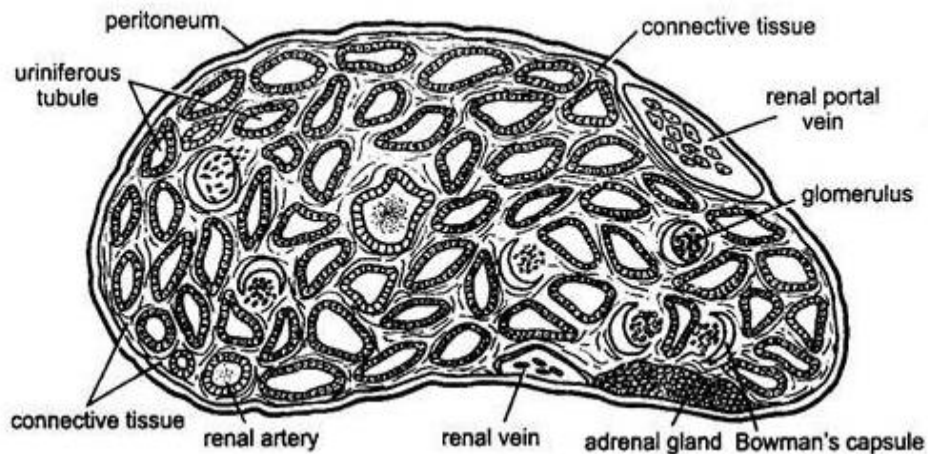


Fig.3.32 T.S. of kidney of frog

33. T.S. of testis of frog

Comments:

Transverse section of testis of frog shows the following histological structures:

1. The outer covering is the peritoneal epithelium or peritoneum.
2. Numerous seminiferous tubules are held together by the inter-tubular connective tissue.
3. Each seminiferous tubule is lined with germinal epithelium whose cells undergo spermatogenesis to produce spermatozoa.
4. Bundles of spermatozoa are seen in the lumen of the mature seminiferous tubules.
5. Spermatogonia, spermatocytes and spermatids are also seen.
6. The connective tissue contains interstitial cells which secrete hormones responsible for the appearance of the secondary sexual characters.
7. Sections of blood vessels are also seen in the connective tissue.
8. Sertoli cells are absent.

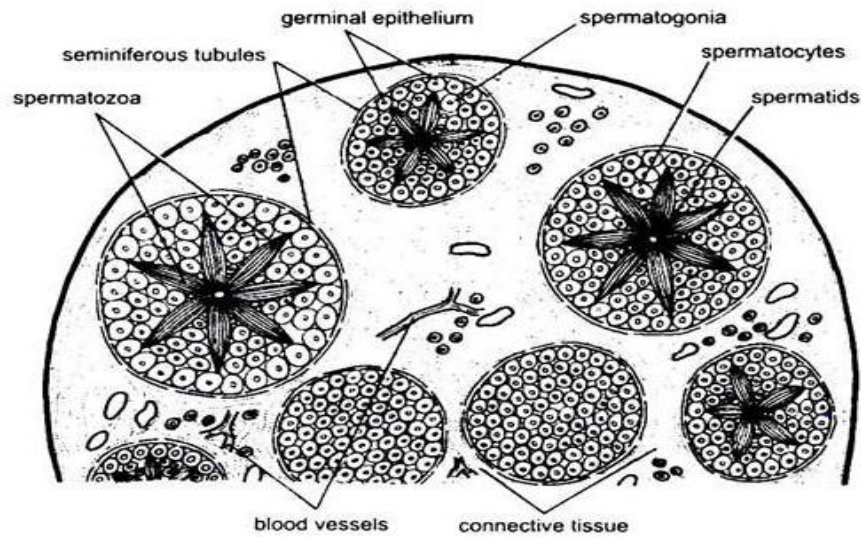


Fig.3.33 T.S. of testis of frog

34. T. S. of ovary of frog

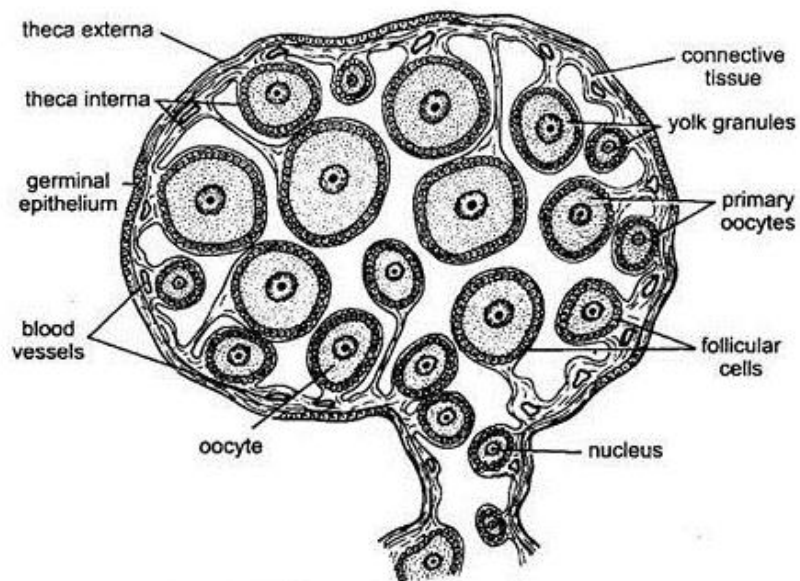


Fig.3.34 T.S. of ovary of frog

Comments:

Transverse section of ovary of frog shows the following histological structures:

1. The ovary consists of a number of hollow lobes or lobules in which ova are formed.
2. Each lobule is surrounded externally by theca externa.
3. Several follicles of various sizes are connected to the theca externa.

4. Each follicle of a lobule is surrounded by theca interna which contains muscle fibres, blood vessels and nerves.
5. Each ovum has a nucleus surrounded by yolky granular cytoplasm.
6. The ovum is also surrounded by follicular cells which develop from oogonia.
7. Small patches of germinal epithelium are lying attached to the theca externa at various places.
8. The germinal epithelium undergoes oogenesis and gives rise to ova which can be seen in various stages of development.
9. Fully formed ova are shed into colomic cavity of ovary.
10. The theca externa, theca interna and follicular cells from the ovarian stroma which secretes ovarian hormones.

35. T.S. of spinal cord of frog

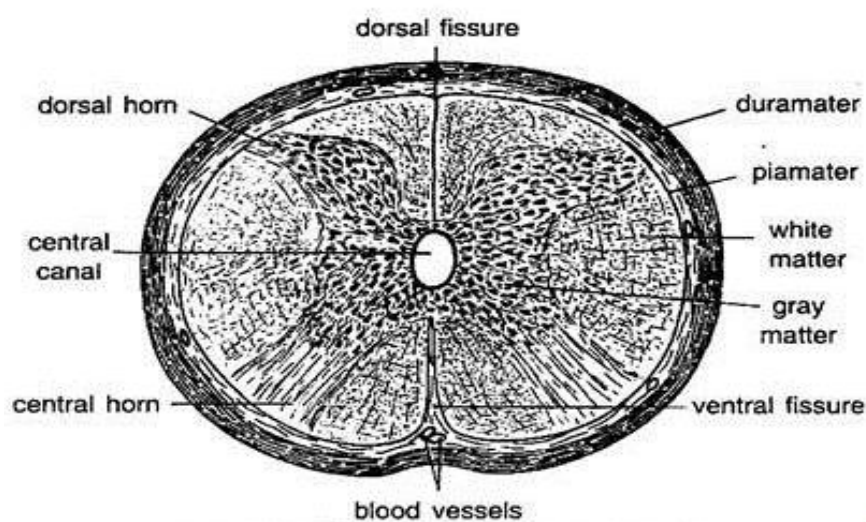


Fig.3.35 T.S. of spinal of frog

Comments:

Transverse section of spinal cord of frog shows the following histological structure:

1. The spinal cord is surround by two fibrous membranes,i.e, duramater and pia mater.
2. The duramater is the thicker and the outer layer.
3. The pia meter is the thinner and the inner layer.
4. The spinal cord is made up of two kinds of nervous tissue, ie., outer white matter and the inner grey matter.
5. The grey matter forms the H-shaped area and composed of ganglion cells.

6. In the centre of grey matter there is a small canal known as **central canal** which is lined by single layer of epithelium. Its functions are presumably to circulate the cerebro-spinal fluid.
7. The grey matter gives rise to four horns, two dorsal and two ventral.
8. The dorsal horns contain single band of nerve fibres, while the ventral horns contain numerous very slender bands of nerve fibres.
9. On its mid-dorsal side present a very slight dorsal fissure and on the mid- ventral side a slightly wide cleft, the ventral fissure.

II) Slide of Birds

36. V.S. of skin of a bird

Comments:

Vertical section of skin of a bird shows the following details:

1. It consists of two layers, the outer epidermis and inner dermis.
2. The outer epidermis is composed of several layers, i.e. epitrichium, stratum corneum and stratum malpighii.
3. The epitrichium is the outer most layers and consists of a single layer of flattened delicate cells.
4. The stratum corneum is the middle layer of cells. It is horny and protective.
5. The stratum malpighii is the inner layer of epidermis and composed of large and cylindrical cells.
6. Feather papilla, calamus of down feather along with barbs is also seen in the epidermal layer.
7. The inner dermis is composed of upper vascular spongy layer and lower compact layer.
8. In the spongy layer dermal papilla of permanent feather, involuntary muscles and blood vessels are seen.
9. The innermost compact layer has patches of fat cells on its upper and lower sides.

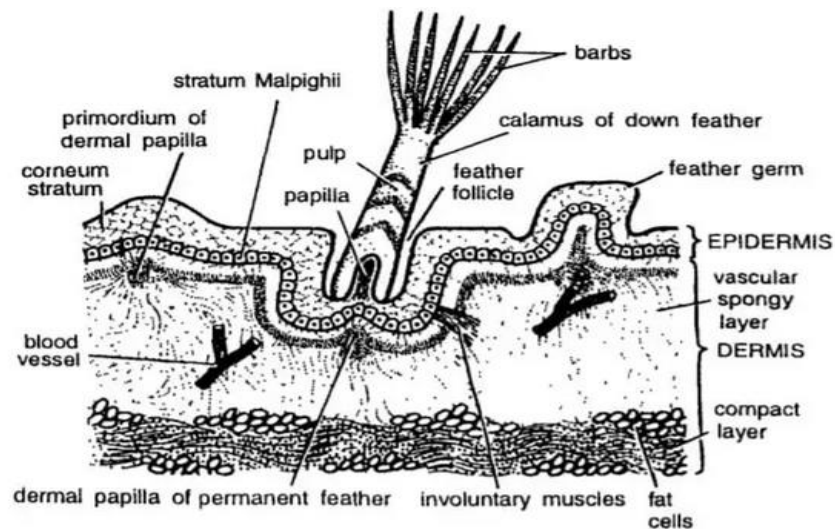


Fig.3.36 V.S. of skin of a bird

III) Slides of Mammalia

37. V.S. of skin of a mammal

Comments:

Vertical section of skin of a mammal shows the following structures:

1. The skin is composed two layers, an outer layer epidermis and an inner layer dermis.
2. The **epidermis** comprises four layers namely outer stratum corneum, next to it **stratum lucidum** then **stratum granulosum** and innermost layer is **stratum germinativum**.
3. Stratum corneum consists of horny cells and periodically moulted.
4. Stratum granulosum is made up of granular cells.
5. The dermis consists of dense areolar connective tissue, muscle fibres, blood vessels, nerves and glands.
6. The mammalian skin is characterized by the presence of hairs and glands.
7. The glands are of two types namely **sebaceous glands** and **sweat glands**.
8. The sebaceous glands are small glands of the simple branched alveolar type.
9. The sweat glands are coiled, tubular and much longer. Each gland opens on the surface through a long coil duct.
10. The main function of sweat glands is temperature regulation of body.

Functions of skin: i) protection of body ii) conservation of heat iii) excretory iv) secretory and v) sensory

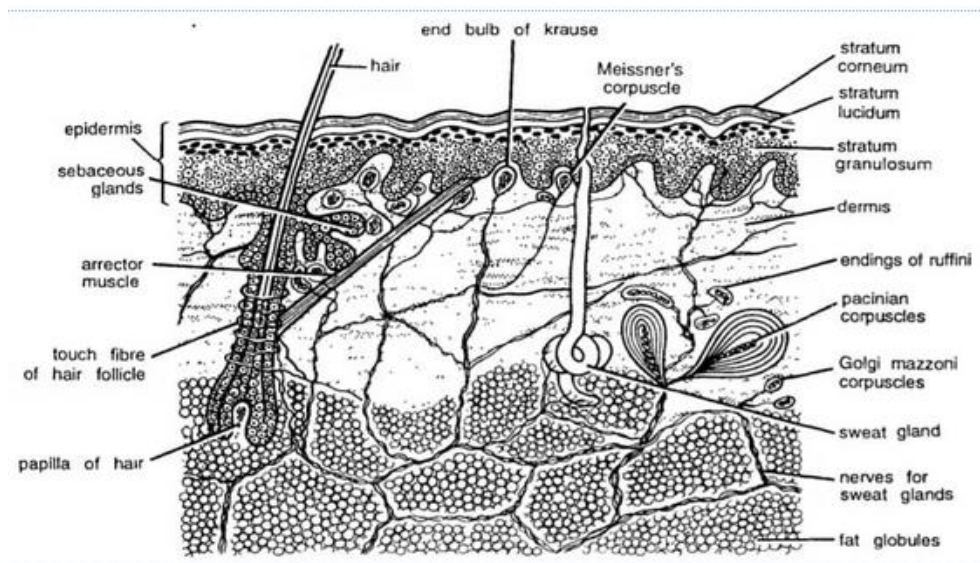


Fig.3.37 V.S. of skin of a mammal

38. T. S. of oesophagus of a mammal

Comments:

1. Outermost layer is composed of fibrous connective tissue and is known as fibrous layer.
2. The muscularis consists of three layers of muscle fibres, the outer and inner layers are composed of longitudinal muscle fibres and the middle layer is made up of circular muscle fibres.
3. The mucosa is composed of connective tissue containing blood vessels, nerves and lymph vessels.
4. The muscularis mucosa is also present and mainly composed of longitudinal muscle fibres and extends close to the stratified epithelium.
5. The mucosa is the innermost layer and forms 4-6 major folds.
6. It is formed of a stratified squamous epithelium.

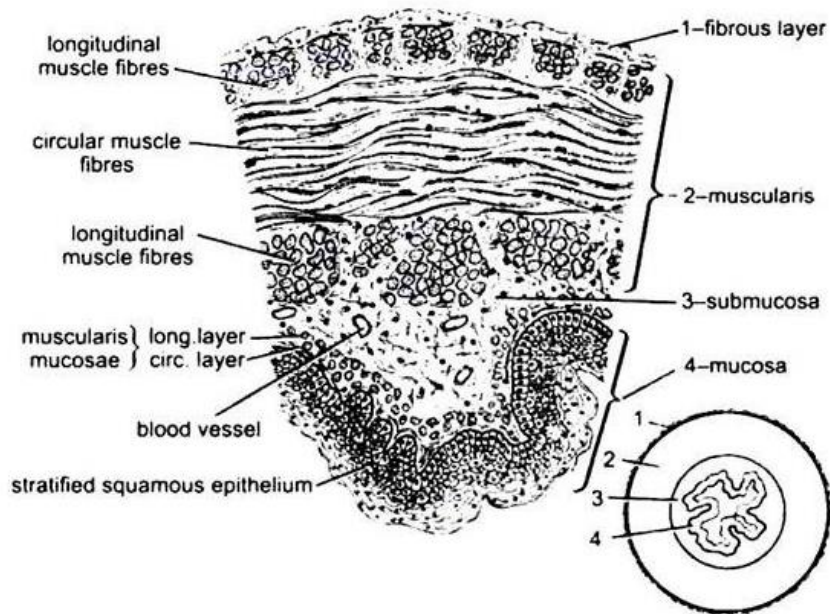


Fig.3.38 T.S. of oesophagus of a mammal

39. T.S. stomach of a mammal

Comments:

Transverse section of stomach of a mammal shows the following histological structure:

1. The serosa is the outermost layer which is composed of simple squamous epithelium.
2. The muscularis consists of two layers; the outer layer is composed of longitudinal muscle fibres, while the inner layer is composed of circular muscle fibres.
3. The muscle fibres in both the layers are arranged in bundles which are bound together by connective tissue.
4. The submucosa is made up of connective tissue containing blood vessels, nerves and lymph vessels.
5. Muscularis mucosae is a thin layer and its fibres are arranged in two layers.
6. The mucosa is the thickest layer. It consists of simple columnar epithelium and tubular or gastric glands.
7. The gastric glands composed of two types of cells namely peptic cells and oxyntic cells.
8. The peptic cells are found at the base of gastric glands.

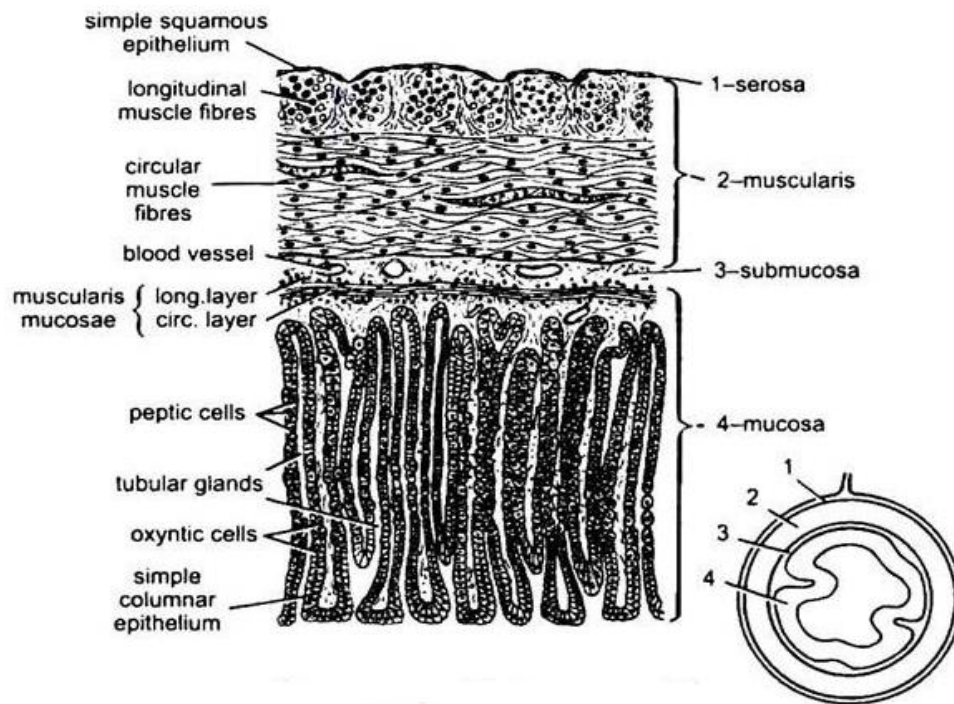


Fig.3.39 T.S. of stomach of a mammal

9. The oxyntic cells are found towards the luminal part of gastric glands. These are circular or oval, non-granulated and secrete HCL.

40. T. S. of duodenum of a mammal

Transverse section of duodenum of a mammal shows the following histological structure:

Comments:

1. Outermost layer is serosa which is usually consists of a simple squamous epithelium.
2. The muscularis consists of longitudinal muscle fibres to the outside and circular muscle fibres to the inside.
3. The submucosa consists of connective tissue holding blood vessels, nerves and lymphatic vessels.
4. The muscularis mucosa is thin and double layered consisting of outer layer of longitudinal fibres and inner layer of circular fibre.
5. The mucosa is thrown into numerous large and small finger- like fold called villi which are all covered by simple columnar epithlium with scattered goblet cells.

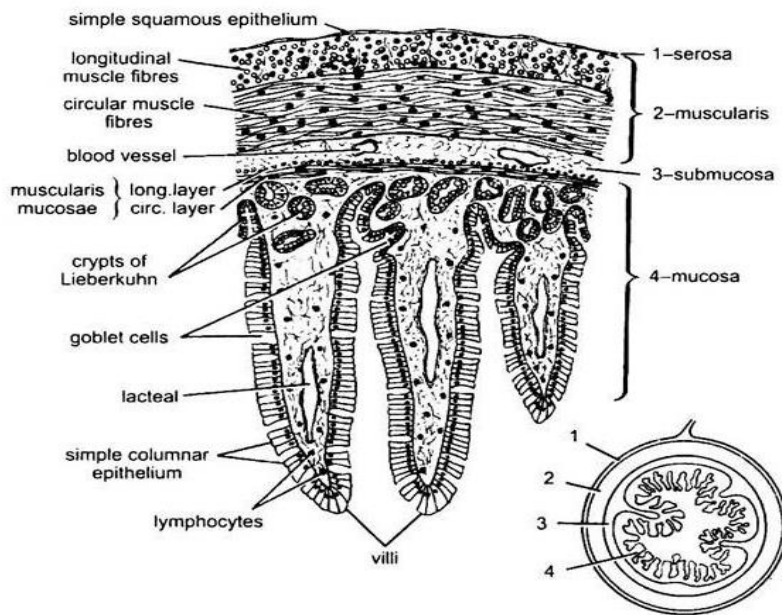


Fig.3.40 T.S of duodenum of a mammal

6. Each villus contains blood vessels, lymphocytes and a lacteal.
7. At the base between the villi are present crpts of Lieberkubn.
8. The crypts of Lieberkuhn lead into Bruner's glands.
9. The secreations of the crypts of Lieberkuhn and Bruner's glands form the intestinal juices.

41. T.S. of liver of a mammal

Comments:

Transverse section of liver of a mammal shows the following histological structure:

1. The liver is composed of polygonal lobules containing a central vein (intra-lobular vein) in the centre and portal canals at the corners.
2. Each portal canal consists of connective tissue strand and contains a branch of portal vein, hepatic artery, bile duct and lymph vessel.
3. The liver cells are polyhedral or rectangular and arranged in single celled long chains extending radially from the central vein to the periphery of the lobule.
4. Each liver cell has granular cytoplasm and a prominent nucleus.
5. The sinusoids are formed from branches of the hepatic portal veins and empty into central veins.
6. Several functions of liver are follows:
 - i) It produces bile which plays an important role in the digestion of food.

- ii) It stores the soluble products of digestion and metabolize them for assimilation.
- iii) Oxidation of sugar takes place in it
- iv) Toxic substances are detoxicated in the liver.

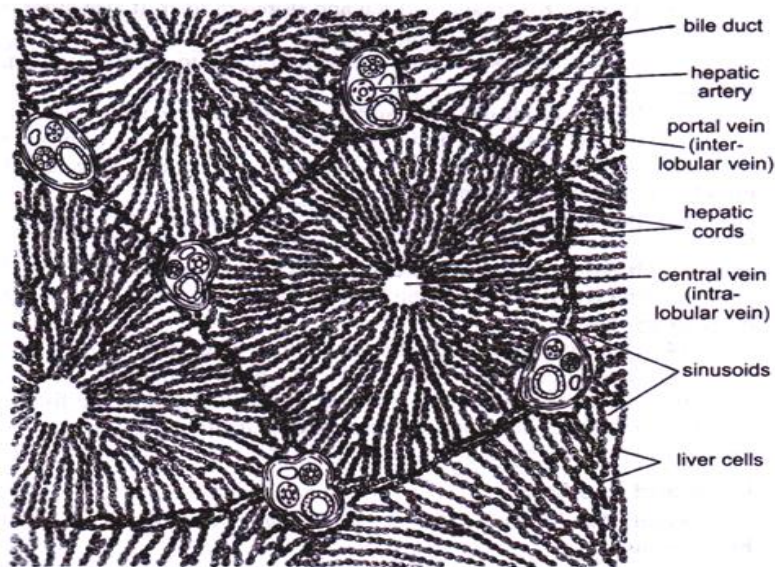


Fig.3.41 T.S of liver of a mammal

42. T. S. of pancreas of a mammal

Comments:

Transverse section of pancreas of a mammal shows the following histological structure.

1. The pancreas consists of consists of two portions namely, exocrine portion and **endocrine portion**.
2. The **exocrine portion** consists of a series of **lobules or acini**.
3. **The lobules or acini are bound together by loose connective tissue.**
4. Each lobule or acinus is made up of few pyramidal pancreatic cells having granular cytoplasm and prominent nuclei.
5. The exocrine portion produces pancreatic juice which contains trypsin, amylase and lipase enzymes.
6. The endocrine portion is composed of islets of Langerhans found between the acini.
7. The islets of Langerhans are compact masses of cells and secrete two hormones namely insulin and glucogon.

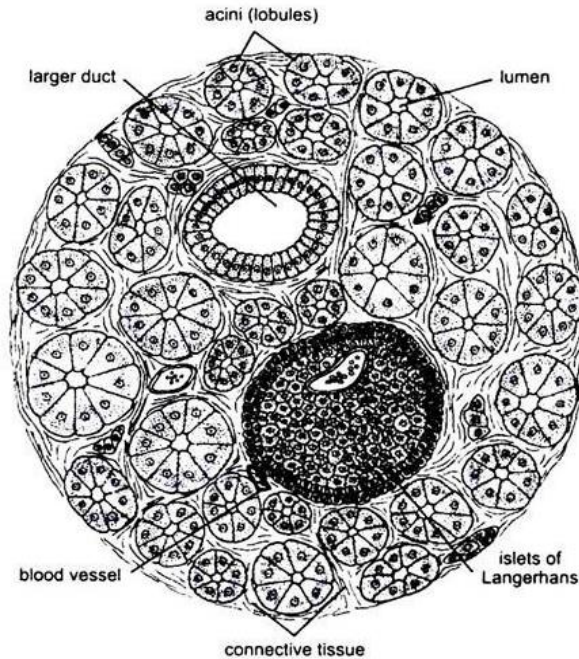


Fig.3.42 T. S. of pancreas of a mammal

8. The insulin is produced by the beta cells of islets of Langer hans.
9. Pancreas acts both as an exocrine as well as endocrine gland.

43. T.S of spleen of a mammal

Comments:

Transverse section of pancrease of a mammal shows the following histological structure.

1. The spleen is surrounded by a thin capsule made up of fibrous connective tissue and involuntary muscles.
2. The capsule arises branching trabeculae which penetrate into the tissue of the spleen.
3. The trabeculae contain fibrous connective tissue.
4. The spleen is composed of lymphatic tissue which is distinguished into white pulp and red pulp.
5. The white pulp consists of reticular fibres and form sheath around the arteries.
6. The red pulp contaions erythrocytes, capillaries and venous sinuses.
7. Macrophages or phagocytes are produced in the spleen which eats up foreign bodies and dead cells.
8. The spleen is very important organ of the body and serves the following functions:
 - i) Spleen produes erythrocytes and lymphocytes.

- ii) Eats foreign bodies, bacteria and dead cells.
- iii) Produces antibodies which prevent the entrance of bacteria.
- iv) It acts as a filtering organ of the blood.

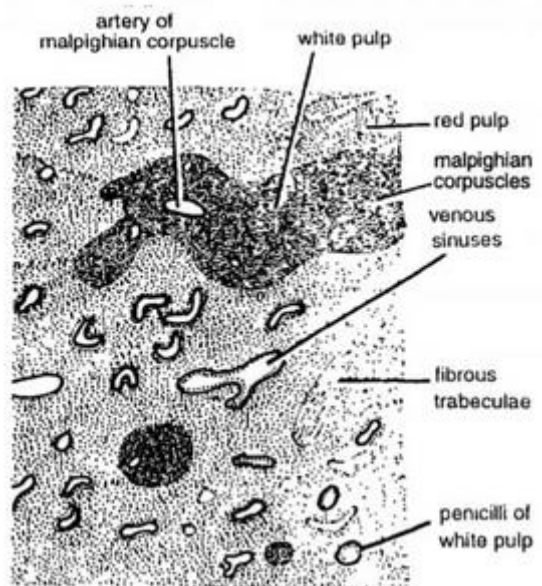


Fig.4.43 T. S. spleen of a mammal

44. T. S. of lung of a mammal

Comments:

1. Lung consists of numerous alveoli.
2. The alveoli communicate with one another by apertures in their walls.
3. Each alveolus is a network of capillary blood vessels in connection with pulmonary artery or vein of the lung.
4. Numerous alveoli form clusters which open in a alveolar duct.
5. Each bronchus as it enters the lungs, divides and sub- divides into finer and finer branches, the bronchioles.
6. The bronchioles are subdivided into respiratory bronchioles.
7. The respiratory bronchiole gives rise to several alveolar ducts which open into alveoli. Or air sac.
8. The alveoli richly supplied with blood vessels form the seat of respiration.

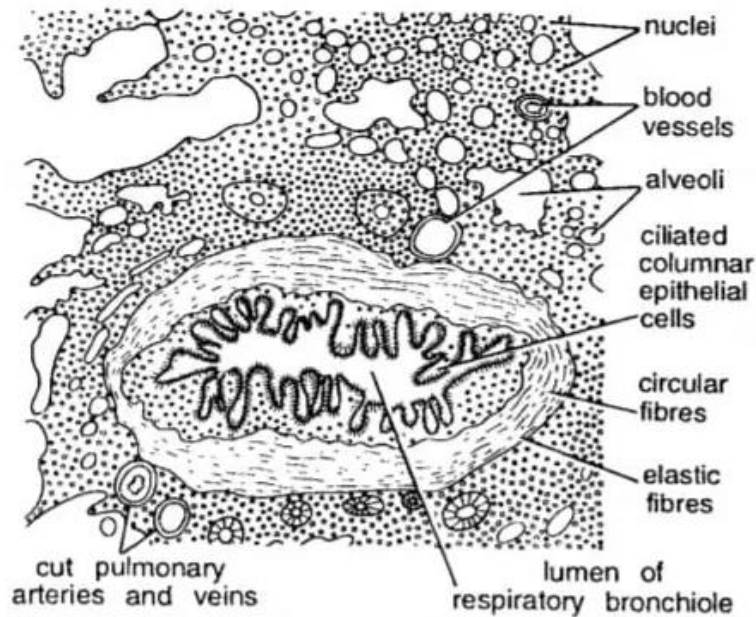


Fig.4.44 T.S of lung of mammal

45. T.S of testis of a mammal

Comments:

Transverse section of testis of a mammal shows the following structures:

1. Histologically each testis is composed of a mass of coiled seminiferous tubules.
2. The seminiferous tubules are separated from one another by intertubular tissue.
3. The intertubular tissue is formed of connective tissue which holds the tubules together and contains blood vessels and interstitial cells.
4. The interstitial cells secrete a hormone testosterone responsible for male secondary sexual characters.
5. The germinal epithelium gives rise to sperms which are seen in various stages of development in a seminiferous tubule and are as follows:
 - i) The **spermatogonia** lie the periphery of the tubule and appear closely packed together.
 - ii) The **spermatocytes** lie in just below spermatogonia and comprise primary and secondary spermatocytes.
 - iii) The **spermatids** aggregate in clusters below the spermatocytes.
 - iv) The **spermatozoa** lie in the cavity of the tubule, grouped in clusters and appear connected with **Sertoli cells**.

6. The groups of spermatocytes, spermatids and spermatozoa are separated from each other by **Sertoli cells**.

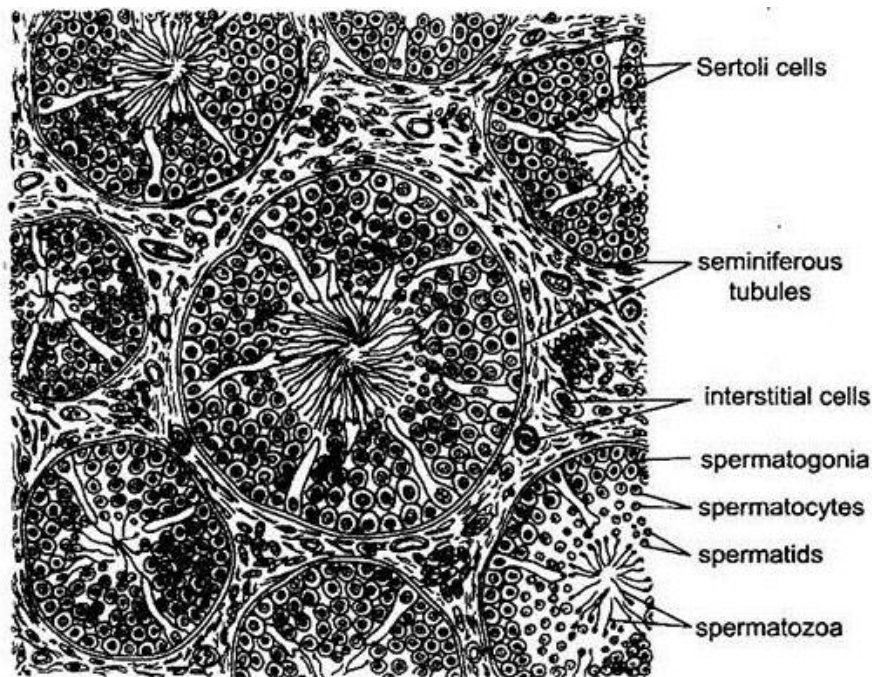


Fig.3.45 T.S of a testis of a mammal

46. T.S of ovary of a mammal

Comments:

Transverse section of ovary of a mammal shows the following structures:

1. The ovary is lined by germinal epithelium which is bounded by the connective tissue, the tunica albuginea.
2. It consists of mass of connective tissue and spindle- shaped cells, the two together forming the stroma.
3. The primary follicles arise from ingrowth of the germinal epithelium into the stroma.
4. The follicle and ovum slowly move deeper into the stroma and become larger.
5. A mature follicle is made up of three layers, an outer theca externa , middle layer theca interna and the inner layer membrane granulosa.
6. After discharging of ovum, the follicle cells undergo proliferation and change in structure to form corpus luteum which secretes hormone, progesterone.

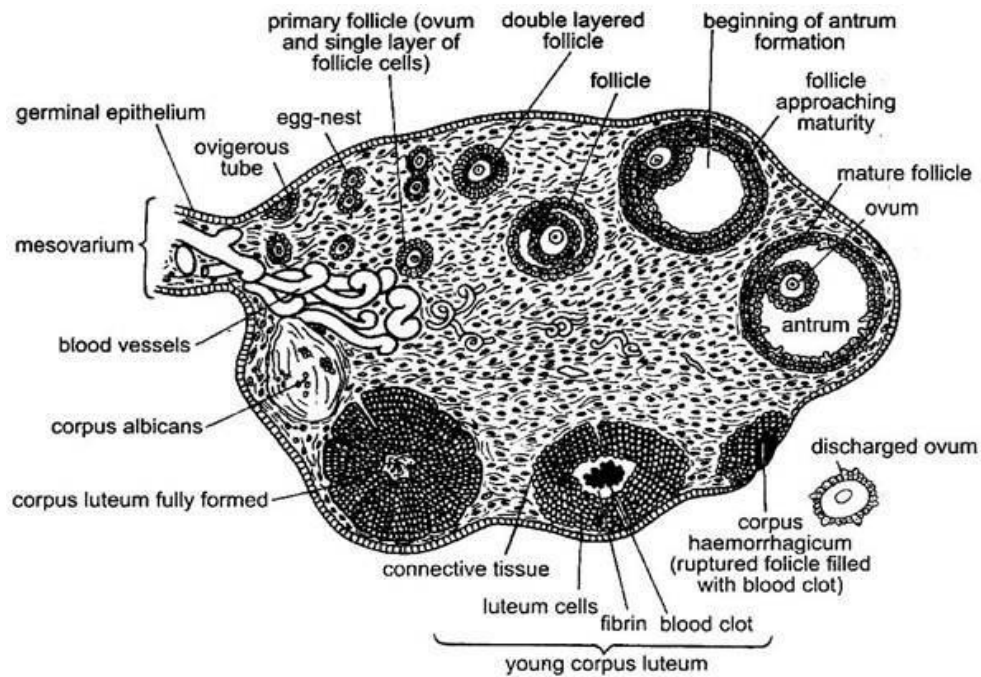


Fig.3.46 T.S. of ovary of a mammal

47. V.S of thyroid gland of a mammal

Comments:

Vertical section of thyroid gland of a mammal shows the following structure:

1. The thyroid gland of mammal lies on the ventro-lateral surface of the larynx and the posterior portion of trachea.
2. It consists usually of two lobes connected by an isthmus.
3. Histologically it consists of an outer fibrous capsule and a number of rounded, oval or oblong thyroid follicle separated by inter-follicular tissue.
4. The fibrous capsule is composed of fibrous connective tissue containing large blood vessels and surrounds the thyroid gland.
5. Thyroid gland secretes thyroxin hormone.

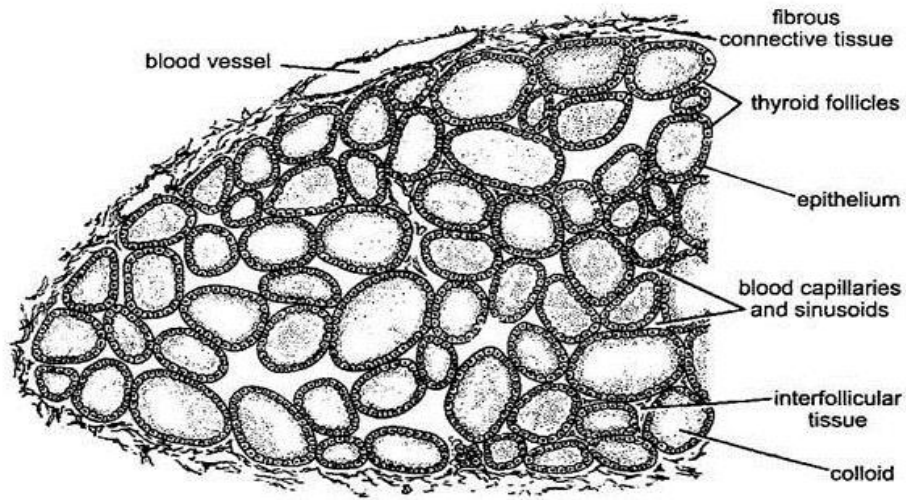


Fig. 3.47 V.S. of thyroid gland of a mammal

6. Thyroxin controls the entire metabolism of animals.
7. Thyroid is an endocrine gland.

48. T.S of adrenal gland of a mammal

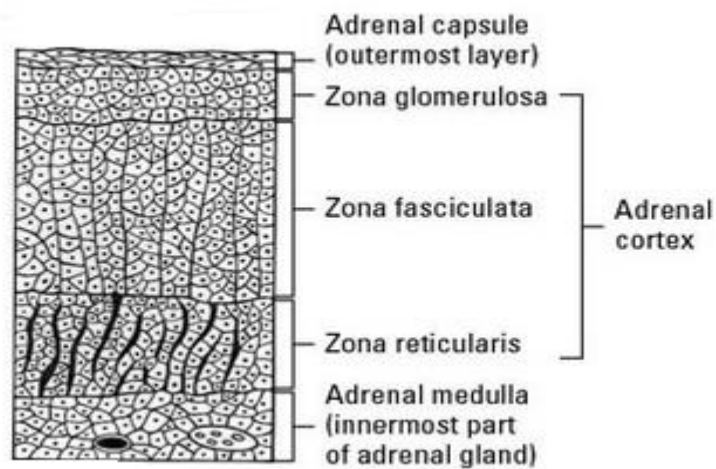


Fig.3.48 T.S. of adrenal gland of a mammal

Comments:

1. The adrenal gland is composed of two distinct parts, i. e., outer cortex and inner mrdulla surrounded by the capsule.
2. The capsule is composed of fibrous connective tissue containing blood vessels and nerves.

3. The cortex produces a hormone known as cortin. It regulates the general metabolism, controls the sodium chloride content of blood and also promotes the breaking down of the tissue proteins to amino acids.
4. The medulla is the central portion, consists of network or cords of polygonal cells and clusters of chromaffin cells, networks of cells contain numerous blood capillaries, sinusoids and in the centre a central vein.
5. Medulla secretes a hormone known as adrenalin. It is responsible for maintaining the blood pressure, dilation of vessels and muscles, increasing the general metabolism rate and also for hastening the coagulation of blood.
6. The adrenal glands are endocrine glands and lie just above the kidney attached to it by a fold of mesentery.

3.4 SUMMARY

The Animals are placed in the kingdom Animalia, which is further divide into phylum non-chordate and phylum chordates. The main characteristic of Phylum chordate is the presence of dorsal tubular nerve cord. Phylum chrodota divided into two groups Acrania (protochrodote) and Craniata (vertebrata). The group protochrodota includes the lowly organized members of phylum chrodota. The organisms which are included in group vertebrata show the presence of vertebral column. There are various methods to study the members of these groups e.g specimen study, permanent slides etc. This unit includes the permanent slides of members of protochrodotes and chrodota. The permanent slides are used to study T. S. of *Amphioxus* through oral hood, T. S of *Amphioxus* through anterior-pharynx, T.S *Amphioxus* through posterior- pharynx showing testes and liver diverticulum, T.S. *Amphioxus* through posterior-pharynx showing ovaries and liver- diverticulum, T.S. of *Amphioxus* through atriopore, T.S. of *Amphioxus* through anal region, T.S. of *Amphioxus* through caudal region, Velum of *Amphioxus*(Whole mount), Oral hood of *Amphioxus* (Whole mount), T.S. of proboscis of *Balanoglossus*, T.S collar of *Balanoglossus* , T.S. of branchiogenital region of *Balanoglossus* , T.S. of post-hepatic intestine of *Balanoglossus*.

Chordates: Slides of fishes- T.S. *Scoliodon* through the olfactory region, T.S. *Scoliodon* through branchial region, T.S. *Scoliodon* through stomach and liver, T.S. *Scoliodon* through intestine, T.S. *Scoliodon* through the base of pelvic fin of male and female, Ampulla of Lorenzini, Placoid scale of *Scoliodon*, cycloid scale (Whole mount), Ctenoid scale (Whole mount).

Slides of Amphibia- V. S. of skin of frog, T.S. esophagus of frog, T.S. stomach of a Frog, T.S. intestine of a frog, T.S. liver of a frog, T.S. of rectum of frog, T.S. of liver of frog, T.S. of pancreas of frog, T.S. spleen of frog, T.S. of lung of frog, T.S. of kidney of frog, T.S. of ovary of frog, T. S. of spinal cord of frog, V.S. of skin of a mammal, T.S. esophagus of a mammal, T.S. of stomach of a mammal, T.S. duodenum of a mammal, T.S. liver of a mammal, T.S. pancreas of a mammal T.S. spleen of a mammal, T.S. lung of a mammal, T.S. of testis of a mammal, T.S. of ovary of a mammal, V.S. of thyroid gland of a mammal, T.S. of adrenal gland of a mammal.

3.5 TERMINAL QUESTIONS AND ANSWERS

1. Multiple Choice Questions:

1. Digestion of protein is completed in

- A. Stomach
- B. Ilem
- C. Duodenum
- D. Duodenum and ileum

2. Enzyme rennin is secreted by

- A. Stomach
- B. Liver
- C. Kidney
- D. Pancreas

3. **The membrane investing the ovum just outside the membrana granulosa is**

- A. Theca interna
- B. Discus proligerus
- C. Zona pellucida
- D. Vitelline membrane

4. Layer of cells immediately surrounding the ovum but outside the zona pellucida is called as

- A. Germinal epithelium
- B. Corona radiata
- C. Theca interna
- D. Membrana granulosa

5. The seminiferous tubules of the testis are lined by the germinal epithelium consisting of

- A. Spermatids
- B. Cells of Sertoli
- C. Spermatogonium
- D. Spermatocytes

Answers: 1. C, 2. A, 3. A, 4. B, 5. B

3. Long Answer Question:

1. Explain oral hood of *Amphioxus*.
2. Describe transverse section of pancreas of a mammal with well label diagram.
3. Describe Vertical section of thyroid gland of a mammal.

REFERENCES

1. A manual of Practical Zoology Chordate by P.S. Verma.
2. Kotpal, R.L 2012 Vertbrate, Rastogi publication Merruth.
3. Some figure are adopted from www.notesonzoology.com
4. <https://www.faunafondness.com/mammal-slides/>
5. <https://www.faunafondness.com/bird-slides-pigeon/>

Unit 4: Study of the museum specimens of Protochordata and of the different classes of vertebrates

4.1 Objective

4.2 Introduction

4.3 Study of Muséum spécimens

4.3.1 Protochordata

4.3.2 Chordata

4.4 Summary

4.5 Terminal Questions and Answers

Study of the museum specimens of Protochordata and of the different classes of vertebrates : The last major group of the animal kingdom is Phylum Chordata. It is derived from two Greek words, “chorde” meaning a string or chord (referring to notochord) and “ata” means bearing. The chord means stiff, rod-like structure along the back i.e. the chorda dorsalis or notochord (Gr., noton: back, chorda: string). All the chordates possess three outstanding unique characteristics at some stage in their life history, i.e., a dorsal, hollow or tubular nerve cord, longitudinal supporting stiff but flexible notochord and a series of pharyngeal gill-slits. A naked skin is hardly seen in chordates. (Some sort of structures like scales, feathers and hair are usually present).

Protochordates as you will recall has three basic chordate characters and are considered most primitive chordates. Protochordates (Gr., protos: first; chorde: chord) are all marine, small, primitive or lower chordates, lacking a head, a skull or cranium, a vertebral column and jaws. This group is divided into 2 subphyla: (1) Urochordata and (2) Cephalochordata mainly on the basis of presence of notochord.

4.1 OBJECTIVE :

Study of the museum specimens of Protochordata and of the different classes of vertebrates

4.2 INTRODUCTION:

Phylum Chordata has been divided into two groups: Protochordates and Vertebrata. The Protochordates is derived from words, protos- first, chorda- cord. They are great phylogenetic significance. It shows first sign of vertebrate formation. This group includes the lowly-organized members of phylum chordata. Protochordates is classify into three kinds of sub phyla based on the type of notochord they possess.i) Hemichordata ii) Urochordata iii) Cephalochordata.

GENERAL DIRECTIONS

1. While coming to the laboratory, to attend the practical class, check that you possess the **practical note book, guide book for practical, pencils, eraser, sharpener, scale, brush** and complete set of **dissecting instruments**.
2. Instruments should be sharp and according to required conditions.
3. Come well prepared with the work you are supposed to do in the practical class.
4. Always sit on the proper place which is allotted to you in the laboratory.
5. Keep your instruments, practical note book and seat well arranged and tidy.

6. Observe silence and follow the instructions given by your teacher.
7. Do not consult your class fellows for any ell. Always remove your difficulties from your archers.
8. Never encourage the habit of lending her to or from your classmate.
9. Never rub your pencil on the top of the table or on the floor, always use the sharpener or a sand paper.
10. Before leaving the laboratory arrange all reagent bottles in the rack and keep other things at proper place.

PRACTICAL NOTE-BOOK

1. Practical note book should be neat, clean and up-to-date.
2. Always draw the diagrams on the right side of practical note book and name of museum specimens or slides below them, which is called as foot heading. Put date on the left hand corner of the page of note book.
3. Write down the comments on left side on line papers.
4. Diagrams should be correctly drawn and well-papers.
5. Try to complete diagrams and comments in the laboratory on same day. Never postpone today's work for tomorrow.

STUDY OF MUSEUM SPECIMENS

1. First study the characteristics of the specimen to be drawn.
2. Try to find out those characters in the specimen which are mentioned in your practical book.
3. Draw only that view which exhibits maximum details such as dorsal view or ventral view or lateral view.
4. Diagrams should be drawn from the original specimen. Take the help of practical book for comparing and labeling the various parts of specimen.
5. Draw proportionate diagram while considering the length and width of the animal body.
6. Draw only line diagrams. Try to avoid shedding as much as possible.
7. Always write down the classification of the entire specimen.

4.3 STUDY OF MUSÉUM SPÉCIMENS (*PROTOCHORDATES*)

Study of the museum

1. Herdmania

Classification

Phylum	-	Chordata
Group	-	Protochordata (Acrania)
Subphylum	-	Urochordata (Tunicata)
Class	-	Ascidacea
Subclass	-	Pleurogona
Order	-	Stolldobbranchla
Family	-	Pyuridae
Genus	-	<i>Herdmania</i>
Species	-	<i>Pallida</i>

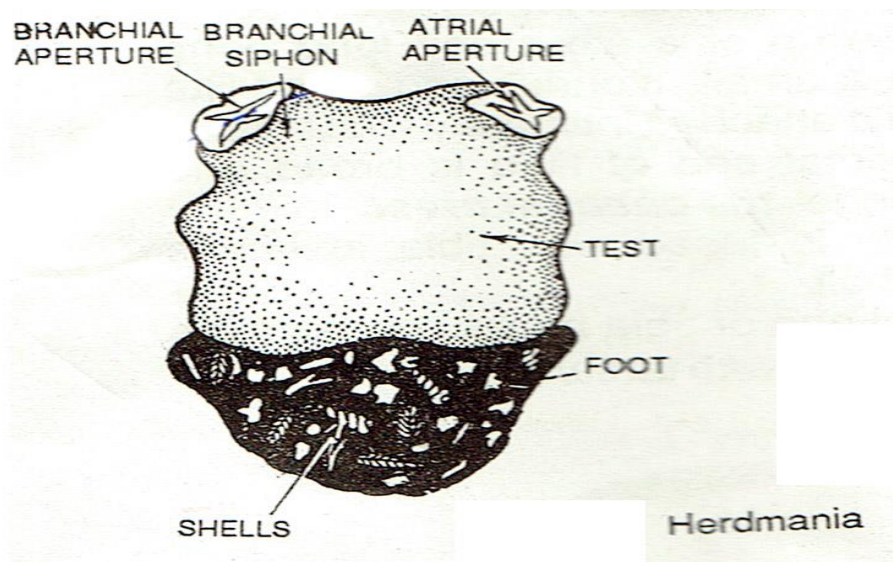


Fig 4.1 Herdmania

1. It is marine, unsegmented and solitary animal.
2. The body is some what square and enclosed in a soft transparent tunic-‘the **test**’.
3. The adults are without tail.
4. The individuals remain attached to substratum through a well marked foot.

5. It's alimentary canal is 'U' – shaped.
6. The mouth and cloaca open into definite chambers-the **branchial and atrial sipons**.
7. Pharynx is perforated with stigmata in youngs and adults both.
8. The **vascular system** is of open type.
9. Nervous system is represented by single ganglion in adults.
10. A **dorsal tubular nerve cord** is present in embryonic stages.
11. Skull, jaws, exo-and endoskeleton are ab-sent.
12. **Notochord is present only in embryonic stage and is restriced to tail.**
13. The excretion is through unpaired neural gland, situated above the nerve ganglion.

2. AMPHIOXUS

Classification

Phylum	-	Chordata
Subphylum	-	Cephalochordata
		(cephalic-head
		(chordata-notochord)
Genus	-	<i>Branchiostoma</i>
Species	-	<i>Lanceolatum</i>

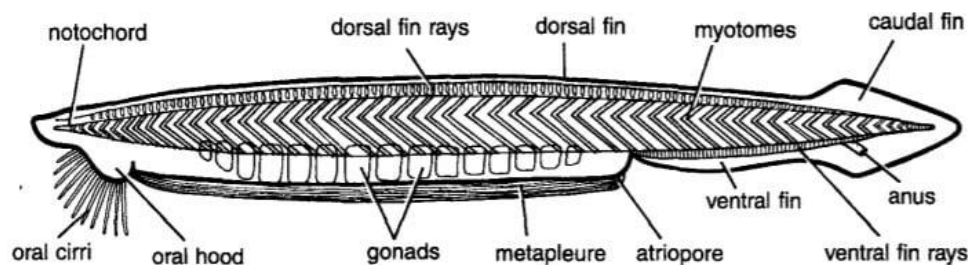


Fig 4.2 Amphioxus

1. They are burrowing, marine and fish like. They are commonly called *Lancelet*.
2. Body is laterally compressed having a distinct tail and a caudal fin.
3. A dorsal fin is present all along the back and the ventral fin is present in front of caudal fin. Dorsal ventral and caudal fins are continuous. Two lateral fins or **metapleural folds** are also present.
4. Body is divisible into trunk and tail, head is absent.

5. Skull, jaws and exoskeleton are absent.
6. Mouth is surrounded by a ring-the *oral-hood* made of about *18-20 oral cirri*.
7. Opening between buccal cavity and pharynx is guarded by a ring- *the velum* having *8 tentacles*. Pharynx is surrounded by atrium and is perforated by *oblique gill slits* (stigmata)
8. Anus asymmetrically placed on right side.
9. **Dorsal tubular nerve chord and noto-chord are present throughout life.**
Notochord extends into head region also.
10. Sexes are separate but no sexual dimorphism is visible.

3.PETROMYZON

Classification

Phylum	-	Chordata
Subphylum	-	Agnatha
Class	-	Cyclostomata
Order	-	Petromyzontiformes
Genus	-	<i>Petromyzon</i>
Species	-	<i>Marinus</i>

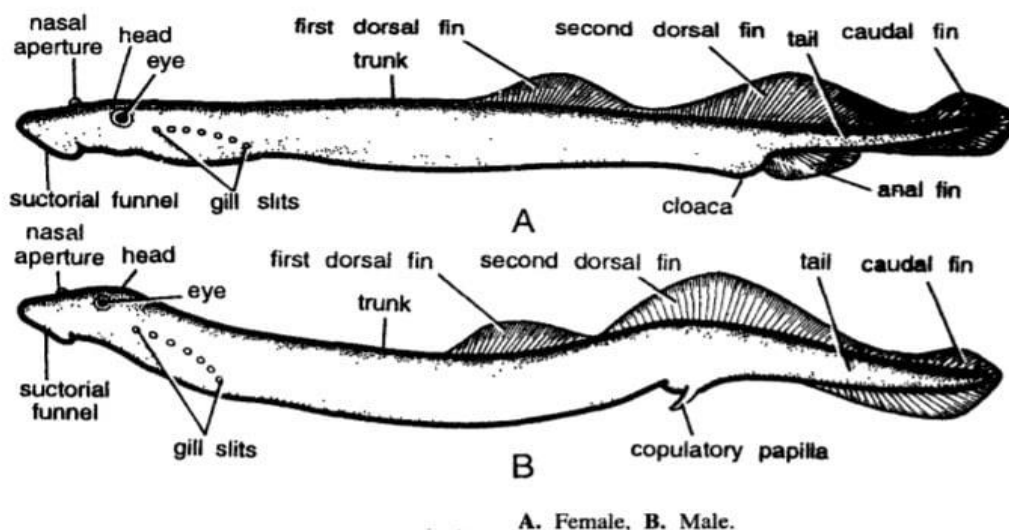


Fig 4.3 Petromyzon

1. It is both marine and fresh water and lives as *ectoparasite on aquatic vertebrates* and commonly called '*lamprey*'
2. Elongated eel-like body is divisible into cylindrical head, trunk, and laterally compressed tail.
3. *Exoskeleton (scales) is absent* but skin is covered with thick, mucous.
4. Paired fins absent but unpaired or median fins are present. Two membranous median dorsal fins near posterior end and a caudal fin around tail are present and supported by fin rays.
5. In female *an anal fin* is also present behind anus.
6. *Mouth is funnel like*, bears adhesive papillae, hooks and radiating rows of horny teeth and is used for sucking. Protrusible tongue is rasping in nature and *jaws are absent*.
7. Pharynx is perforated with *7 pairs of round gill slits*.
8. Head bears one pair of eyes laterally.
9. Single nostril is present mid dorsally on head but internal nares is absent.
- 10.** Cloaca present on ventral side at the junction of trunk and tail.

4.MYXINE

Classification

Phylum	-	Chordata
Subphylum	-	Agnatha
Class	-	Cyclostomata
Order	-	Myxiniiformes
Genus	-	Myxine
Species	-	glutinosus

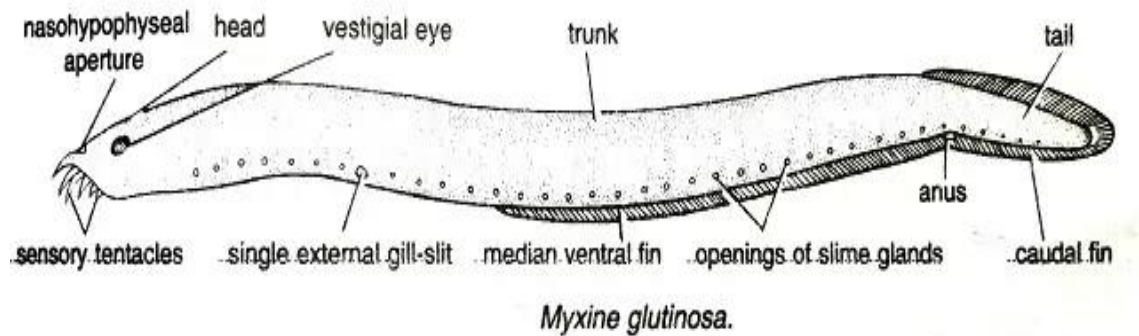


Fig 4.4*Myxine*

1. It is marine and quasiparasite and is found burried in mud and sand.
2. It is commonly called 'hag-fish' or '*slime-eel*'
3. Elongated eal like body is differentiated into head, trunk and tail.
4. ***Exoskeleton is absent*** but skin is covered with thick mucous.
5. Double rows of mucous glands are present all along the body.
6. ***Paired fins absent***, but median, but median fins are present. One caudal find around the tail and one ventral fin are also present.
7. ***Jaws are absent*** but suctorial terminal mouth is guarded by soft and wrinkled lips and is surrounded by **8 tentacles**.
8. The single median and terminal nasal ***aperature (nostrll)*** lies close to the mouth and communicates with it.
9. ***Eyes are greatly reduced and covered*** with a fold of skin.
10. ***Pharynx is perforated with palred round gill slits which open externally through one pair of common extrnal gil slits.***
11. It is hermaphrodite, ***protandrous*** has ***single ovotestis***.

5.AMMOCOETAE LARVA

Classification

Phylum	-	Chordata
Group	-	Vertebarta (Cranita)
Class	-	Cyclostomata
Order	-	Petromyzonifformes
Genus	-	<i>Ammocoete larva of petromyzon</i>

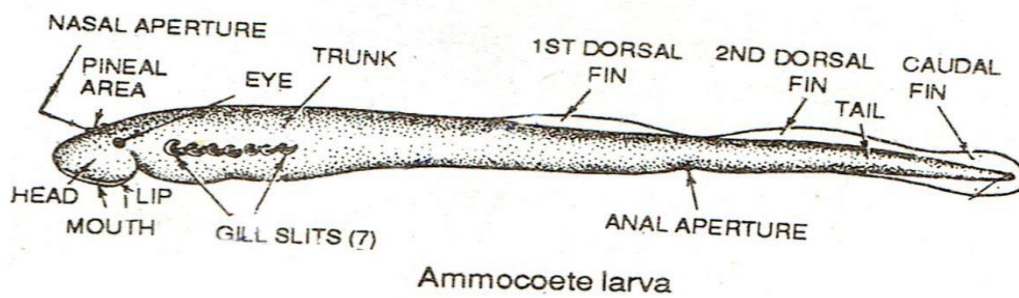


Fig 4.4 Ammocoete larva

1. *It is the free swimming lava of petromyzon* (lamprey) and lives in freshwater and mud.
2. It feeds on plankton and is macro- *phagus*.
3. Elongated eel-like body is **without -exoskeleton** (scales) **but is covered by thick mucous**.
4. **Paired fins abáent but median fins, are present.** There are *two dorsal fins and a caudal fins* around tail.
5. *Mouth is not funnel like and buccal cavity is without teeth, hooks and papillae.*
6. *Jaws are- absent but - mouth is guarded by dorsal and ventral lips.*
7. Eyes are completely hidden by skin (subcutaneous).
8. On either side, behind head, **are present seven gill slits** protrusible tongue.
9. *The external and Infernal, nasal apertures, and pineal organ are absent.*
10. Pharynx has endostyle.
11. Anal aperature is present on ventral side at the junction of trunk and tail
12. *Metamorphoses into adult when it migrates Into sea catad-romous).*
Metamorphosis takes 3 Years.

1: ft iscommo,cced.: "shik" and A

4.3.2 CHORDATA

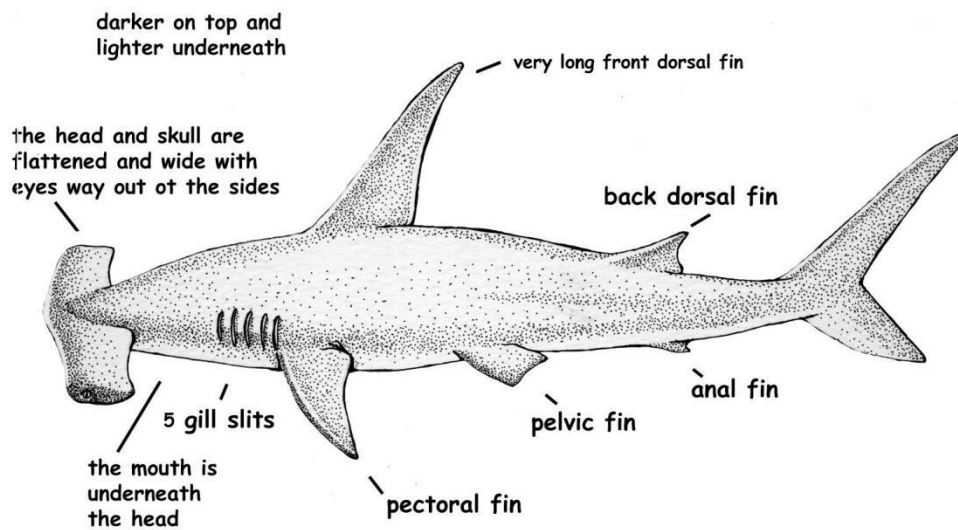
SPHYRNA

CLASSIFICATION

Phylum	-	Chordata
Super class	-	Pisces
Class	-	Chondrichthyes (Elasmobranchii)
Order	-	Pleurotremata
Genus	-	Sphyrna
Species	-	zygaena

Smooth Hammerhead Shark

Sphyrna zygaena



www.exploringnature.org

©Sheri Amsel

Fig 4.5 Sphyrna

1. It is marine and found in tropical **and** subtropical seas and is commonly called ***“hammer headed shark”***.
2. ***Exoskeleton is made up of placoid scales.***
3. Body bears median and paired fins.
4. Two ***dorsal fins, one anal fin and one caudal fin*** around ***heterocercal tail*** are present.
5. A pair of ***pectoral fins*** are present ventrolaterally.
6. Cranium and jaws are well developed.
7. ***Head is produced into blunt lateral lobes and eyes are situated at the tip of each lateral lobe.***
8. Crescentic mouth is ventral.
9. Spiracles are absent.
10. Pharynx is perforated by ***5 pairs of lateral gill slits.***
11. The nerve cord is dorsal and tubular and modified into brain at its anterior end and notochord is modified into cartilaginous vertebral column in adult.
12. ***Males have paired claspers at*** the base of pelvic fins.
13. It is ***viviparous.***

RAJA OR RAIA

CLASSIFICATION

Phylum	-	Chordata
Group	-	Vertebrata (Craniata)
Subphylum	-	Gnathostomata
Super class	-	Pisces
Class	-	Chondrichthyes (Elasmobranchii)
Subclass	-	Selachii
Order	-	Hypotremata
Genus	-	Raia or Raja
Species	-	mammillidens

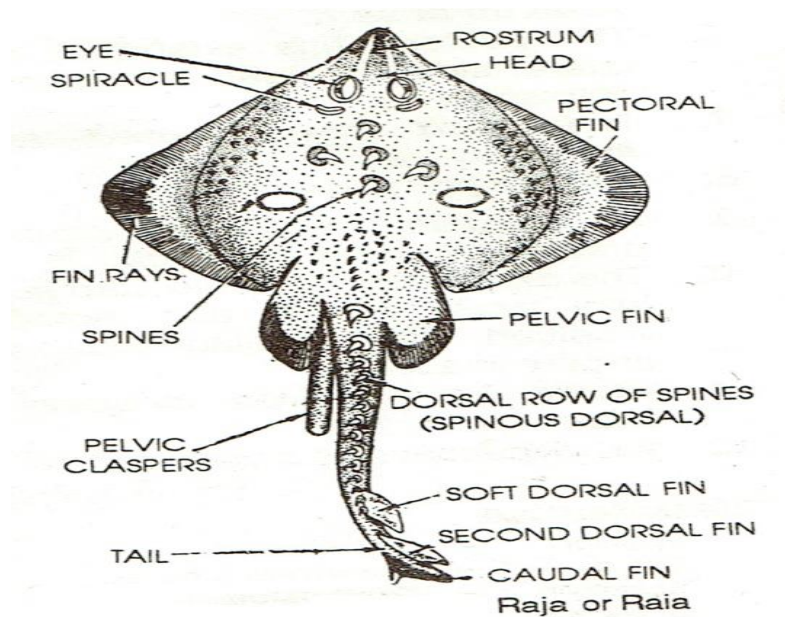


Fig 4.6 Raia or Raja

1. Commonly called *skate* and is found in all temperate seas.
2. It is a bottom feeder carivorous fish feeding on crustaceans and small fishes.
3. Body is dorsoventrally flattened and is divided into a **rhomboid disc** (head + trunk and pectoral fins) and a **slender tail**.
4. The rhombic disc is about 2 metre wide and bears **5 denticles** in the middle and 3 rows of spines near the joint of trunk and pectoral fins and tail and pelvic fins on either side.
5. The head bears paired eyes and spiracles.
6. The median and paired fins are present. The median fins are 2 dorsal and a caudal. **The anal fin being abset.**
7. The single lobed caudal fin is reduced.
8. The two dorsal fins are situated near the tip of tail.
9. Ventral gill-slits are 5 pairs and ventral mouth is armed with rasping teeth.
- 10. Al along the back are present rows of denticles.**
11. Males have paired claspers and exoskeleton is of placoid scales.
12. It is **oviparous**. The **eggs are laid enclosed in egg capsules having 4 horns**.
13. The dorsal tubular nerve cord is modified into brain in front and notochord is modified into cartilagenous vertebral column in adults.

TRYGON OR DASYATIS

CLASSIFICATION

Phylum	-	Chordata
Super class	-	Pisces
Class	-	Chondrichthyes (Elasmobranchii)
Subclass	-	Selachii
Order	-	Hypotremata
Genus	-	Trygon o r Dasyatis
Species	-	zygaena

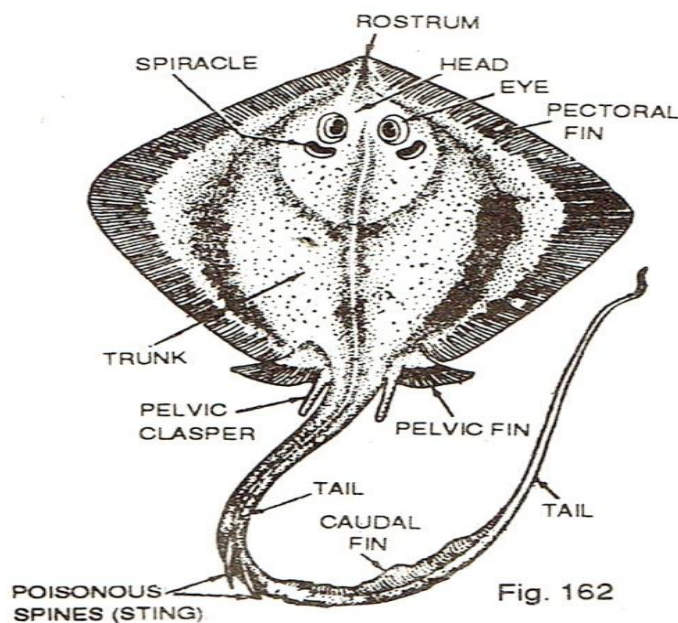


Fig 4.7 Trygon o r Dasyatis

1. It is marine and commonly called 'whlp ray' or 'sting ray'.
2. Rhomboidal disc like body is dorsoventrally compressed.
3. Exoskeleton is made up of placoid scales.
4. Paired and median fins are present.
5. Pectoral fins are fused with lateral sides of head and trunk and usually extend of head and trunk and usualy extend upto tip of snout.
6. Dorsal fin is modified into backward directed posonous spines, which are present in the middle of tail on mid dorsal line.
7. Mouth is ventral and anal fin is absent.

8. Males have paired claspers at the base of pelvic fins.
9. Slender, long and *whip like tail bears terminal single lobed caudal fin.*
10. Pharynx is perforated with *5 pairs of lateral gill slits.*
11. Spiracles are present on the dorsal surface behind the eyes.
12. Cranium and jaws are well developed and well defined.
13. The nerve cord is dorsal and tubular and modified into brain and notochord is modified into cartilagenous vertebral column in adult.

TORPEDO (ASTRAPE)

CLASSIFICATION

Phylum	-	Chordata
Super class	-	Pisces
Class	-	Chondrichthyes (Elasmobranchii)
Subclass	-	Selachii
Order	-	Hypotremata
Genus	-	<i>Astrape or Torpedo</i>

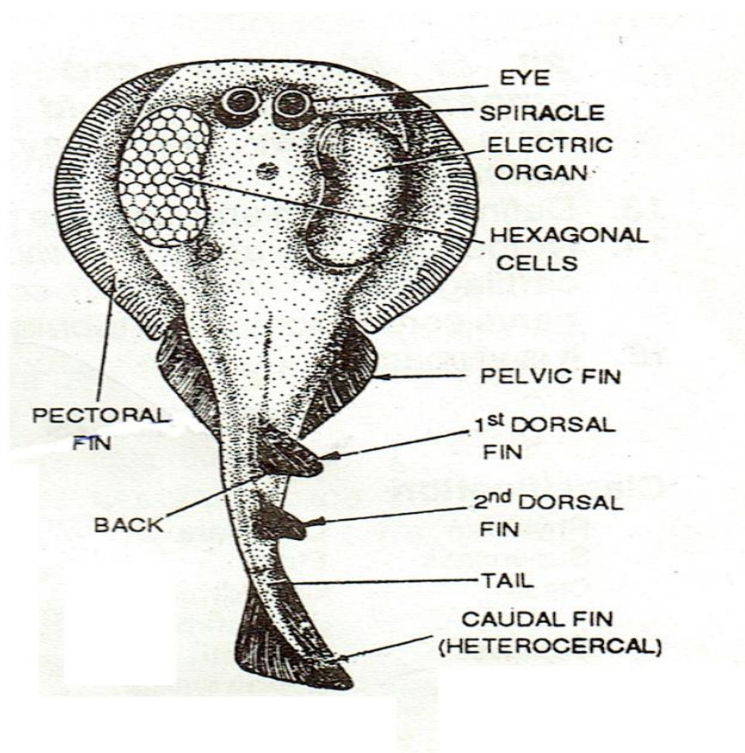


Fig 4.8 Astrape or Torpedo

1. It is marine and is commonly known as '*electric ray*'.
2. Body is dorsoventrally compressed and mouth is ventral.

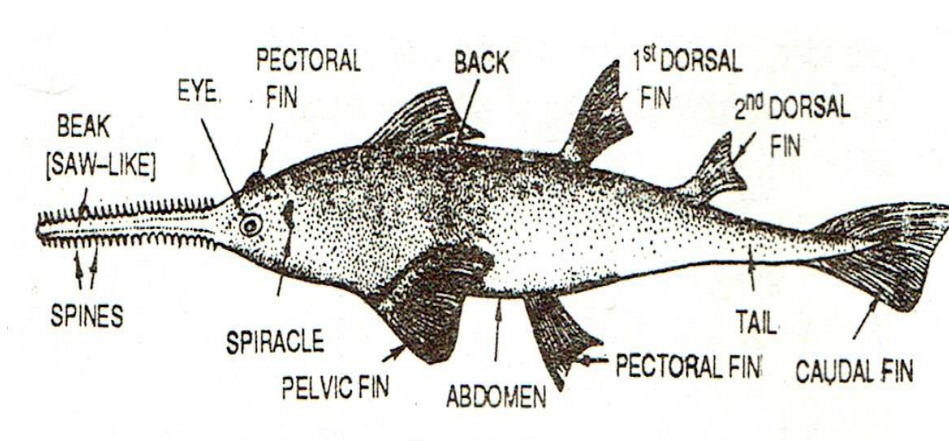
3. *Exoskeleton* is made up of placoid scales.
4. Head broad and almost circular and tail gradually tapering. Median and paired fins are present.
5. Median and paired fins are present.
6. Pectoral fins confluent with lateral sides of body.
7. ***Males have paired claspers at the base of pelvic fins.***
8. Two ***dorsal fins*** situated in the middle of the tail but ***anal fins*** are absent.
9. ***Heterocercal tail*** bears single lobed ***caudal fin***.
10. Five pairs of external gill slits are present on ventral side.
11. Two spiracles are present just behind the eyes on dorsal side.
12. Large electric organ made up of hexagonal cells is present on either side below the eyes. It produces electric discharge of 20 to 50 volts and of several amperes which would not only stun the prey but may even kill them.
13. Definite cranium and jaws are present.
14. Notochord in adult is modified into cartilagenous vertebral column and nerve cord is dorsal and tubular.
15. It is viviparous.

PRISTIS (SAW FISH)

CLASSIFICATION

Phylum	-	Chordata
Super class	-	Pisces
Class	-	Chondrichthyes (Elasmobranchii)
Subclass	-	Selachii
Order	-	Hypotremata
Genus	-	Pristis
Species	-	cuspidatus

Fig 4.9 *Pristis*



1. It
is marine
and

commonly known as 'saw fish'.

2. Elongated body is not dorsoventrally flattened like other skates and rays.
3. *Exoskeleton is made up of placoid scales.*
4. *Head is produced into a long beak-like lateral denticles or serrations to work as saw. It is used for offence, defence and food capture.*
5. Median and paired fins are present.
6. Pectoral fins are small and are present on either side behind the head.
7. Males have paired claspers at the base of pelvic fins.
8. Two dorsal fins and one anal fin present. First dorsal fin is just opposite to pelvic fin.
9. Heterocercal tail bears single lobed caudal fin.
10. It is viviparous.

CHIMAERA

(Monster fish or rat fish)

CLASSIFICATION

Phylum	-	Chordata
Super class	-	Pisces
Class	-	Holocephalii
Genus	-	Chimaera
Species	-	monstrosa

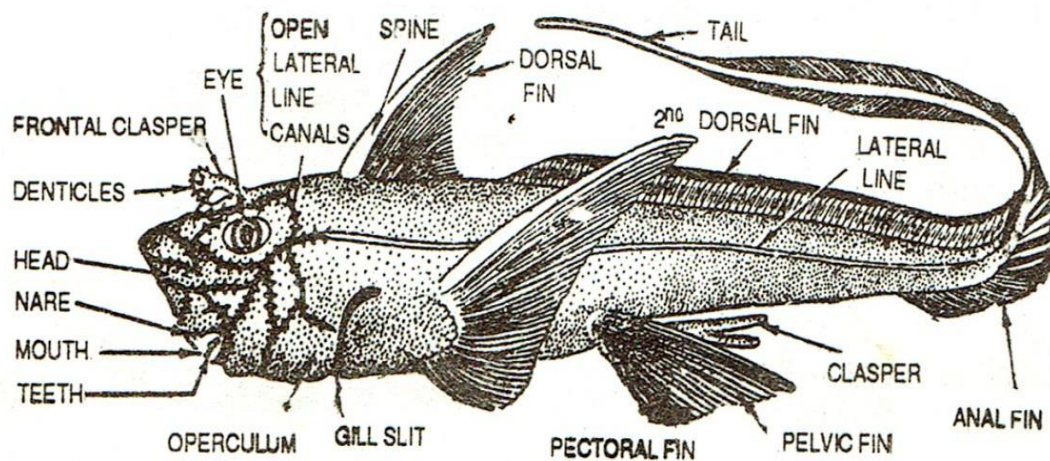


Fig 4.10 Chimaera

1. It is marine and commonly known as '*rat monster fish, elephant fish or king of herrings.*'
2. ***Exoskeleton is absent in adults.***
3. Median and paired fins present.
4. ***Two large dorsal fins and one small anal fin*** are present opposite to dorsal fin.
5. Long and whip like ***heterocercal tail*** surrounded by a ***diphycercalcaudal fin*** in its anterior half.
6. ***Males have paired claspers at the base of pelvic fins.***
7. Males have a retractile frontal or cephalic clasper on the head in addition to normal pelvic claspers. The frontal clasper is club shaped and armed with denticles. One pair of additional anterior claspers are also present in front of pelvic fin.
8. For pairs of gills open to exterior by single external gill slit on either side covered by a fleshy operculum.
9. Mouth ventral. Single nasal aperture is confluent with mouth and the ***spiracles are absent.***

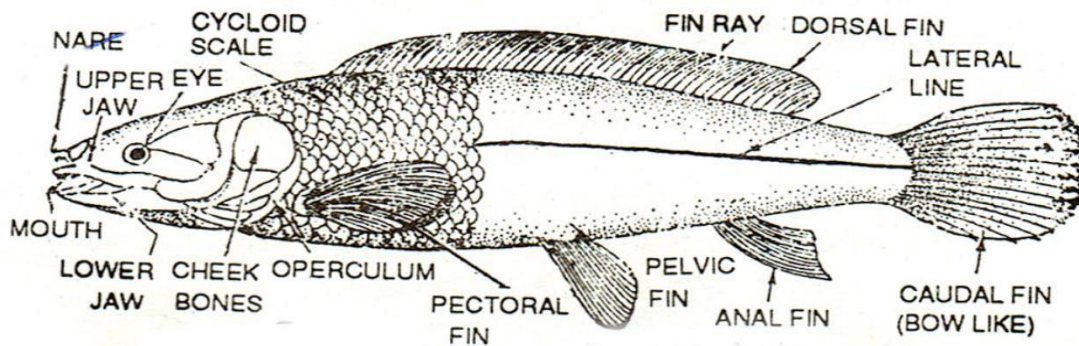
10. Upper jaw Is fused witti chondro-cranium. Jaws covered by hard flat plates
11. Lateral line canals on head are open groove.
12. Nerve cord is dorsal and tubular.
- 13.Oviparous and lays one egg at a time.

AMIA

Classification

Phylum	-	Chordata
Superclass	-	Pisees
Class	-	Teleostomil
Order	-	Amilformes
Genus	-	Amiiformes
Species	-	<i>calva</i>

Fig 4.11 Amiiformes



1. It is fresh water predatory fish of North America and commonly known as "*Bow—fin*".
2. *Exoskeleton is of cyclorid scales.*
3. Median and paired fins with dermal fin rays.
4. *Single dorsal fin extends all along the back.*
5. *Pelvic fins abdominal.*
6. Mouth ventral and *spiracles are closed.*
7. *Tail semihomoceral* (externally homo-cercal and internally heterocercal.)

8. The Pharynx perforated by gill slits and gills are covered by an operculum.

9. It constructs beautiful nest in breeding season and exhibits parental care.

WALLAGO

Classification

Phylum	-	Chordata
Subphylum	-	Vertebrata (craniata)
Class	-	Osteichthyes (Teleostomi)
Subclass	-	Actinopterygi
Superorder	-	Teleostei
Order	-	Cypriniformes
Family	-	Siluridae
Genus	-	Wallago
Species	-	attu

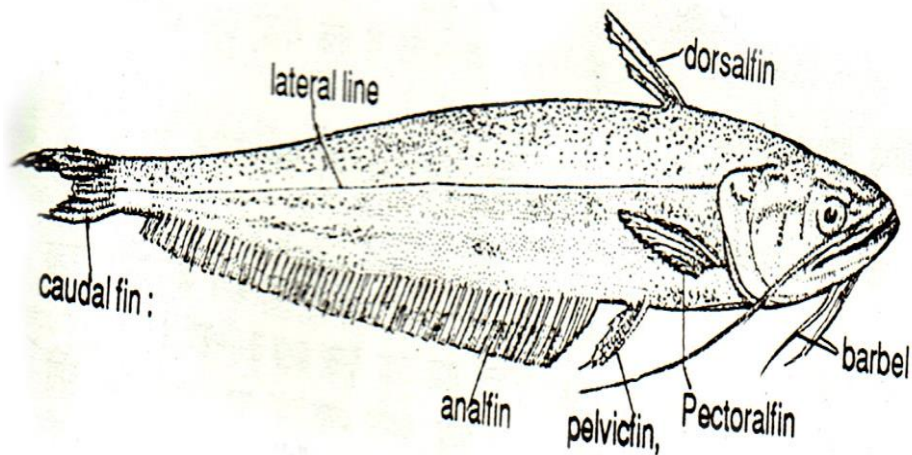


Fig 4.12 Wallago

1. It is a fresh water predatory fish, distributed throughout India and is commonly called *cat-fish, Lachi, Mullee or boalli* .
2. The colour is greyish brown above and white below with purplish head.
3. Head is with large mouth, small trunk and long tail which tapers behind.
4. *Mouth extends behind the orbits* and has villiform teeth in jaws.

5. Head bears 2 maxillary and 2 mandibular barbels.
6. The eyes are prominent.
7. Skin is scaleless.
8. Dorsal and Pectoral fins are small Pectoral spine is stout and serrated.
9. Anal fin is long but not confluent with caudal fin.
10. Gill membranes free. Weberian ossicles are present.

LABEO

Classification

Phylum	-	Chordata
Subphylum	-	Vertebrata
Class	-	Osteichthyes (Teleostomi)
Subclass	-	Actinopterygii
Superorder	-	Teleostei
Order	-	Cypriniformes
Family	-	Cyprinidae
Genus	-	<i>Labeo</i>
Species	-	<i>rohit</i>

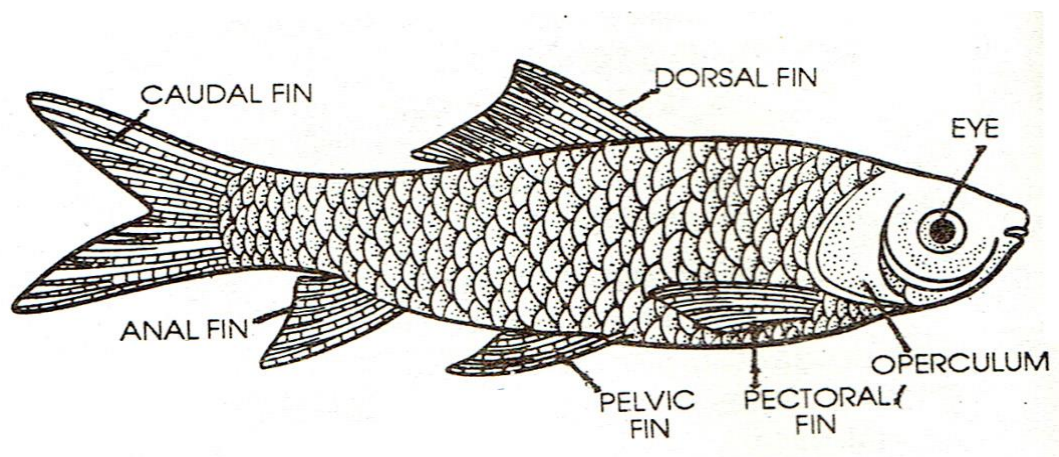


Fig 4.13 Labeo

1. It is commonly found in fresh water ponds, rivers, lakes and estuaries. It is commonly called '**Rohu** or **Indian carp**'
2. It is herbivorous and bottom feeder.
3. Body is fusiform and the colour is bluish or brownish above and silvery white below.
4. **Exoskeleton is of large cycloid scales.**
5. Head is produced into a short and blunt snout covered with tubercles.
6. **Mouth is sub-terminal and bounded by thick and fleshy lips**

7. A pair of small *maxillary barbels* arise from the upper lip.
8. Median and paired fins have bony fin rays.
9. Four pairs of gills are covered by operculum.
10. Dorsal fin Is large and single.
11. *Pectoral, pelvic* And *anal* fins are present.
12. *Homocercal tail* is surrounded by a *deeply notched caudal fin*.
13. Prominent lateral line runs along the sides of the body.
14. It is oviparous and breeds only in running water i.e., rivers and bund type of tanks.
15. Fertilization is external and takes place in running water.

ANABAS

Classification

Phylum	-	Chordata
Subphylum	-	Vertebrata
Superclass	-	Gnathostomata
Class	-	Osteichthyes
Subclass	-	Actinopterygii
Superorder	-	Teleostei
Order	-	Perciformes
Family	-	Anabantidae
Genus	-	<i>Anabas</i>

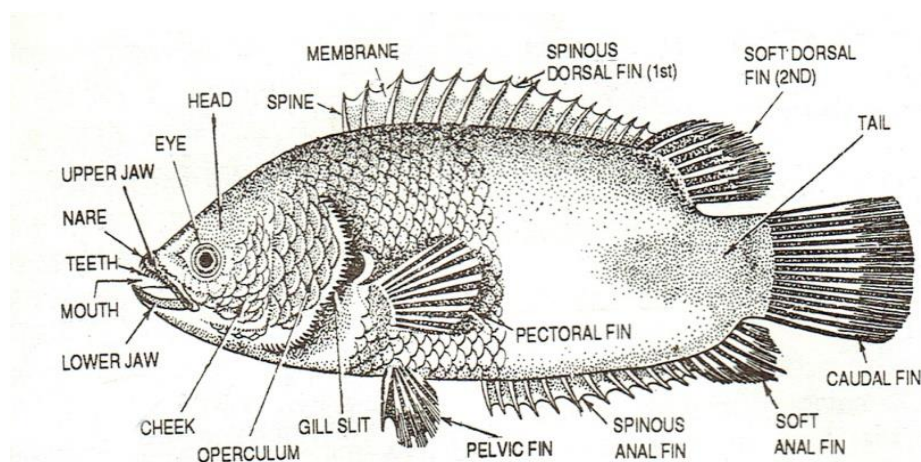


Fig 4.14 Anabas

1. Commonly called ***climbing perch*** and is found in fresh waters and estuaries of India, Ceylon, Burma and Malaya etc.
2. It is a predatory fish and is eaten a delicacy.
3. ***Airbladder Is physocleistic, and spiracles are absent***
4. Anterior part of dorsal median fins is made up of spinous rays.
5. ***Gills are supplemented with accessory respiratory organs which are in the form of membranous labyrinthine structures.***
6. Ventral fins abdominal and its spines help the fish in walking on the ground and it can live out side water for quite some time.
7. The operculum bears spines which help the fish in climbing on trees.
8. Caudal fin is round and ***scales are cycloid and ctenoid.***
9. ***The spiracles and claspers are absent.***
10. Dorsal tubular nerve cord is modified in front into brain and notochord gives rise to bony vertebral column.

ANGUILLA

Classification

Phylum	-	Chordata
Superclass	-	Pisces
Class	-	Teleostomi
Subclass	-	Actinopterygii
Order	-	Anguilliformes
Genus	-	<i>Anguilla</i>
Species	-	<i>vulgaris</i>

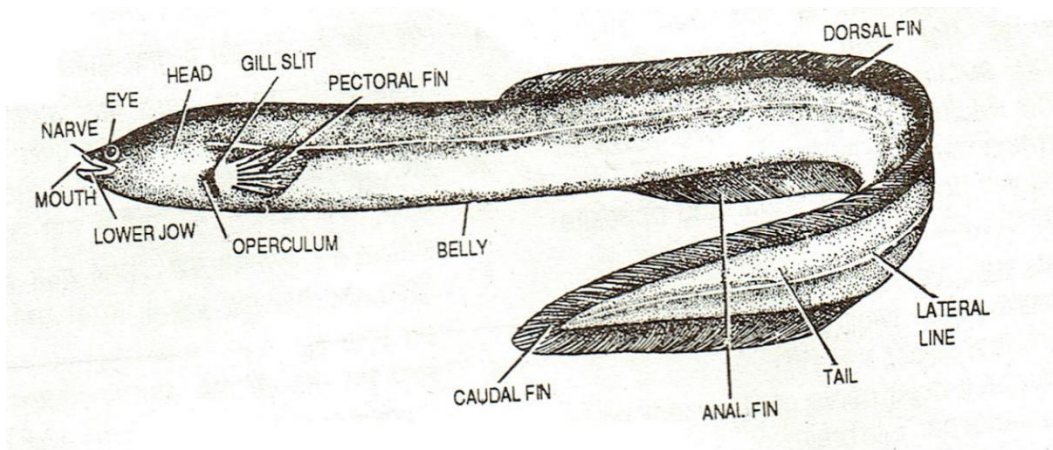


Fig 4.15 Anguilla

1. It lives in mmains and is commonly known as "European eel'.
2. Body is eleongated, cylindrical and eel like.
3. Skin naked but fldw.uli.j SCOW we burned in subcutis.
4. Paired and median fin are Iio oi branched rays.
5. Dorsal and anal fin are c4'w with caudal fin.
6. Pelvin fins are absent and Pectoral fins are small.
7. Minute and round gill openings are present on the sides and are covered by operculum.
8. Airbladder is closed and Weberian ossicles and premaxilae are absent.
9. It is a mlgratory fish. Adults migrate to Sargasso sea in autumn to breed. After spwning in deep waters they die. Development is through delicate transparent Leptocephalus larva (or glass fish). It feeds and growos in sea for 2-3 years, after which they return to rivers and metamorphos into adult.

CYPSELURUS OR EXOCOETUS

Classification

Phylum	-	Chordata
Group	-	Vertebrata
Subphylum	-	Gnathostomata
Super Class	-	Pisces
Class	-	Teleostoml
Subclass	-	Actinopterygll
Order	-	Belonlformes
Genus	-	Exocoetus

1. It is commonly called '***Flying Fish***' and is found in Indian and tropical Atlantic oceans. It feeds on prawnns, young fishes and their eggs.
2. ***It can skip above the surface of water and can glide for considerable distance.***
3. It is commonly called '***Flying Fish***' and is found in Indian and tropical Atlantic oceans. It feeds on prawnns, young fishes and their eggs.
4. ***It can skip above the surface of water and can glide for considerable distance.***

5. Body is cylindrical and the sides of body are silvery. ***The scales are cycloid.***
6. The eyes are large, nostrils are on sides mouth is wide and toothed.
7. Dorsal fin is located opposite to the anal fin and pelvic fins are large and abdominal.
8. The ***pectoral fins are as large as the body*** and are placed high up on the body. ***They work as parachutes.***

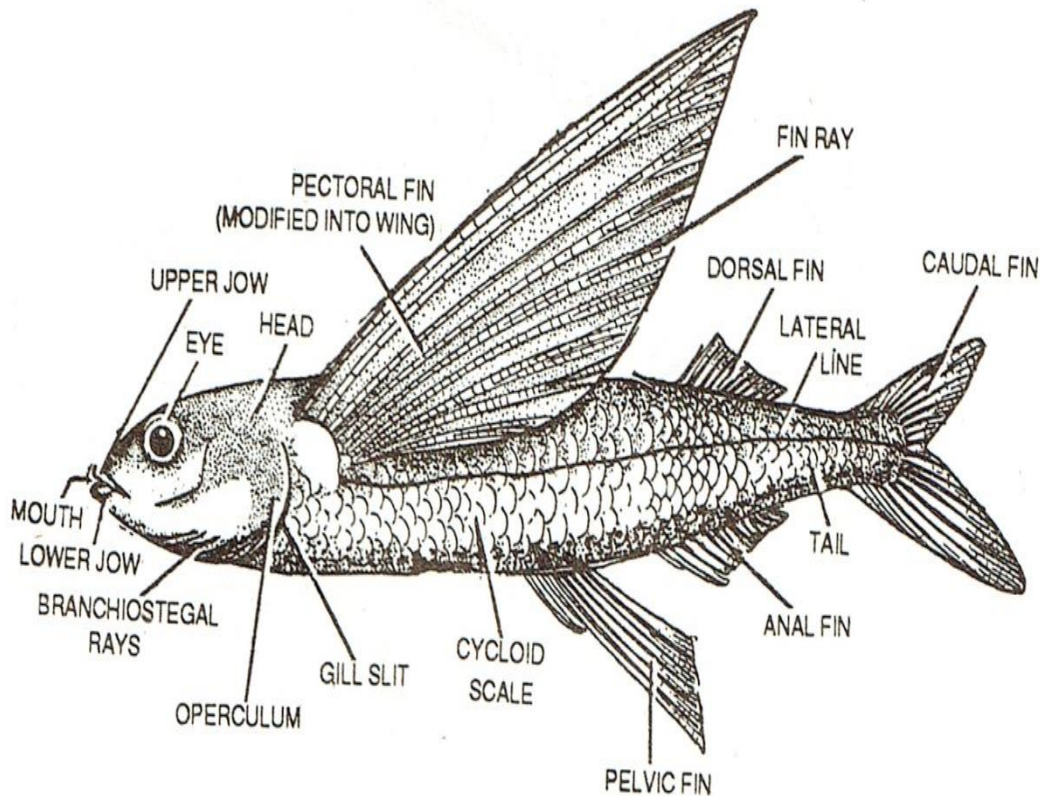


Fig 4.16 Exocoetus

9. ***The body is lifted above the water by forceful lashing of hypoblastic tail and pelvic fins on the water.***
10. They are oviparous and ***lack claspers and spiracles.***
11. The lateral line runs just above the lower edge of abdomen.
12. The dorsal tubular nerve cord is modified in front into brain and notochord gives rise to bony vertebral column.
13. ***It is also used as food.***

NEOCERATODUS (EPICERATODUS)

Classification

Phylum - Chordata

Subphylum	-	Gnathostomata
Super Class	-	Pisces
Class	-	Teleostomi
Subclass	-	Actinopterygii
Order	-	Belontiiformes
Genus	-	Cyprinus " lung fish "

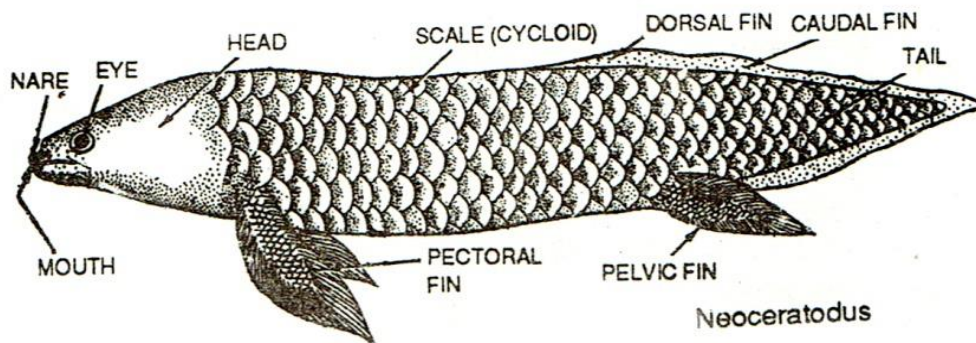


Fig 4.16 Cyprinus (lung fish)

1. It is fresh water fish found in rivers of Queensland in Australia and is commonly called "**lung fish**".
2. Exoskeleton is of cycloid scales.
3. Body is eel like.
4. Median and paired fins are present.
5. Pelvic and Pectoral fins are lobate and are with well developed fin rays.
6. Dorsal, anal and caudal fins are confluent.
7. **Tail is Diphycercal and pelvic girdle is single.**
8. **Branchial arches and gill-slits are five in number.**
9. **It has single air bladder acting as lung (Monopneumona).**
10. Mouth small and **jaws have specialized crushing tooth plates.**
11. Eyes comparatively reduced.
12. Cutaneous gills are absent in tadpole larva.
13. **They aestivate during drought in summers.**

BUFO

Classification

Phylum	-	Chordata
--------	---	----------

Class	-	Amphibia
Order	-	Sallentia
Suborder	-	Procoela
Family	-	Bufo
Genus	-	Bufo

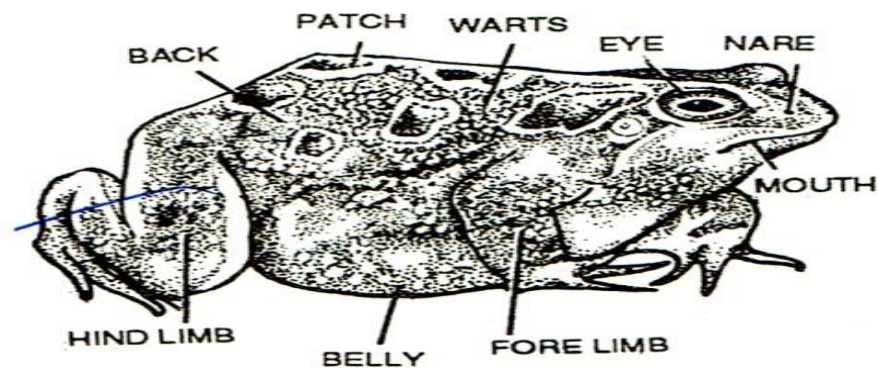


Fig 4.17 Bufo

1. It is terrestrial and nocturnal i.e., remains concealed during day and becomes active during night. It is commonly called 'Indian toad'.
2. Body is divisible into head and trunk.
3. ***Hind legs are much longer than the fore legs and have five and four digits respectively and web is poorly developed in hind legs.***
4. ***Skin on the dorsal surface is rough and bears warty out growths and poison glands.***
5. Eyelids are well formed and nictitating membrane is also present in eyes.
6. Large poison secreting ***parotid glands*** are present behind each tympanum.
7. ***External ear is absent but middle ear is represented by columella ouris*** which is connected with tympanum.
8. Both jaws are edentulous.
9. Skull has two occipital condyles.
10. All vertebrae are ***procoelus*** including VIII and IX. Urostyle has two condyles.
11. Heart is three chambered and kidney is mesonephric.
12. ***Males have a subgular vocal sac.***
13. Breeding takes place in water. Fertilization is external.

14. It is commonly called '*Flying Fish*' and is found in Indian and tropical Atlantic oceans. It feeds on prawns, young fishes and their eggs.

HYLA

Classification

Phylum	-	Chordata
Class	-	Amphibia
Order	-	Salientia (Anura)
Suborder	-	Procoela
Genus	-	Hyla
Species	-	arborea

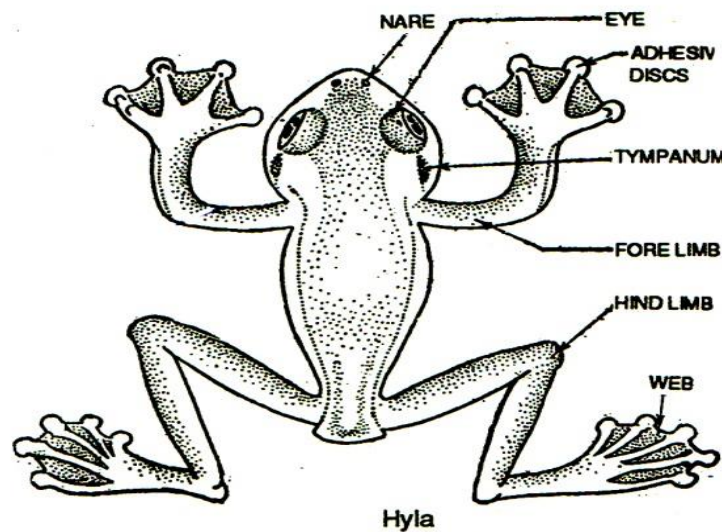


Fig 4.18 Hyla

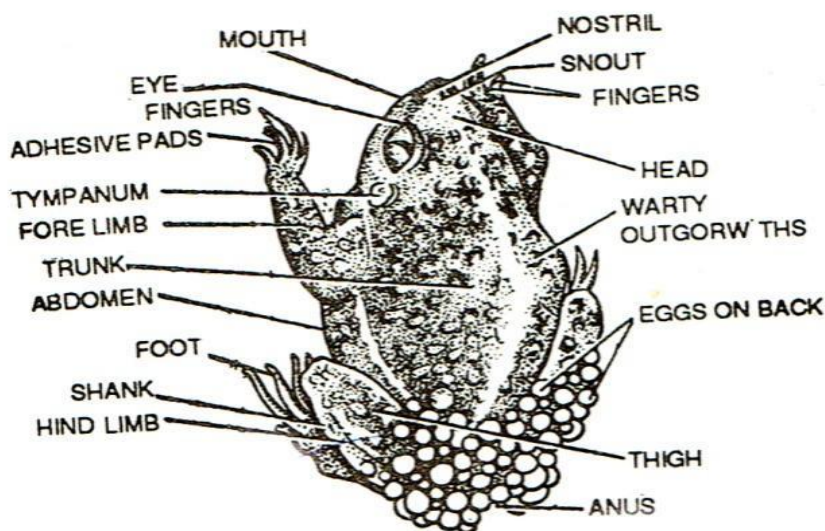
1. It is an *arboreal frog* i.e., living on trees and is commonly called '*tree frog*'.
2. Body is divisible into head and trunk. It's colour is green and it *rapidly changes colour*.
3. *Hind legs usually much longer than the fore legs and have five and four digits respectively. Terminally each digit bears glandular adhesive disc. Web between digits is absent.*

4. Skin of belly and throat has *hygroscopic glands* and is sticky in nature. It helps the frog to fix on leaf, stem or twig,.
5. Eyes have nictitating membrane.
6. External ear is absent but middle ear is represented by *columella* which is connected to tympanum. Middle ear opens into pharynx.
7. True jaws and well formed cranium present. *Homodont teeth are present in upper jaw. Lower jaw is edentulous.*
8. Skull has two occipital condyles.
9. Heart is three chambered and kidney is mesonephric.
10. *It exhibits micmicry.*
11. *It produces loud noise during breeding season.*
12. It lays eggs in water. Fertilization is external and development is through *adipole larva*.

ALYTES

Classification

Phylum	-	Chordata
Class	-	Amphibia
Order	-	Sallentia
Suborder	-	Procoela
Family	-	Discoglossidae
Genus	-	Alytes
Species	-	obstetricans



195 Alytes

Fig 4.19 Alytes

1. It is found in **west and central Europe** and live on land in grass. It is commonly called '**Midwife toad**'.
2. Body is divisible into head and trunk.
3. **Tail and exoskeleton are absent.**
4. **Hind limbs much longer than fore limbs and have 5 and 4 digits respectively. Web between digits hind legs is absent.**
5. **Skin on dorsal surface is rough and is provided with warty outgrowths and poison glands.**
6. Eyelids are movable, pupil is vertical nad nictitating membrane is present.
7. External ear is absent but middle ear is represented by **columella**, which is connected with tympanum.
8. **Disc –like nonprtrusible tongue is present.** Lower jaw edentulous, i.e., teeth are absent . Skull is dicondylic and ribs are present throughout life.
9. Vocal sacs are absent in males. Males exhibit parental care. by carrying cluster of eggs around their hind legs and staying in damp places untill egss are hatched.

PIPA

Classification

Phylum	-	Chordata
Class	-	Amphibia
Order	-	Sallentla
Suborder	-	Oplsthocoela
Family	-	Pipldae
Genus	-	Pipa
Species	-	americana

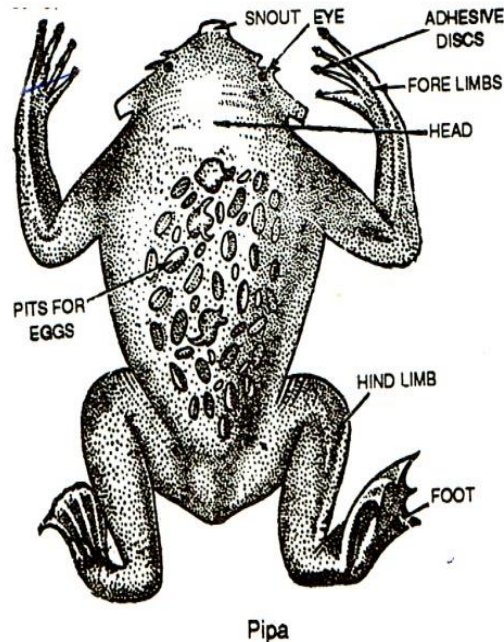


Fig 4.20 Pipa

1. It is an aquatic toad and is commonly called '**Surinam toad**'.
2. Body is much flattened, head is small and triangular and trunk is large.
3. **Toes are logn and webbed. Tips of digits of fore lims are provided with glands.**

4. *The skin is papillated and each papilla bears a spine and an opening of poison glands.*
5. Eyes are small and eyelids are usually absent. Nictitating membrane is present.
6. Tympanum is invisible and middle ear is represented by columella.
7. Tongue and teeth are absent.
8. Numerous dermal flaps and tentacles are present on either side along the upper jaw. Skull is dicondylic and vertebrae are opisthocoelus.
9. Heart is three chambered and kidney is mesonephric. Males have a transverse fold on the belly.
10. Female exhibits parental care. During breeding season skin of dorsal side of female becomes soft, develops pits in which eggs are carried till hatching. Incubation period lasts for three months.

SALAMANDRA

Classification

Phylum	-	Chordata
Class	-	Amphibia
Order	-	Caudata (urodela)
Suborder	-	Salamandroidea
Genus	-	Salamandra
Species	-	maculosa

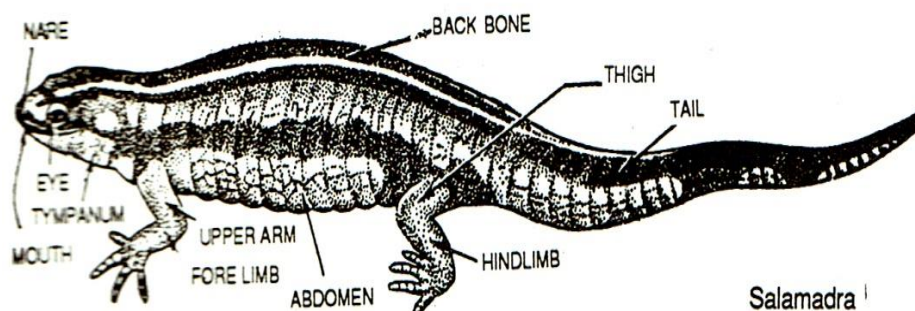


Fig 4.21 Salamandra

1. It is terrestrial and is commonly called '*fire salamander*'
2. Body is divisible into head, trunk and subcylindrical tail. Its body colour is shining black with yellow spots.

3. *Skin with numerous pores and skin glands are visible as swellings on either side of body. When offended it ejects poisonous milky fluid from skin glands which is capable of killing small animals.*
4. Eyes are with movable eyelids. Nictitating membrane is present.
5. Fore limbs have *four* and hind limbs have *five digits* of equal size.
6. *Teeth are present in both jaws.*
7. *Gular fold on throat is present.*
8. Skull is dicondylic.
9. *Vertebrae are opisthocoelus.*
10. Heart is three chambered and kidney is mesonephric.
11. Male lays sperms in spermatophore which is picked up by female with her cloacal lips and taken internally to fertilize her eggs. *Female gives birth to larvae*, whose further development is completed in water.

NECTURUS

Classification

Phylum	-	Chordata
Class	-	Amphibia
Order	-	Caudata (urodela)
Suborder	-	Protelidae
Family -		Proteidae
Genus	-	Necturus
Species	-	maculosus

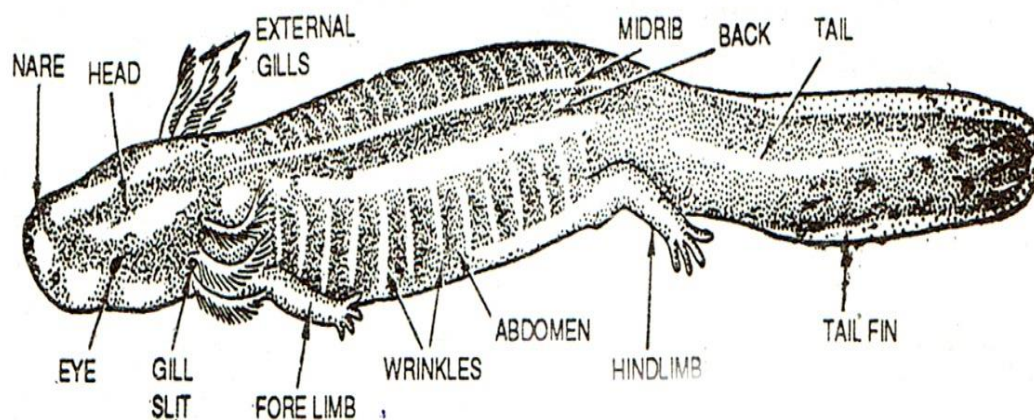


Fig 4.21 *Necturus*

1. It is a nocturnal, bottom dweller North American fresh water newt and is commonly called 'Mud puppy'.
2. It's colour is dark brown with few black spots.
3. Body is divisible into head, trunk and tail.
4. Rectangular head and elongated trunk are dorsoventrally flattened but tail is laterally compressed and with prominent tail fin. ***Hind limbs and fore limbs are feeble and have for digits in each.***
5. ***Three pairs of fringed external gills and two pairs of gill slits are present behind the head on lateral sides.***
6. Eyes are small and without eyelids but nictitating membrane is present.
7. Tympanum membrane are absent and middle ear opens into pharynx.
8. Skull is dicondylic.
9. Teeth are present in jaws.
10. ***Lateral line system well developed.***
11. Heart is three chambered and kidney is mesonephric.
12. ***Skin of the throat forms gular folds.***
13. ***It shows permanent neotenic larval stage.***

AMBYSTOMA

Classification

Phylum	-	Chordata
Class	-	Amphibia
Order	-	Caudata (urodela)
Suborder	-	Ambystomoldea
Genus	-	Ambystoma
Species	-	tigrum

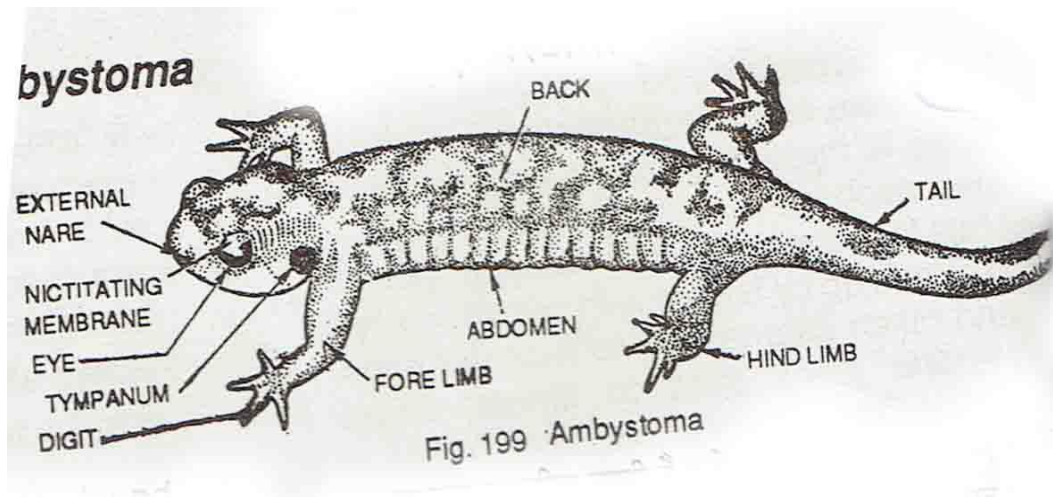


Fig 4.22 Ambystoma

1. Adult is terrestrial and is found in North America, Central exico and United States, It is commonly called "***Tiger Salamander or 'spotted salamander'***".
2. Yellow and orange patches are present on dorsal and lateral sides of the body.
3. Body is divisible into head, trunk and tail.
4. Head is flat and some what rounded tail is cylindrical and ***trunk has 12 intercostal grooves.***
5. Eyes with movalbe eyelids and nictitating membrane is present.
6. ***A pair of polsonous parotid glands are present behind tympanum.***
7. Well developed ***fore and hind limbs have 34 and 5 digits respectively.***
8. Skull is dicondylic and jaws are toothed.
9. ***Vertebrae are amphicoelus.***
10. Heart is three chambered and kidneys are mesonephric.
11. A gular fold is present on the throat.

AXOLOTL LARVA

Classification

Phylum	-	Chordata
Group	-	Vertebrata
Class	-	Amphilia
Order	-	Caudata (urodela)
Suborder	-	Ambystomoldea
Genus	-	Axolotl larva of Ambystoma

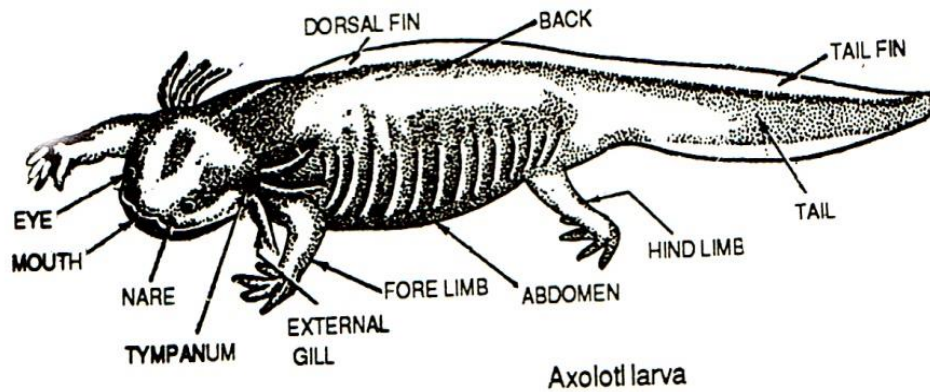


Fig 4.23 Axolotl larva of Ambystoma

1. It is the Axolotl larva of Ambystoma and is found in *lakes of Mexico*.
2. It is perennial and its body is visible into head, trunk and laterally compressed tail head, trunk and laterally compressed tail surrounded by tail fin.
3. Three external gills and 4 gill-clefts are present on either side behind the head.
4. Both pairs of limbs have 4 digits in each.
5. Eyes are with movable eyelids.
6. **Jaws are toothed** and are well developed.
7. **Vertebrae amphicoelus**.
8. In iodine deficient water the larva does not metamorphose into adult instead it becomes sexually mature i.e., develops gonad but remains morphologically immature. These sexually mature larvae mate and produce fertile eggs. This phenomenon is known as Neteny.

AMPHIUMA

Classification

Phylum	-	Chordata
Class	-	Amphibia
Order	-	Caudata (urodela)
Family	-	Amphiumidae
Suborder	-	Ambystomoldea
Genus	-	Amphiuma
Species	-	Means.

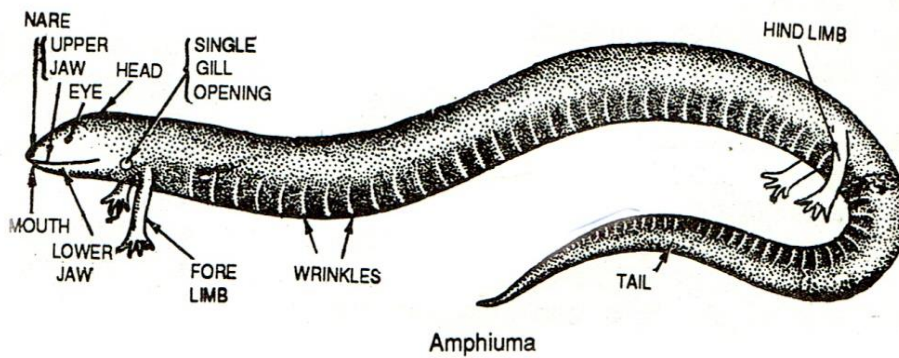


Fig 4.24 Amphiuma

1. It lives in swamps and rice fields in North America and is commonly called ‘*Congo-eel*’.
2. It has long, cylindrical and eel-like body with pointed head.
3. Cylindrical long tail tapers behind and is *without tail fin*.
4. **Both pairs of small rudimentary limbs have two small digits in each.**
5. **A single gill opening is present on either side of head and is guarded by flaps.**
External gills are absent but lungs are present.
6. Well developed functional eyes are without eyelids.
7. *Vertebrae are amphicoelus.*
8. *Female exhibit parental care by coiling around the eggs till they are hatched.*

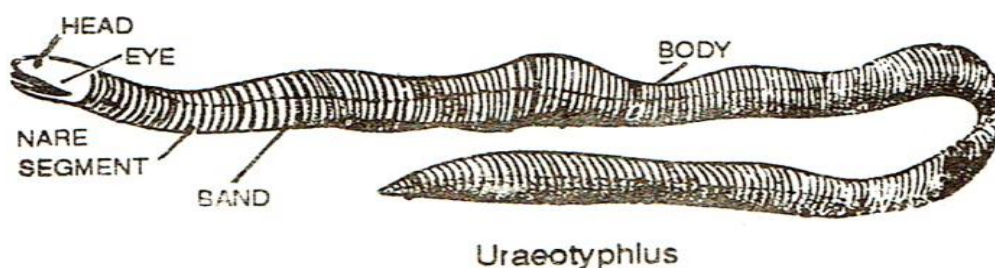
URAEOTYPHLUS

(Apodon And Ichthyophis)

Classification

Phylum	-	Chordata
Class	-	Amphibia
Order	-	Gymnophiona (Apoda)
Genus	-	Uraeotyphlus

Fig 4.25 Uraeotyphlus



1. It lives in burrows and is found in India, South Africa and South America.
2. Elongated body is worm-like and has extrnal ring like annull (pseudometamerism).
3. Skin naked but small dermal scales are embedded in it.
4. Limbs, tail and neck are absent.
5. Anus is sub-terminal.
6. Greatly reduced eyes remain concealed beneath the skin.
7. A special sensory tentacular apparatus lies in a pit between the eyes and nares.
8. Left lung is reduced an right is exceptionally long and sac-like.
9. It exhibits parental care. The males guard the eggs by encircling them.
10. In Ichthyophis female shows parental care instead of male.
11. The skin in Ichthyophis bears slime and squirt glands. The squirt glands eject irritating fluid.

SPHENODON

Classification

Phylum	-	Chordata
Class	-	Reptilla
Subclass	-	Diapsida
Order	-	Rhynchocephalia
Genus	-	Sphenodon
Species	-	punctatum

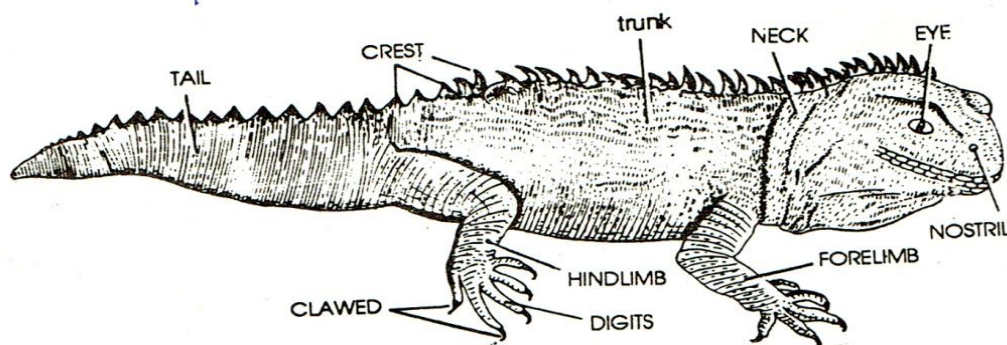


Fig 4.26 Sphenodon

1. It is nocturnal, lives in burrows, lead a semiaquatic life, feed on insects, molluscs and small vertebrates and is molluscs and small vertebrates and is *found in New Zealand*. It is commonly called '*Tuatara*'.
2. *It is called living fossil because it has several primitive characters i.e.,*
 - (a) presence of median pineal eye,
 - (b) presence of abdominal ribs,
 - (c) *vertebrae amphicoelous and caudal vertebrae having chevron bone*, and vestiges of notochord persisting throughout life.
 - (d) *Skull with three temporal bridges and a proatlas*.
3. Body is dull olive green with white and yellow spots above and white below.
4. *Skin is covered by scales*. Several *crest like spiny scales* are present along mid-dorsal line.
5. Laterally compressed BI long and the *limbs are two pairs, clawed and pentadactyle*.
6. *Parietal eye (pineal eye) is prominent and functional. It has retina and lens*.
7. *Skull has two complete temporal fossae*.
8. Upper jaw bears acrodont teeth.
9. Anal opening is transverse and males are without copulatory organ.

HEMIDACTYLUS

Classification

Phylum	-	Chordata
Class	-	AmphibiaReptilia
Subclass	-	Diapsida
Order	-	Squamata
Suborder	-	Lacertilla
Genus	-	Hemidactylus
Species	-	flaviviridis

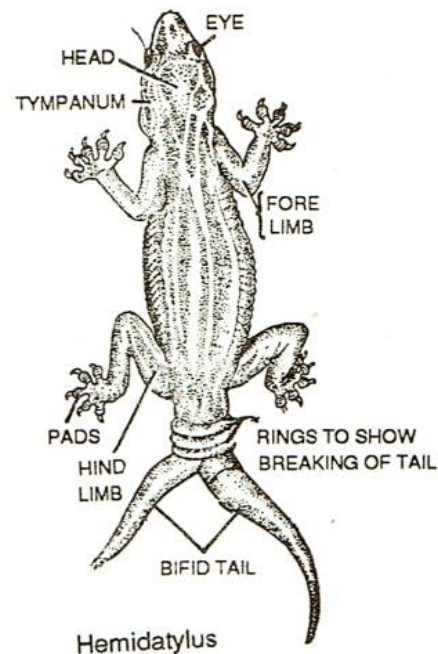


Fig 4.27 Hemidactylus

1. It is a common 'house or wall lizard and is usually known as 'house gecko'.
2. The skin is covered with minute scales which are more prominent on head. The skin also has poison glands.
3. Two pairs of limbs are penadactyle and clawed.
4. Tail is smaller and brittle and exhibits autotomy i.e., it breaks its tail on the approach of danger.
5. A pair of nostrils, and a pair of eyes are present on head. Eyes have movable eyelids, nictitating membrane and vertical pupil.
6. External ears are represented by tympanum. Jaws bear pleurodont teeth.
7. Digits are flattened and broad ventrally and bear numerous transverse lamellae arranged in two rows which help in walking aong vertical walls and across the cellings.
8. Tongue is sticky and protrusible.
9. Skull monocondylic and has two temporal arcades.
10. Male with eversible double copulatory organs (hemipenes).

CALOTES

Classification

Phylum	-	Chordata
Class	-	Reptilla
Subclass	-	Diapsida
Order	-	Squamata
Suborder	-	Lacertilla
Family	-	Agamidae
Genus	-	Calotes
Species	-	versicolor

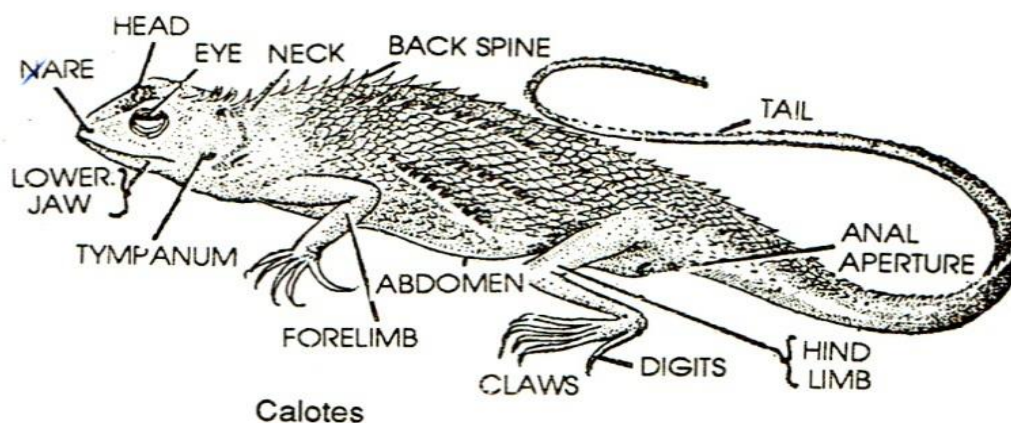


Fig 4.28 Calotes

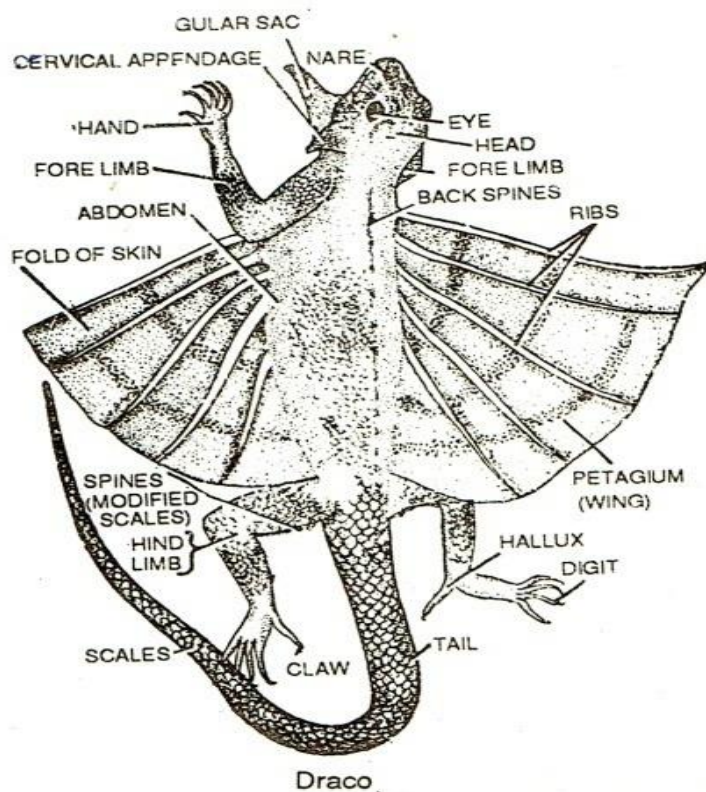
1. It is arboreal and lives in gardens, forests and fields and is commonly called 'gir-git' or 'garden lizard'.
2. The exoskeleton is in the form of minute, horny and imbricate scales all over, scales of mid dorsal line are large, spiny, movable and pointing backward and upwards and form a crest or frill.
3. Body is divisible into head, neck, trunk and long cylindrical tail.
4. Body is greenish yellow above and the throat is red.
5. Limbs two pair, pentadactyle and clawed. **Hind limbs are longer than fore limbs.**
6. Eyes are with movable eyelids and nictitating membrane.
7. Ear opening is covered by tympanum.
8. Skull is monocondylic and jaws bear acrodont teeth.
9. Males are longer than females.
10. It possesses remarkable quality of colour change when excited.

DRACO

Classification

Phylum	-	Chordata
Class	-	Reptilia
Subclass	-	Diapsida
Order	-	

Genus
Species



	-	Squamata
Suborder	-	
	-	Lacertilla
	-	Draco
	-	Volans

Fig 4.29 Draco

1. It is arboreal in habit and is commonly called '*flying lizard*'. It is found in Sumatra, Java, Borneo and forests of Kerala. It is small and brilliantly coloured lizard with a very long tail.
2. Dorsoventrally flattened body is covered with minute scales. Numerous spines are present on head and tail. 'The spines are modified scales.'
3. Both pairs of limbs are well developed, clawed and pentadactyle.
4. External ear is represented by tympanum. Eyes have movable eyelids.
5. Jaws bear acrodont and heterodont teeth.
6. The skin of lateral sides of trunk expands to form parachute-like patagium or 'wings', supported by 5 thoracic ribs. The 'wings' are used for gliding from tree to tree.
7. Neck bears three hooked appendages of which median is largest. A vertical gular pouch hangs down from the ventro-median part of throat. It is larger in males.

CHAMAELEON

Classification

Phylum	-	Chordata
Class	-	Reptilia
Subclass	-	Diapsida
Order	-	Squamata
Suborder	-	Lacertilla
Genus	-	Chamaeleon
Species	-	vulgaris

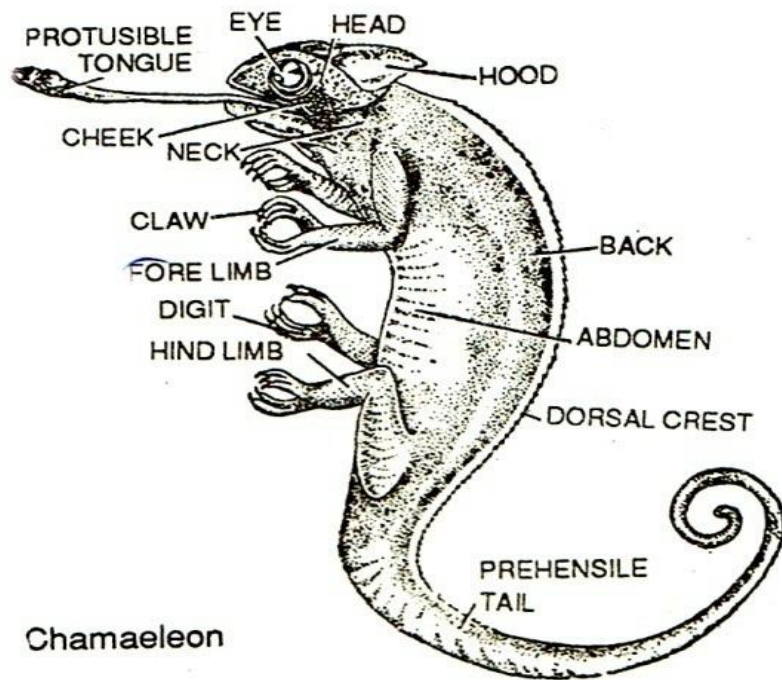


Fig 4.30 Chamaeleon

1. It is an arboreal lizard found in Africa Madagascar and India.
2. Laterally compressed body is covered with scales which are modified into small tubercles. Prominent serrated crest is present along the middorsal and midventral line.
3. Tail is long and prehensile. Casque-shaped head bears prominent hood formed by squamosal and occipital bones.
4. Eyes are located on movable elevated cones on the head making the vision binocular. Tympanum is absent.
5. Club shaped, long, sticky and protrusible tongue works like a spring.
6. Two pairs of well developed clawed, and pentadactyls limbs are adapted for grasping. Feet are zygodactylus, and have opposable digits peculiarly arranged in groups of 3/2 in hind limbs.
7. They are capable to change their body colour rapidly to blend with their surroundings.
8. Lungs are with air sacs, teeth acrodont and vertebrae procoelus.

NAJA (COBRA)

Classification

Phylum	-	Chordata
Class	-	Reptilia
Subclass	-	Diapsida
Order	-	Squamata
Suborder	-	Ophidia
Genus	-	Naja
Species	-	Naja

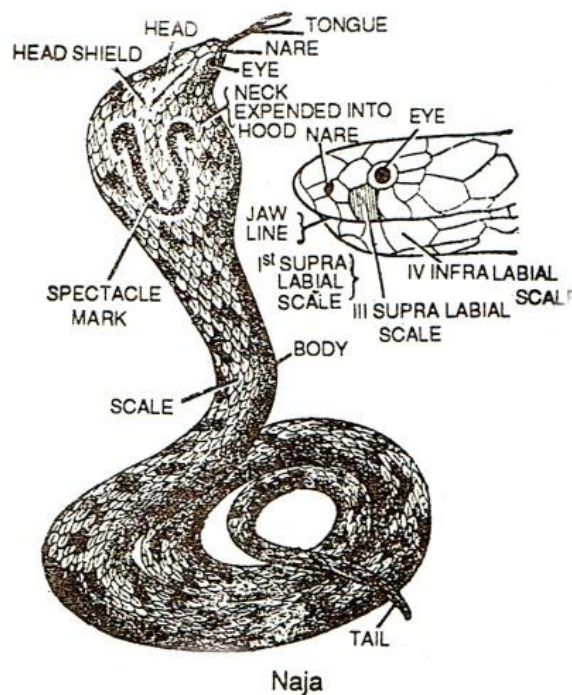


Fig 4.31 Naja

1. It is a diurnal and deadly poisonous snake commonly known as 'Cobra' or 'Naag'.
2. Its blackishbrown body is long cylindrical and without limbs and girdles.
3. Tail is narrow and cylindrical and head is small.
4. Body is covered with small scales on dorsal side and broad transverse and plate-like scales on belly. Head is covered with shields. Of these IIIrd supra labial shield touches the eye and nasal shield.
5. The IVth Infra labial shield is the largest. The subcaudal shields largest. The subcaudal shields (scales under the tail) are in two rows and are divided.
6. Eyes have immovable eyelids and pupil is round. Tympanum is absent.
7. Bifid tongue is protrusible.
8. The maxilla has two anterior grooved and permanently erect Proteroglyphous fangs.
9. The neck is expandable into hood and bears a spectacle mark (v) above. It is a defensive organ. Its poison is neurotoxic. Its food is small birds, rats, frogs and lizards etc.

VIPERA (VIPER)

Classification

Phylum	-	Chordata
Class	-	Reptilia

Subclass	-	Diapsida
Order	-	Squamata
Suborder	-	Ophidia
Genus	-	Vipera
Species	-	russelli

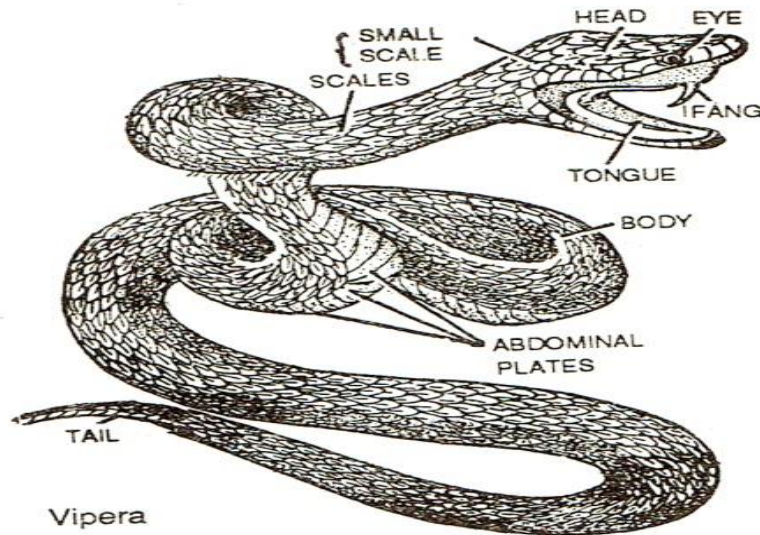


Fig 4.32 Vipera

1. It is nocturnal, terrestrial and ***the largest pitless viper snake*** found in Europe, Asia, Sri Lanka, Burma and India. It is commonly called '***Chained viper***', '***Dabola***' or '***Suskarna***'.
2. Body is covered with small scales. Of these the ventral scales are broad, transverse and plate-like and cover the whole belly.
3. The head is somewhat triangular and flat and is covered with uniform small scales as are present on dorsal surface of the body. A yellow '^' Mark is present on the head.
4. Tail small and subcaudal shields are in two rows.
5. Three rows of large black rings, which appear like a chain, are present on the upper surface of body.
6. Large ***fangs are solenoglyphous*** (tubular) and remain folded when not in use.
7. Nostrils are large, and oblique.
8. Eyes have movable eyelids and pupil is vertical. Tympanum is absent.
9. Tongue is bifid and protrusible.
10. ***It is a deadly poisonous snake, its venom is haemolytic and produces severe pain and bleeding.***

CROCODILUS

Classification

Phylum	-	Chordata
Class	-	Reptilla
Subclass	-	Diapsida
Order	-	Crocodilla
Genus	-	Crocodilus
Species	-	palustris and porosus

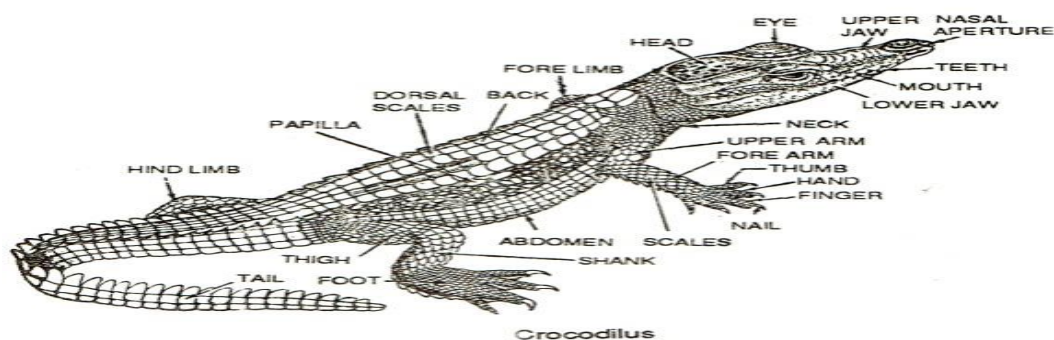


Fig 4.33 Crocodilus

1. It is found in tropical fresh water rivers, of Central America, Asia, Africa, Indonesia, Australia or **Marshes of India**.
2. It is a predator and is commonly called '**maggar**' or **marshy crocodile of India**.
3. It's long, cylindrical and depressed body is dark olive green with black spots or bands.
4. Head is produced into a flat and somewhat conical snout. Nostrils are present on the snout, eyes are with movable on the snout, eyes are with movable eyelids and ear openings are situated high on the head.
5. When it dives, the ear openings get covered by a flap of skin, nostrils are covered by valves and eyes by nictitating membrane.
6. **Skin is thick and leathery** and bears **scales, bony plates** and **bony scutes**. Skin of dorsal and ventral surface is with **rectangular horny scutes** supported by dermal bony plates.
7. Massive and **laterally compressed tail bears double crest of vertical scutes in the proximal half and single crest in the distal half** along the sorsal surface.
8. Limbs are two pairs, short, strong, pented-actyle and clawed. Hindi limbs have 4 toes only.

9. *Pheromone glands two pairs-one on throat and other in a longitudinal slit near cloaca.*
10. Teeth are similar and *the codont and are embedded in sockets.* IVth mandibular tooth fits into a groove in upper jaw and remains visible from outside. The Vth upper tooth is largest.
11. Palate hard, bony and complete and *mandibular symphysis extends upto VIIth or VIIIth teeth.*
12. *Heart completely 4 chambered.* Heart and lungs are embedded in pleural cavities and are separated from rest of the viscera by a *muscular diaphragm.*
13. *A simple and grooved copulatory organ is present in males.* Female is oviparous.
14. It is very aggressive and attacks man. The back bears 4-6 rows of vertical scutes or ridges.

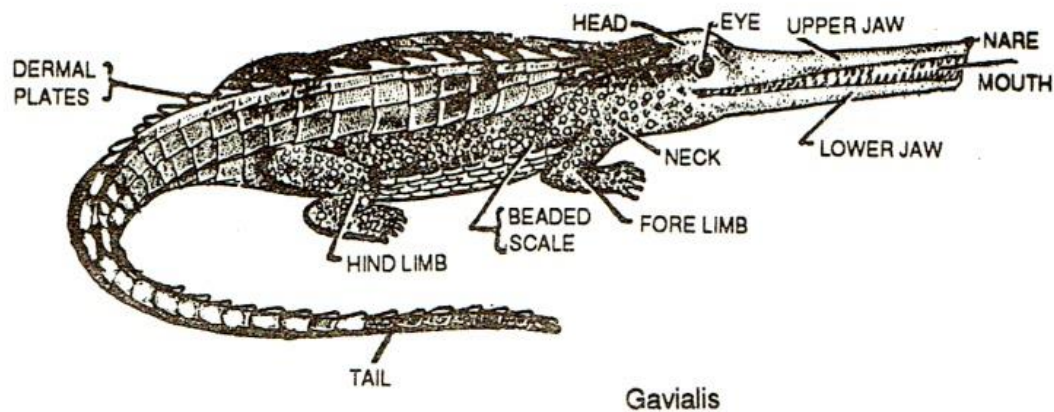
GAVIALLS

Classification

Phylum	-	Chordata
Class	-	Reptilla
Subclass	-	Diapsida
Order	-	Crocodilla
Genus	-	Gavialis
Species	-	Gangeticus

1. It is a *plscivorous, fresh water form* found in *Ganges river in India* and is commonly called '*Gharial*' or '*Naka*'.

Fig 4.34 Gavialis



2. It's logn, cylindrical and depressed body is dark olive green.
3. ***Had is produced into very long narrow beak like snot which in turn is produced into a club shaped structure at the tip.*** Nostnis are at the tip of snout, eyes are with movable eyelids and ear openings are situated high on the head.
4. When it dives, its ear openings get covered by a flap of skin, nostrils are closed by a flap of skin, nostrils are closed by valves and eyes are covered by nictitating membrane.
5. ***Skin is thick and leathery and has scales, bony plates and horny scutes. Skin of dorsal and ventral surface is with rect-angular horny scutes (modified scales) supported by dermal body plates.***
6. ***Massive and laterally compressed tail bears double crest of vertical scutes in the proximal half and single crest in the distal half along upprrt surface.***
7. Limbs are two pairs, short, strong, pentadactyle, clawed and webbed. Hind limbs have 4 toes only.
8. ***Similar thecodont teeth are embedded in sockets. Neither pit nor IVth mandibular tooth.***
9. Palate hard, bony and complete. ***Mandibular symphysis extends upto15th teeth.***
10. ***Heart completely 4 chambered*** and lungs enclosed in pleural cavities. Heart and lungs are separated from rest of the viscera by a muscular ***diaphragm.***
11. Sexes are separate. A simple and grooved copulatory organ is present in males. It is oviparious.

PASSER DOMESTICUS (HOUSE SPARRROW)

Classification

Phylum	-	Chordata
Class	-	Aves
Subclass	-	Neornithes
Sub Order	-	Neognathae
Genus	-	Passer
Species	-	domesticus

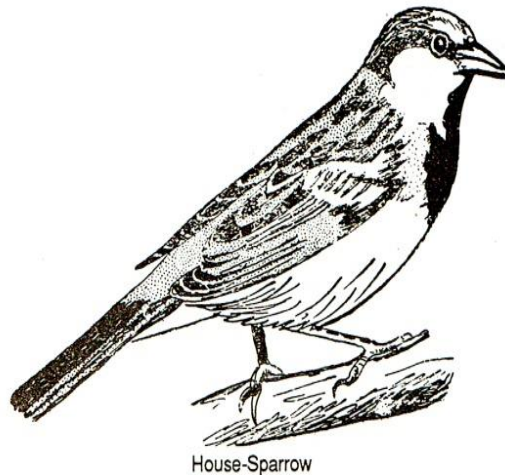



Fig 4.35 Passer

1. It is commonly called '**house sparrow**' or '**gauraiyya**' and is found throughout India, Pakistan, Burma and Sri Lanka.
2. Body is light brown or dove gray on back and whitish on absomen and is covered by feathers.
3. **Exoskeleton is represented by feathers.**
4. The baeak is small, stout and pointed at tip and is of **seed crushing type**.
5. Feet are of perching type with three toes infront and directed forwards and first toe or halux behind and directed backwards. **Fore limbs are modified into wings.**
6. It **makes nest during breeding seasons and breeding takes place throughout year.**
7. It is viviparous and lays 3 to 5 pale white greyish eggs at time.
8. **It exhibits parental care.**
9. Itis diurnal, herbivorous and **mainly granivorous**.
10. **Palate is of egithognathous type.**

COLUMBA (PIGEON)

LIBIA

Classification



Phylum	-	Chordata
Class	-	Aves
Subclass	-	Neornithes
Sub Order	-	Neognathae
Order	-	Columbiformes
Genus	-	Columba
Species	-	libia

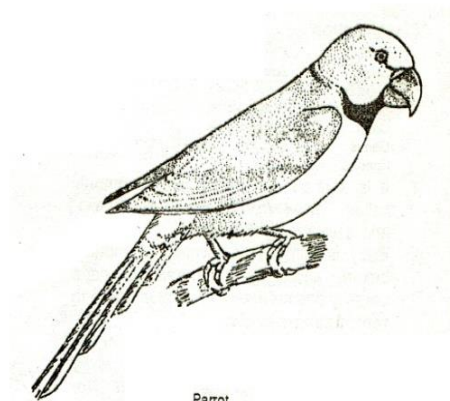
Fig 4.35 Columba

1. It is commonly called '**pigeon**' in English and '**Kabutar**' in Hindi and is found throughout India and USA.
2. Body is dark grey with blakish stripes on the upper side of wings and light grey on the lower side. Body is covered by feathers.
3. ***Exoskeleton is represented by feathers.***
4. Premaxillae are produced into a beak which is small, stout, pointed at tip and is of ***seed crushing type.***
5. ***Fore limbs are modified into wings for flight. Feet are of perching type with slight modification for clinging on walls.***
6. Neck is distinct and somethimes with a ring of black or blue colour.
7. Sexual dimorphism is absent but sexes are separate.
8. It is oviparous and lays eggs in nest. ***It exhibits parental care.***
9. ***Palate is of schizognathous type.***

PSITTACULA

(PARROT)

Classification



Phylum	-	Chordata
Class	-	Aves
Subclass	-	Neornithes
Sub Order	-	Neognathae
Order	-	Psittaciformes
Genus	-	Psittacula
Species	-	krameri

Fig 4.36 Psittacula

1. It is found in India, Pakistan, Burma and USA and is commonly called '*parrot or tota*'.
2. Body, except the beak and hind limbs, is completely covered by bright green plumage, Neck may have a red ring around it.
3. **Beak is coral red, small but stout, sharp edged and deeply hooked and is modified for eating fruits and for cracking nuts.**
4. **Feet are zygodactylus, i.e., first and IVth, toes are directed backward and IIInd and IIIrd toes directed forward, thus well adapted for grasping, holding, climbing and clinging. The outer hind toe is irreversible. Digits (toes) are clawed.**
5. *Exoskeleton is represented by feathers on body, scales on legs, claws on toes and horny sheath on beak.*
6. Upper jaw is movable in vertical plane. Jaws edentulous and are covered with horny sheath and premaxillae are produced into a beak.
7. Tail is made up of elongated tail feathers.
8. It forms nest in breeding season and is oviparous.
9. It is diurnal, gregarious and intelligent and it famous for mimicking words taught by the master and trainer.
10. It is a very popular domestic cage bird.

OWL

Classification

Phylum	-	Chordata
Class	-	Aves
Subclass	-	Neornithes
Superorder	-	Neognathae
Order	-	strigiformes
Genus	-	Bubo
Species	-	bubo




Fig 4.37 Bubo

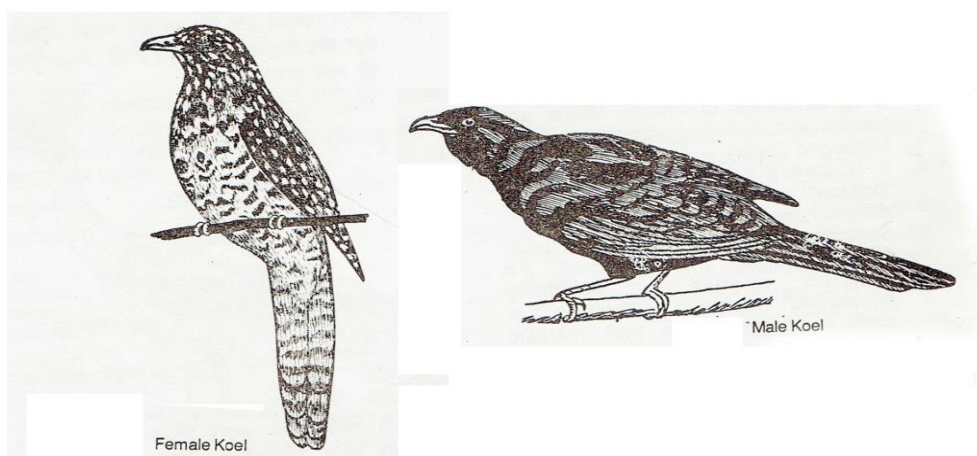
1. It is a large and heavy bird commonly called '**great horned owl**' or 'Uiloo' and is university distributed.
2. Body is completely covered by mottled brown and grey coloured plumage dorsally and creamish white plumage with vertical plumage with vertical streaks below.
3. It is carnivorous and carrion feeder hence ***small powerful beak is very sharply edged and hooked for tearing flesh of the pray.***
4. ***Two distinct feather tufts on the head look like two horns.***
5. Eyes are immovable, large, round and forwardly directed and are situated close to each other in a disc of radial feathers giving this bird binocular vision.
6. Tail is made up of feathers.
7. A characteristic feature of this bird is that its legs are completely covered by feathers instead of scales.
8. ***Feet are specially modified for perching on twigs and picking and holding the prey. Toes bear well developed curved claws and all toes, except one, are directed forward.***
9. ***Neck is short but highly movable. The movability is so much that the head can rotate to 180⁰ degree.***
10. Exoskeleton is represented by feathers on body and ***horny sheaths*** on beak and ***claws in toes.***
11. It is oviparous.

12. It is nocturnal and detects prey through especially equipped ears. The bird can comfortably look in dark and can easily hunt.

KOEL (EUDYNAMIS)

Classification

Phylum	-	Chordata
Class	-	Aves
Subclass	-	Neornithes
Superorder	-	Neognathae
Order	-	Cuculliformes
Genus	-	Eudynamis



Fig

4.38 Eudynamis

1. It is found throughout India, Pakistan and Burma and is commonly called '**Koel**' Or '**Kokila**'.
2. It is of the same colour and size as the crow but comparatively slimmer and with longer tail than crow.
3. It's body is covered by plumage of **glistening black colour in male and of brown colour with white spots in female**.
4. Yellowish green **beak is modified for fruit eting** and is small, straight and pointed.
5. Small red eyes are with rounded pupil.
6. Tail is made up of feathers only and neck is distinct.
7. **Exoskeleton is represented by feathers on body, scales on hind legs, claws in toes and horny sheath on beak.**

8. Feet are modified for perching and have 4 clawed digits.
9. *It is oviparious. It does not make nest herself but layer eggs in a crow's nest. So eggs and young ones are looked after by crow (nest paasite).*
10. *Sexual dimorphism is conspicuous. Males have melodious voice but females utter quic and sharp 'Kik-kik-kik'.*

PAVO (PEACOCK)

Classification

Phylum	-	Chordata
Class	-	Aves
Subclass	-	Neornithes
Superorder	-	Neognathae
Order	-	Galiformes
Genus	-	Pavo
Species	-	Cristatus

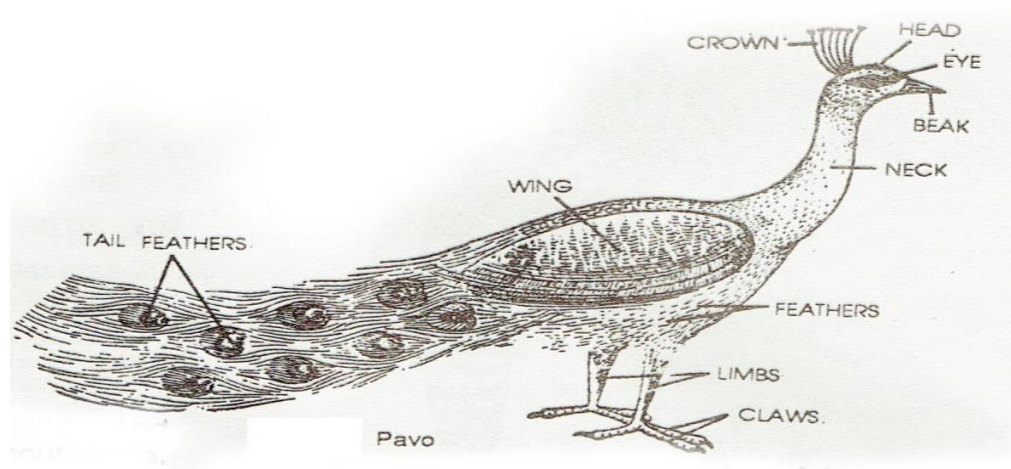


Fig 4.39 Pavo

1. It is inhabitant of shrubs, fields and forests and is found throughout India, Nepal and Ceylon.
2. It is commonly called 'Mor', 'Mayur', *peafowl*, or 'peacock' and is the national bird of India.
3. *Sexual dimorphism is conspicuous. Male is larger then female. It's body is covered by beautifully pigmented plumage. Plumage of neck is bright green with metallic shine. It's ornamented gorgeous long tail (about 1-2-.25 meters) is made up of exceptionally long upper tail coverts. Tail feathers are beautifully decorated with almost round,*

hollow, golden, blue and green ocell and patches. The head bears a crest made up of 24 bare shafted gold tipped feathers.

4. *In female plumage is mottled brown and the ornamental tail and crest on the head are absent.*
5. Bill is small and feet are adapted for fast running and for scratching the earth for finding worms.
6. The bird is *unable to fly well* and for long distances.
7. It is a *polygamous* bird and usually lives in a group of one cock and 4 to 5 hens.
8. It is oviparous and *makes nest on the ground.*
9. It feed on grains, insects, worms and reptiles i.e., like snakes and lizards.
10. It's call is loud and shrill. It sounds like '*may-awe*'.
11. The bird is considered a sign of immortality and is said to live for 100 years.
12. *It's flesh, tongue and brain have medicinal value.*

ORNITHORHINCHUS (Duck-Billed Platypus)

Classification

Phylum	-	Chordata
Class	-	Mammalia
Subclass	-	Prototheria
Order	-	Monotremata
Genus	-	Ornithorhynchus

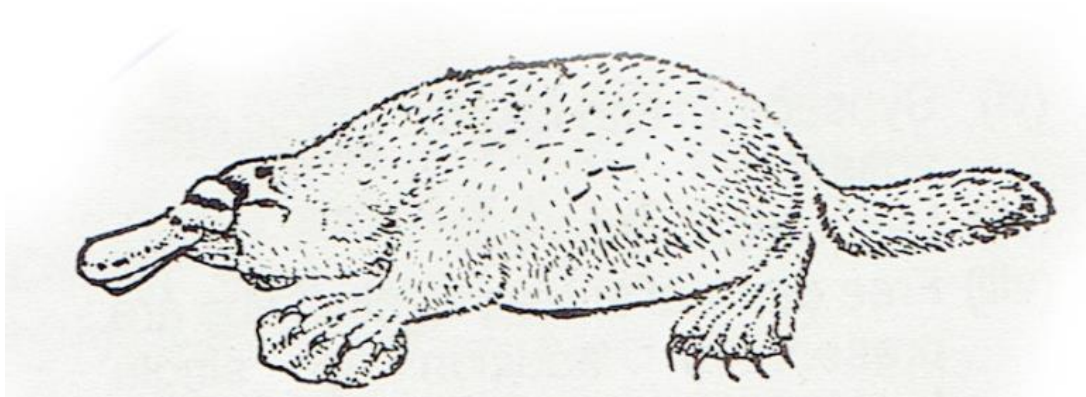

Fig 4.40 Ornithorhynchus

1. It is an aquatic, burrowing, nocturnal and carnivorous mammal ***found in the rivers of Australia and Tasmania*** and commonly called ‘Duck-billed platypus’.
2. Body is covered with soft, brown, water proof ***fur*** with ***Interspersed spines***.
3. Upper jaw forms a flattened, dorsally convex sensitive and edentulous ***bill lined with horny plates*** and covered with ***hairless rubber like skin***.
4. Two pairs of limbs. Each limb has 5 clawed and webbed digits. ***Web extends beyond the claws***.
5. Eyes are small and rudimentary and have nictitating membrane.
6. Sexual dimorphism is distinct. In males a sharp, stout, movable and hollow tarsal ***spur is present on the heel*** and is ***connected with the poison gland located in the thigh***.
7. ***Mammary glands without teats***.
8. It is oviparous. Female usually lays 2 eggs at a time in a nest of grass curled around them for incubation:

TACHYGLOSSUS (ECHIDNA)

Classification

Phylum	-	Chordata
Class	-	Mammalia
Subclass	-	Prototheria
Order	-	Monotremata
Genus	-	Tachyglossus



Fig 4.41. Tachyglossus

1. It is terrestrial, burrowing and nocturnal mammal ***found throughout Australia and change are Tasmania*** and is commonly called ‘Spiny ant eater’ or ‘Echidna’.
2. Long, narrow and gradually tapering body is covered all over with small, ***tough spines*** and ***coarse hair*** except on ventral side.
3. Head is produced into a long and tubular snout with terminal mouth.
4. ***Long protrusible tongue is sticky and bear horny serrations on upper surface.***
5. Teeth and tail absent and external ears inconspicuous.
6. Small eyes are very sensitive and without nictitating membrane.
7. ***Two pairs of small limbs with broad clawed feet. Second claw of each hind leg is long and curved to clean spines and is called ‘toilet claw’.***
8. Sexual dimorphism clearly visible. male bears a hollow tarsal spur on each hind leg which is connected to a ***poison gland*** present in the thigh.
9. They are oviparious and the ***females develop a temporary marsupium during breeding season and put their single egg (sometimes 2 or 3) in it to incubate. Egg shell is leathery.***
10. ***It exhibits gyaecomastism, i.e., males and females both possess functional mammary glands to feed’ young ones. Mammary glands are without teats.***
11. It feeds on ants and termites (insectivorous) .

BAT

Classification

Phylum	-	Chordata
Class	-	Mammalia
Subclass	-	Eutheria
Order	-	microchiroptera
Genus	-	Rhianolophus




Fig 4.42. *Rhianolophus*

1. It is a nocturnal, mainly insectivorous, gregarious or solitary mammal and commonly called 'bat' or 'chamgadar'.
2. Small or medium sized body is covered with steel grey brownish fur.
3. It flies with the help of patagia (wings) which are membranous, leathery lateral extensions of skin along the body, tail and limbs and are supported by elongated forelimbs and hind to fifth fingers. Only 1st finger is clawed.
4. Hind limbs are small, toes are clawed and tail and eyes small.
5. Teeth heterodont and thecodont with dental formula $1123/2123$.
6. External ears (pinnae) present and ears are provided with most advanced sonar or echo apparatus.
7. Vocal cords produce ultrasonic sound waves, which, after striking solid objects, rebound and are received by ears and help in guiding the animal during flight even in dark.
8. Mammary glands have distinct teats.

ERINACEUS OR HEMIECHINUS (PEACOCK)

Classification

Phylum	-	Chordata
Class	-	Mammalia
Subclass	-	Eutheria
Order	-	Insectivora
Genus	-	Erineaus or Hemiechinus
Species	-	Collaris




Fig 4.43 .Erineaus or Hemiechinus

1. It is a terrestrial and burrowi, nocturnal mammal which lives underand is found throughout India, Europe, Asia and North africa and is commonly knownas ‘Jahu chuha’ or hedgehog’.
2. Somewhat globular body is covered all over with numerous short, stiff and erectile spines intermingled with hair except on ventral surface. The spines can be erected on the approach of slightest danger and the animal can easily roll into a ball.
3. Small, stumpy and cylindrical tail is covered with scales.
4. Two pairs of small limbs have 5 clawed digits in each and are adapted for digging.
5. Head is produced into a pointed snout which bears small eyes.
6. ***Jaws bear thecodont and heterodont teeth. Dental formula 2133/2013.***
7. Mammary glands have definite teats.
8. It is omnivorous and feeds on insects, snails, young birds and snakes.
9. It is Immune to snake venom and may even kill vipers.

FUNAMBULUS

Classification

Phylum	-	Chordata
Class	-	Mammalia
Subclass	-	Eutheria
Order	-	Rodentia
Genus	-	Funambulus



Fig 4.44 .Funambulus

1. It is a very active diurnal and arboreal mammal found throughout the world except Australia. It is more common in warmer parts and is called 'squirrel' in English and 'Gilhari' in Hindi.
2. Body is covered with light grey fur and has 3 to 5 black and white longitudinal stripes along its back and its tail is bushy.
3. Head is produced into mustachioed snout and bears large eyes and large external ears which always remain erect.
4. Its two pairs of limbs have four distinct clawed digits in each.
5. Jaws bear heterodont and thecodont teeth. Incisors continue to grow throughout life and are used for gnawing. The diastemma is present because canines are absent.
6. *It is frugivorous and eat seeds, nuts and fruits.*

LION

Classification

Phylum	-	Chordata
Class	-	Mammalia
Subclass	-	Eutheria
Order	-	Carnivora
Genus	-	Panthera (Felis or leo)
Species	-	leo

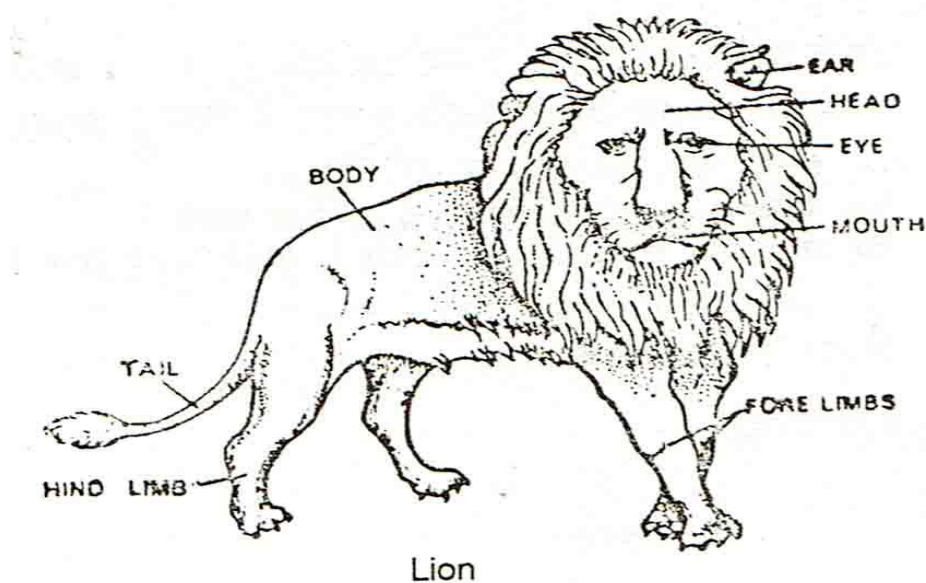


Fig 4.45 Panthera

1. It is an inhabitant of dense forests but not it is common in well protected sancturies especially in 'Gir forests' in Gujrat in India and in grasslands of Africa and South Western Asia.
2. It is commonly called 'Sher', 'Babbar sher' or lion'.
3. It is predatory and feeds on cattles, dear, bison, antelope and even on man. Body is covered with tawny **yellow fur**. It's skull is high and jaws are powerful.
4. Jaws bear heterodont and thecodont teeth. Canines are large strong and each

TIGER

Classification

Phylum	-	Chordata
Class	-	Mammalia
Subclass	-	Eutheria
Order	-	Carnivora
Genus	-	Panthera (Felis)
Species	-	tigris

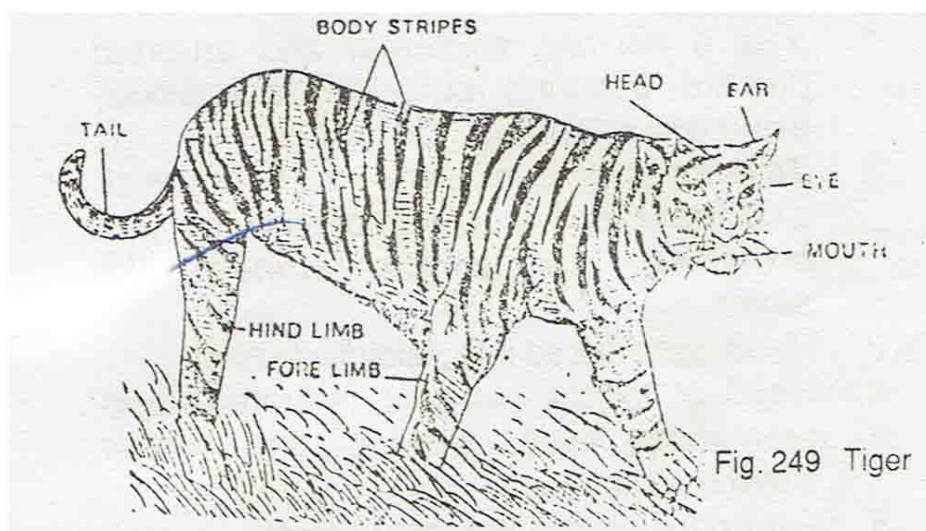


Fig 4.47 *Panthera (Felis)*

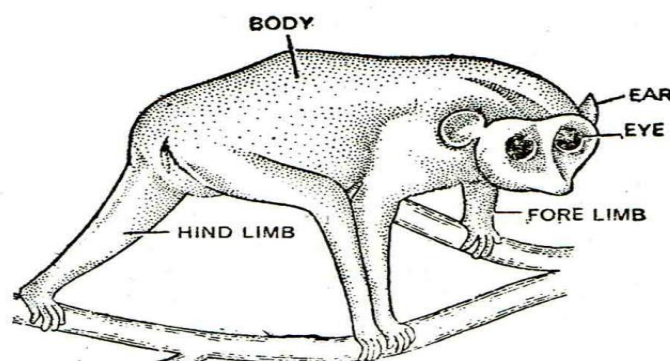
1. It is an inhabitant of dense forests but now it occurs in especially protected reserves in ***Kanha National Park (M.P.)*** and ***Corbett National Park (U.P.)*** and certain other national parks or sanctuaries of Bihar, Maharashtra, Karnataka and Andhra Pradesh.
2. ***It is the national animal of India since 1972 and is commonly called 'Cheetah' or 'tiger'.***
3. Body is covered with ***golden ye-llow fur*** with black vertical stripes and is a solitary animal.
4. It is carnivorous and feeds on cattle, deer, antelope, bison and other domestic hoofed animals and even on man.
5. It has high skull and large eyes and external ears.
6. Powerful jaws bear thecodont and heterodont teeth. Canines are well developed and pointed for tearing flesh. Two pairs of limbs bear powerful claws.
7. Since the feet have very soft and highly cushioned pads, It can move in forest without making any noise and thus without alarming the prey.
8. It is regarded to be the most cunning, ferocious, shrewd, intelligent and agile animal. It is a fast runner and chases its prey before killing. There is no sexual dimorphism.

LORIS

Classification

Phylum	-	Chordata
Class	-	Mammalia
Subclass	-	Eutheria
Order	-	

Genus



Loris

- Primata

- Loris

Fig 4.48 Loris

1. It is a solitary, nocturnal and arboreal primate occurring outside Madagaskar, especially in India and Sri Lanka.
2. *Taillenss* body is divisible into head, neck and trunk and is covered over by soft ***brownish fur which shines like silver.***
3. Head is produced into a pointed snout.
4. Head bears closely situated and prominent eyes making the vision ***binocular.***
5. External ears (pinnae) are conical.
6. One pair of external nostrils are present on the snout.
7. Jaws bear heterodont and thecodont teeth.
8. Two pairs of long pentadactyle limbs have claws in some fingers and flat nails on other fingers.
9. sexual dimorphism is present. ***In females transverse skin fold is present on the abdomen.***
10. It is a slow mover but often hangs upside down on tree branches.
11. They feed on fruits and small animals.

4.4 SUMMARY

The Animals are placed in the kingdom Animalia, which is further divide into phylum non-chordate and phylum chordates. The main characteristic of Phylum chordate is the presence of dorsal tubular nerve cord. Phylum chrodata divided into two groups Acrania (protochrodate) and Craniata (vertebrata). The group protochrodata includes the lowly organized members of phylum chrodata. The organisms which are included in group vertebrata show the presence of vertebral column. There are various methods to study the

members of these groups e.g specimen study etc. This unit includes the permanent slides of members of protochordates and chordata.

4.5 TERMINAL QUESTIONS AND ANSWERS

Q.1 Larva of Balanoglossus is

- (a) Tornaria
- (b) Muller's larva
- (c) Kentrogen larva
- (d) Tadpole

Ans. (a)

Q.2 Which of the following statements is true?

- (a) All chordates are vertebrates
- (b) All vertebrates are chordates
- (c) Nonchordates have a vertebral column
- (d) Invertebrates possess a tubular nerve cord

Ans. (b)

Q.3. In which of the following jaws are found

- (a) Herdmania
- (b) Fish
- (c) Petromyzon
- (d) Amphioxus

Ans. (b)

Q.4. The petromyzon belongs to

- (a) Chondrichthyes
- (b) Osteichthyes
- (c) Cyclostomata
- (d) Amphibia

Ans. ©

Q.5 . Herdmania belongs to which subphyla

- (a) Cephalochordata
- (b) Hemichordata
- (c) Urochordata
- (d) Protochordata

Ans. (c)

Q.6. The most important distinctive character of chordata is the presence of

- (a) Vertebral column
- (b) Hairy skin

- (c) Notochord
 - (d) All the above
- Ans. ©

Q.7. The animal who possesses notochord throughout life is

- (a) Fish
- (b) Amphioxus
- (c) Bird
- (d) Snake

Ans. (b)

Q.8. Animals which show viviparity include

- (a) Whales
- (b) Bony fishes
- (c) Turtles
- (d) Running birds

Ans. (a)

Q.9. Which of the following are Anamniotes?

- (a) Chondrichthyes, Osteichthyes, Amphibia
- (b) Reptilia, Aves, Amphibia
- (c) Amphibia, Aves, Mammals
- (d) Reptilia, Mammals, Aves

Ans. (a)

Q.10 . Balanoglossus belongs to

- (a) Hemichordata
- (b) Cephalochordata
- (c) Urochordata
- (d) Cyclostomata

Ans. (a)

Q.11. Which of the following sets of animals belong to class cyclostomata?

- (a) Herdmania and petromyzon
- (b) Petromyzone and myxine
- (c) Amphioxus and balanoglossus
- (d) Herdmania and myxine

Ans. (b)

Q.12. Retrogressive metamorphosis is found in

- (a) Balanoglossus
- (b) Branchiostoma
- (c) Herdmania
- (d) All of these

Ans. ©

Q.13. Which of the following is the smallest taxonomic group of animals having a cranium, vertebral column, ventral heart, pulmonary respiration and two pairs of limbs?

- (a) Gnathostomata
- (b) Tetrapoda
- (c) Vertebrata
- (d) Chordata

Ans. (b)

Q. 14. In which of the following notochord is absent

- (a) Adult Herdmania and Balanoglossus
- (b) Adult Herdmania and adult Branchiostoma
- (c) Larva of Herdmania and Branchiostoma
- (d) Larva of Herdmania and Balanoglossus

Ans. (a)

Q.15. Lampreys are

- (a) Jawless fishes
- (b) Jawless primitive vertebrates
- (c) Jawed fishes
- (d) Fishes with a spherical mouth

Ans. (b)

Q.16. Which animal is ‘‘Non-chordate-prot chordata’’?

- (a) Herdmania
- (b) Balanoglossus
- (c) Branchiostoma
- (d) Botryllus

Ans. (b)

Q.17. Vertebral column is derived from

- (a) Notochord
- (b) Dorsal nerve cord
- (c) Ventral nerve cord
- (d) Outgrowth of cranium

Ans. (a)

Q.18. Agnatha includes

- (a) Hag fishes
- (b) Fishes
- (c) Jelly fishes
- (d) Flying fishes

Ans. (a)

REFERENCES

6. A manual of Practical Zoology Chordate by P.S. Verma.

7. Kotpal, R.L 2012 Vertbrate, Rastogi publication Merruth.

UNIT 5:- EXERCISES ON DEVELOPMENTAL BIOLOGY & ENDOCRINOLOGY

5.1 Objectives

5.2 Introduction

5.3 Study of eggs from collected/preserved material

5.4 Study of development of frog, chick through models/charts/slides

5.5 Study of chick embryos from 16-18hrs, 24-28 hrs, 33-36 hrs, 42- 72hrs, of development.(whole mount models, charts)

5.6 Study of development of chick by window preparation

5.7 Endocrine glands of rat, insect (location through models, charts)

5.8 Endocrine disorders (photographs)

5.9 Summary

5.10 Terminal questions and answers

5.1 OBJECTIVES

We will learn about:

- Study of eggs from collected/preserved material
- Study of development of frog, chick through models/charts/slides

- Study of chick embryos from 16-18hrs, 24-28 hrs, 33-36 hrs, 42- 72hrs, of development.(whole mount models, charts)
- Study of development of chick by window preparation
- Endocrine glands of rat, insect (location through models, charts)
- Endocrine disorders (photographs)

5.2 INTRODUCTION

Developmental biology is the science that investigates how a variety of interacting processes generate an organism's heterogeneous shapes, size, and structural features that arise on the trajectory from embryo to adult, or more generally throughout a life cycle. It represents an exemplary area of contemporary experimental biology that focuses on phenomena that have puzzled natural philosophers and scientists for more than two millennia. Philosophers of biology have shown interest in developmental biology due to the potential relevance of development for understanding evolution, the theme of reductionism in genetic explanations, and via increased attention to the details of particular research programs, such as stem cell biology. Developmental biology displays a rich array of material and conceptual practices that can be analyzed to better understand the scientific reasoning exhibited in experimental life science. This entry briefly reviews some central phenomena of ontogeny and then explores four domains that represent some of the import and promise of conceptual reflection on the epistemology of developmental biology.

Endocrinology is the study of hormones. Hormones are essential for our every-day survival. They control our temperature, sleep, mood, stress, growth and more. Endocrinology is a branch of biology and medicine dealing with the endocrine system, its diseases, and its specific secretions known as hormones. It is also concerned with the integration of developmental events proliferation, growth, and differentiation, and the psychological or behavioral activities of metabolism, growth and development, tissue function, sleep, digestion, respiration, excretion, mood, stress, lactation, movement, reproduction, and sensory perception caused by hormones. Specializations include behavioral endocrinology and comparative endocrinology.

The endocrine system consists of several glands, all in different parts of the body, which secrete hormones directly into the blood rather than into a duct system. Therefore, endocrine glands are regarded as ductless glands. Hormones have many different functions and modes

of action; one hormone may have several effects on different target organs, and, conversely, one target organ may be affected by more than one hormone.

5.3 STUDY OF EGGS FROM COLLECTED/PRESERVED MATERIAL

TYPES OF EGGS

For the embryo to develop inside a fertilized egg nutrition is needed. The amount of food needed varies for different organisms. It normally depends on the duration of development. Food is provided in the form of **yolk**. It may be '**fatty yolk**' or '**protein yolk**'. It is provided by the ovary during differentiation of the egg. Due to accumulation of yolk a maturing egg rapidly increases in size. In amphibian eggs yolk occurs in the form of large granules, called **yolk platelets**. Chemically, the yolk platelets contain two main pro-tenacious substances namely **phosvitin** and **lipovitellin**.

The amount of yolk is an important determining factor for further patterns in embryological stages. The amount of yolk influences cleavage and gastrulating methods. The eggs can be classified based on amount and distribution of yolk.

AMOUNT OF YOLK AND EGG TYPES:

In certain animals the developmental stages are not very elaborate. The final 'young one' born may be very simple in structure and organization. Such conditions remain in animals like *Hydra*, *Sea urchin*, *Amphioxus* and **Placental mammals**. In the eggs of such organisms due to brevity of the growth period the amount of yolk is much reduced. Such eggs are said to be **Microlecithal** or **oligolecithal**.

In certain other animals the eggs need to release young ones in a more self supportive condition. Hence for such eggs the amount of yolk is considerable in quantity. Such eggs with moderate amount of yolk are called **meso-lecithal eggs**. Such eggs are produced by annelid worms, molluscs and amphibians.

In some animals the growth and differentiation of the embryo is much more elaborate. The growth period is sufficiently long. Hence for supporting the embryo in development the eggs contain large quantity of yolk. Such eggs are termed as **Megalecithal** or **Macrolecithal eggs**. The eggs of reptiles and birds are considered as macrolecithal. Further these eggs are covered

by a calcareous shell. It is a protective structure for laying the eggs on lands. Such eggs are called **cleidoic eggs** or land eggs.

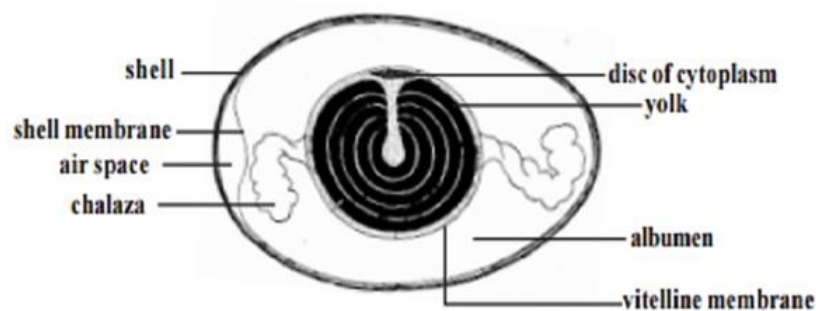


Fig.5.1 Hen's Egg

DISTRIBUTION OF YOLK

The pattern of cleavage and the consequent gastrulation processes are affected by the distribution of yolk within the egg. According to the pattern of dispersal of yolk the following egg types had been identified.

1. HOMOLECITHAL OR ISOLECITHAL EGGS

Eggs of this type have the yolk disbursed in the entire cytoplasm. The distribution is somewhat uniform in animal, vegetal poles and the equatorial region. In such eggs the cleavage will be deeper and may bisect the eggs connecting the two poles. All microlecithal eggs have this nature.

2. TELOLECITHAL EGGS

All eggs have polarity. In polarity, the eggs have an innate nature for to be differentiated into upper animal pole and lower vegetal pole. The polar nature is mainly due to the denser material in the cytoplasm, namely yolk. The yolk in the egg will normally get concentrated in the vegetal pole. The cytoplasm with the nucleus will occupy the upper animal pole. The extent of vegetal pole is determined by the amount of yolk. Thus the eggs having a polarized distribution of yolk in the cytoplasm are referred to as telolecithal eggs. Mesolecithal and macrolecithal eggs remain as telolecithal eggs.

3. CENTROLECITHAL EGGS

An egg need not be spherical always. In invertebrate animals oval shaped eggs are seen. The pattern of cleavage and further gastrulation also deviate from that of the vertebrates. In **insects** the eggs are oval in shape and the yolk remains in the centre of the egg. However, the eggs of echinoderms are similar to that of the vertebrates.

5.4 STUDY OF DEVELOPMENT OF FROG, CHICK THROUGH MODELS/CHARTS/SLIDES:

- When sperm fertilize the egg, streaming movements are set up in the egg and these results in distribution of materials. So that three regions can be seen, the upper animal hemisphere (pole) which is pigmented and lower white vegetal pole. Between the two hemispheres, there is a small are with no pigment called grey crescent.

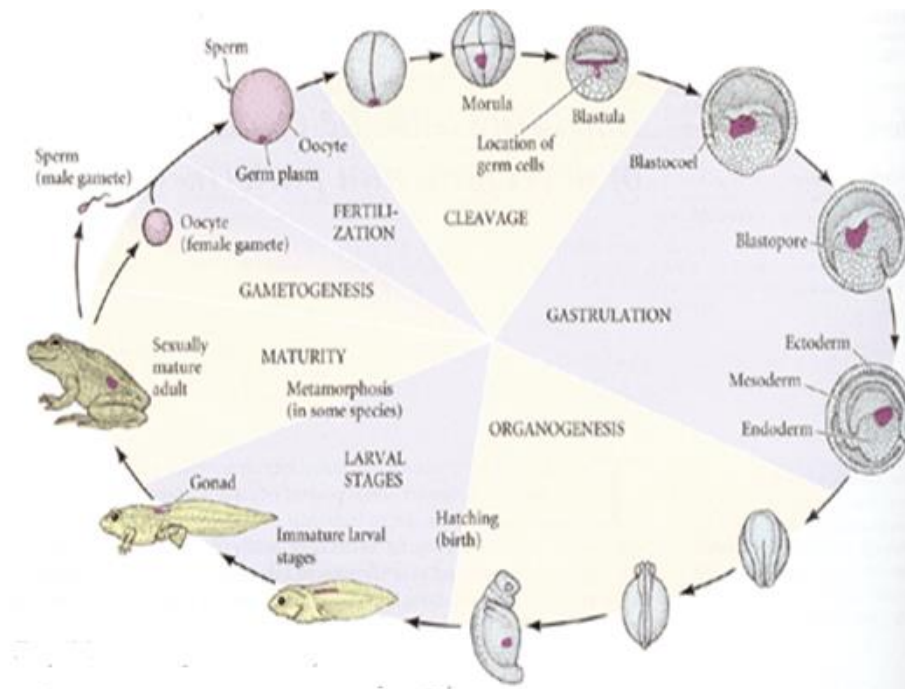


Fig.5.2 Developmental history of a Frog. The Egg from Fertilization through hatching are known collectively Embryogenesis

CLEAVAGE OR SEGMENTATION:

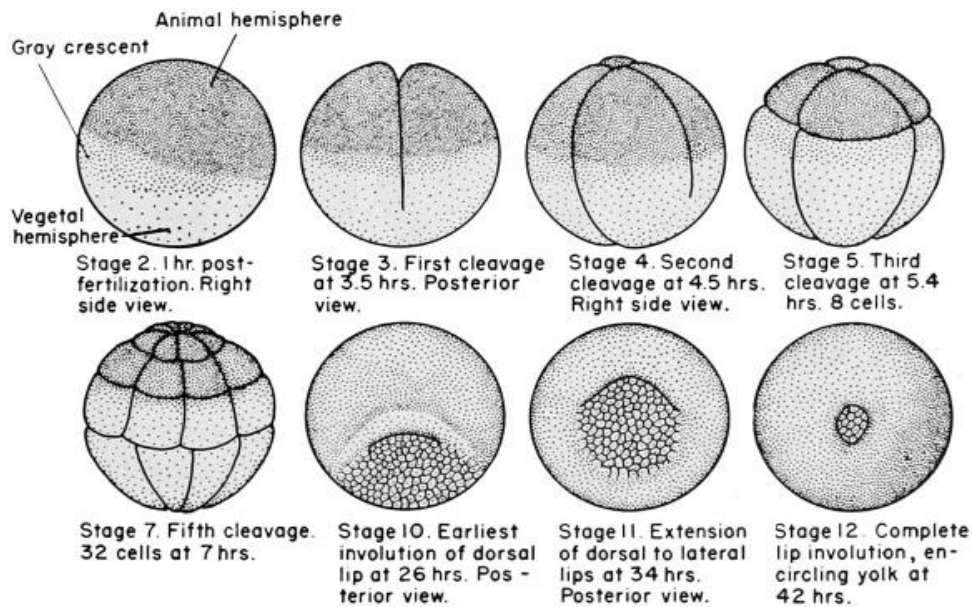


Fig.5.3 Cleavage or segmentation:

- 2-3 hours after fertilization, the zygote begins to divide. The repeated division in the successive fashion is known as **cleavage or segmentation**.
- Division is mitotic
- The cleavage begins as a small depression at animal pole and gradually extends surrounding the zygote, dividing into two cells.
- The divisions are **holoblastic** and complete
- First cleavage is vertical; two celled stage
- Second cleavage is also vertical but right angle to the first one; forms 4 celled stage
- The cells are known as blastomere.
- Third cleavage is horizontal but above the equatorial line forming unequal size cells. The upper 4 cells toward animal pole are small and pigmented known as micromeres or epiblast. The lower 4 large yolk laden cells are known as megameres or hypoblast.
- Fourth and fifth cleavage is also vertical forming 16 celled zygote. This division is followed by two horizontal cleavages, one toward animal pole and other toward vegetal pole, resulting in 32 celled stages.

MORULA (MULBERRY SHAPE STAGE):

- As the result of repeated and irregular cleavage, ball of cells is formed known as morula stage.
- One hemisphere of morula is composed of large number of small black and yolkless cells known as **micromeres** and other hemisphere is composed of fewer numbers of large white and yolk laden cells known as **megameres**.

BLASTULA STAGE:

- The micromeres dives more rapidly than megameres which results in formation of small fluid filled cavity known as **Blastocoel or segmentation cavity**.
- Blastocoel bearing stage is called **Blastula**
- The floor of blastocoel is composed of layer of yolk laden megameres while the roof is composed of micromeres.
- In this stage early Presumptive areas can be differentiated by staining technique.
- The entire animal pole of blastula represents the presumptive ectoderm, which is further divided into presumptive epidermis and presumptive neural plate
- A small area near vegetal pole is presumptive notocord
- Close to presumptive notochord there is a grey crescent region which is the presumptive mesoderm
- The remaining vegetal region is presumptive endoderm

GASTRULA STAGE:

- Gastrula is the two layered embryo stage formed by migration and rearrangement of cells of blastula. The process of formation of gastrula is called **gastrulation**.
- Gastrulation involves some critical changes in the blastula such as- differentiation of cells, transformation from monoblastic to **diploblastic layer**, formation of **three primary germ layers**.
- Gastrulation completes in following steps.

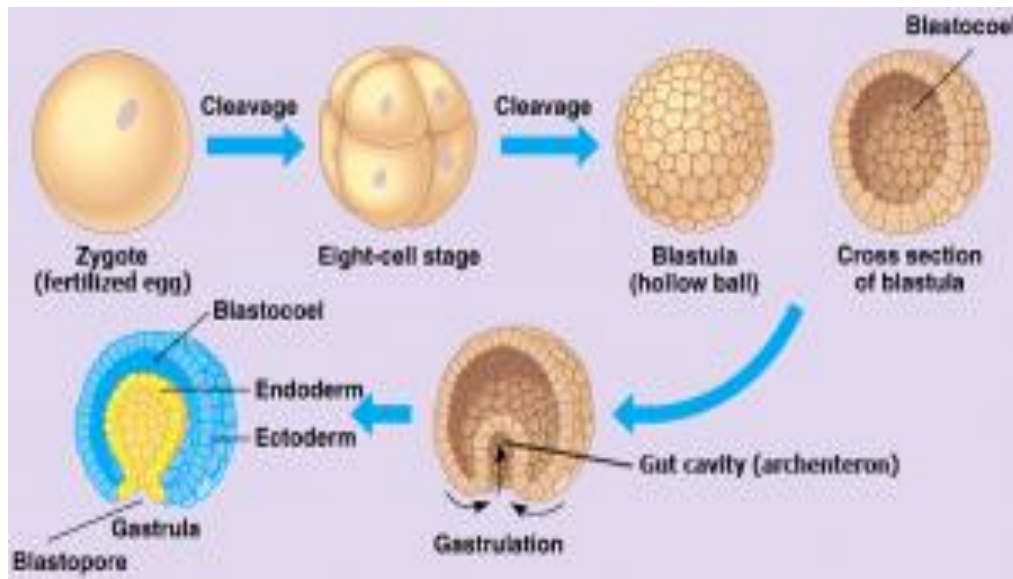


Fig.5.4 stages of gastrulation

1. EPIBOLY:

- In this step, micromeres at animal pole divide more repeatedly and rapidly enclosing the megameres except in the region of yolk plug. This overgrowth or spreading of micromere cells is known as Epiboly.

2. EMBOLY OR INTUCKING (INVAGINATION):

- In this step, small groove appears due to invagination of megameres near grey crescent region. The invagination gradually grows inward causing migration of cells.
- This stage is also known as Yolk plug stage.
- The narrowing of blastopore exerts pressure on underlying yolk laden megameres, result in protruding of some megameres cells as yolk plug.
- Contraction of lips of blastopore: contraction of lips from all side occurs so that blastopore become smaller and narrower.
- As invagination progresses archenteron increases in size and the blastocoel become reduced and finally obliterated.
- This groove is the beginning of archenteron and its anterior opening is called blastopore. The blastopore is guided by anterior margin called dorsal lip and backward projecting lateral lip.

3. INVOLUTION:

- due to increase in size of archenteron as well as formation of yolk plug, there is rapid migration of presumptive areas within the embryo occurs. This movement of the presumptive areas is known as involution.
- Rotation of gastrula: gastrulation causes shift in the center of gravity of the embryo. In the blastula stage, embryo floats with animal pole upward. But formation of archenteron causes the embryo to rotate within the vitelline membrane so that blastopore comes near the vegetal pole.
- Gastrulation causes following changes-
 - i) Blastopore is presumptive gut
 - ii) Roof of archenteron is chord mesoderm
 - iii) Floor of archenteron is endoderm

4. FORMATION OF THREE GERM LAYER:

- The three layers are ectoderm; mesoderm and endoderm are known as primary germ layer. They are also called as germinal layers because entire organs and body are derived from this layer.

Fate of germ layers

1. **Ectoderm:** epidermis, cutaneous glands, eye lens, cornea, retina, conjunctiva, central nervous system (brain and spinal cord), pineal gland, pituitary gland, enamel of teeth etc are derived from primary ectoderm layer.
2. **Mesoderm:** notochord, pericardium, peritoneum, muscles, skeleton, connective tissues- blood, lymph, adipose tissue, dermis of skin, visceral organs, is derived from primary mesoderm layer.
3. **Endoderm:** epithelium of digestive tract, respiratory tracts, Eustachian tubes, gastric and intestinal glands, liver, pancreas, bile and pancreatic ducts, lining of urinary bladder are derived from primary endoderm layer.

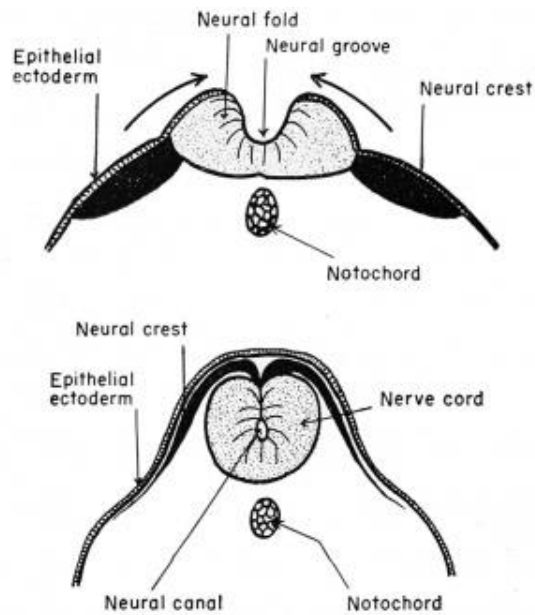


Fig.5.5 process of formation of nerve cord

NEURULATION:

- It is the process of formation of neural tube or nerve cord.
- At the end of gastrulation the prospective neural plate comes to lie along the length of mid-dorsal region. Neural plate later forms central nervous system including brain and spinal cord.
- A pair of longitudinal ridges called neural folds appears along the edges of neural plate, which meet in a semicircle anteriorly.
- The neural folds increase in height and comes closer together the median line where they fuse to form neural tube, enclosing the neural canal.
- The closure of neural tube begins just in front of mid-region and proceeds both anteriorly and posteriorly
- At the front end neural tube remains open for short time through neuropore. But posteriorly it communicates for some time with archenteron by neurenteric canal.
- Finally closed tubular neural tube is formed which later form brain and spinal cord.

NOTOGENESIS:

- It is the process of formation of notochord
- The meso-endodermal cell lying in mid dorsal region of roof of archenteron separates from mesoderm layer
- These cells become solid cylinder rod like structure along the median line and parallel to and just below the neural tube lies called notochord.
- Later, notochord sheath develop around the notochord
- In adult notochord is replaced by vertebral column.

FORMATION OF COELOM:

- Coelom is the body cavity and it is mesodermal in origin
- Mesodermal layer split into two thin layers-outer somatic or (parietal) layer and inner visceral or (splanchnic) layer.
- Between these two layers a cavity is formed called splanchnocoel, which extend downward and continues to the outside below the gut
- Outer somatic layer combines with ectoderm to form body wall (somatopleure)
- Inner visceral layer unites with endoderm to form gut wall (splanchnopleure)
- Splanchnocoel continues to form coelom or body cavity between gut wall and body wall.
- The coelom is known as Schizocoel coelom.

5.5 STUDY Of CHICK EMBRYOS FROM 16-18hrs, 24-28 Hrs, 33-36 Hrs, 42- 72hrs, OF DEVELOPMENT. (WHOLE MOUNT MODELS, CHARTS)

1. Chick: M. 4 Hours of Incubation:

1. Four hours after incubation of the egg shows differentiation of the blastodisc into area pellucida and area opaca. (Fig. 5.6).

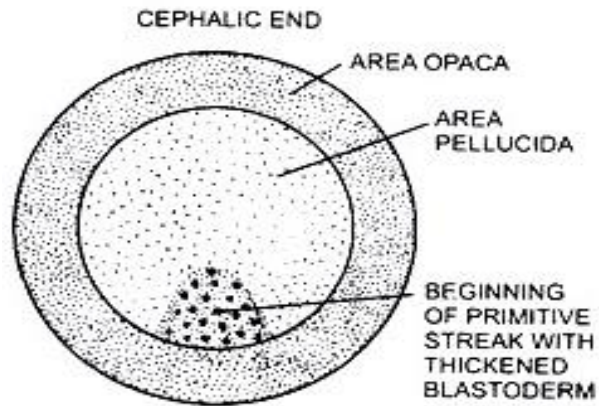


Fig.5.6 Chick Embryo, 4 hours of Incubation

2. One quadrant of area pelluciada becomes thickened, which marks the future caudal end of embryo.
3. After 7 to 8 hours, the thickening becomes more elongated and represented start of primitive streak.

2. Chick: W.M. 16 Hours Embryo:

Comments:

1. 16 hours after incubation the primitive streak becomes so distinct that embryos are characterized as being in primitive streak stage. (Fig.5.7).

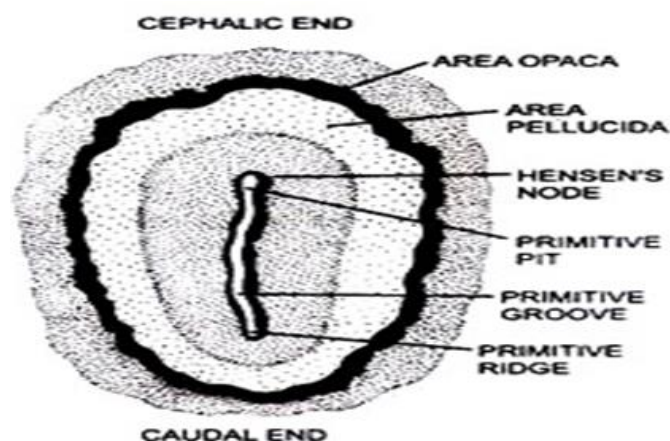


Fig.5.7 Chick Embryo 16 hours of incubation

2. In fixed and stained slide, w.m. is composed of central furrow, called as primitive groove lined by thickened primitive ridges.

3. at the cephalic end of the primitive streak, closely-packed cells form thickened area, called as Hensen's node. Part of area pellucida adjacent to the primitive streak shows increased thickness and forms embryonic elliptical shape.

4. Area pellucida assumes elliptical shape.

5. Elongated primitive streak represents long axis of future embryonic body.

6. Caudal end of the streak is that which lies close to the area opaca.

3. W.M. 18 Hours Chick Embryo:

1. It is a W.M. of 18 hours stage of chick embryo.

2. At this stage the dark peripheral area opaca and central translucent area pellucida are distinctly visible.

3. In the anterior part is present the pro-amnion, which is a small and comparatively more translucent region of area pellucida and is characterised by the absence of mesoderm.

4. In the middle of area pellucida, in the posterior half, runs a primitive streak having a primitive groove through its centre. The primitive groove is being bound by primitive folds.

5. In the anterior half of area pellucida, in the middle, runs a neural groove bound by neural folds.

6. The primitive streak and neural groove is separated by a thickening-the Hensen's node having a small depression in the centre-the Hensen's pit.

7. The primitive streak gives rise to an out-growth, the notochord immediately below the primitive groove.

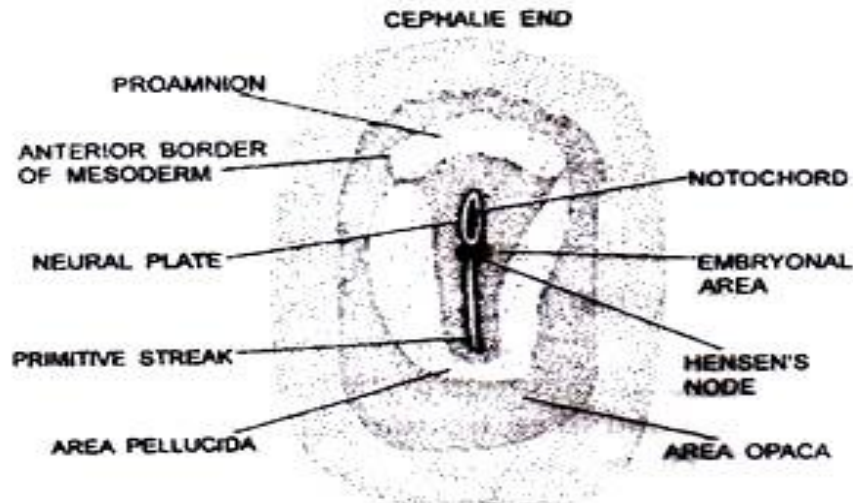


Fig. 17.3. W.M. of 18 Hr embryo of chick

Fig.5.8 W.M. of 21 Hours Chick Embryo

4. W.M. of 21 Hours Chick Embryo:

1. It is a W.M. of 21 hours chick embryo.
2. At this stage the dark peripheral area opaca and central translucent and colourless area pellucida are distinctly visible.
3. In the anterior part are present the pro-amnion, which is a small and comparatively more translucent region of area pellucida and is characterised by the absence of mesoderm.
4. In the middle of area pellucida, in the posterior half, runs a primitive streak having a primitive groove through its centre. The primitive groove is being bound by primitive folds.
5. In the anterior half of area pellucida, in the middle, runs a neural groove bound by neural folds.
6. The primitive streak and neural groove are separated by a thickening, the Hensen's nod having a small depression in the centre of the Hensen's pit.
7. The primitive streak gives rise to a small outgrowth, the notochord immediately below the primitive groove and to mesoderm on either side.
8. At this stage embryonic and extra embryonic regions have also become distinguished in the area pellucida.

9. In the anterior most part the ectoderm has given rise to head fold, which is a pocket-like extension of neural folds.

10. With the ectoderm the underlying endoderm is also transformed into a pocket-like structure the -foregut.

11. The proambion is comparatively reduced in size.

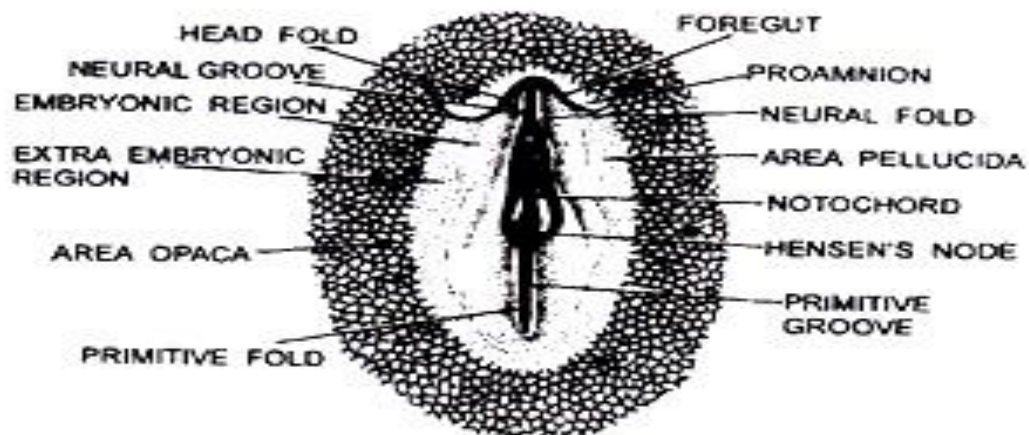


Fig. 17.4. W.M. of 21 hour chick embryo.

Fig.5.9 W.M. of 24 Hours or 4 Pairs of Somites Stage of Chick Embryo:

5. W.M. of 24 Hours or 4 Pairs of Somites Stage of Chick Embryo:

1. It is a W.M. of 24 hours 4 pairs of somites stage of chick embryo.
2. At this stage the dark peripheral area opaca and central translucent and colourless area pellucida are distinctly visible.
3. In the anterior part is present the proamnion, which is a small and comparatively more translucent region of area pellucida and is characterised by the absence of mesoderm.
4. In the middle of area pellucida, in its posterior half runs a primitive streak with a primitive groove in its centre. The primitive groove is bound by primitive folds.
5. In the anterior half of area pellucida, in the middle, runs the neural groove bound by neural folds.
6. The primitive streak and neural groove are separated by Hensen's node having a small depression in the centre-the Hensen's pit.

7. Immediately below the primitive groove the primitive streak gives rise to a small out-growth, the notochord and on either side to mesoderm.
8. In the area pellucida embryonic and extra embryonic regions also become distinguished.
9. In the anterior- most part the ectoderm has given rise to head fold, which is a pocket-like extension of neural folds. The underlying endoderm is also transformed into a pocket-like foregut. The proamnion is greatly reduced.
10. In front of Hensen's node the mesoderm of embryonic area differentiated into 3-4 pairs of mesodermal somites.
11. The neural canal, in the region of head fold, gives rise to forebrain.
12. The foregut extends on either side into an amino-cardiac vesicle.

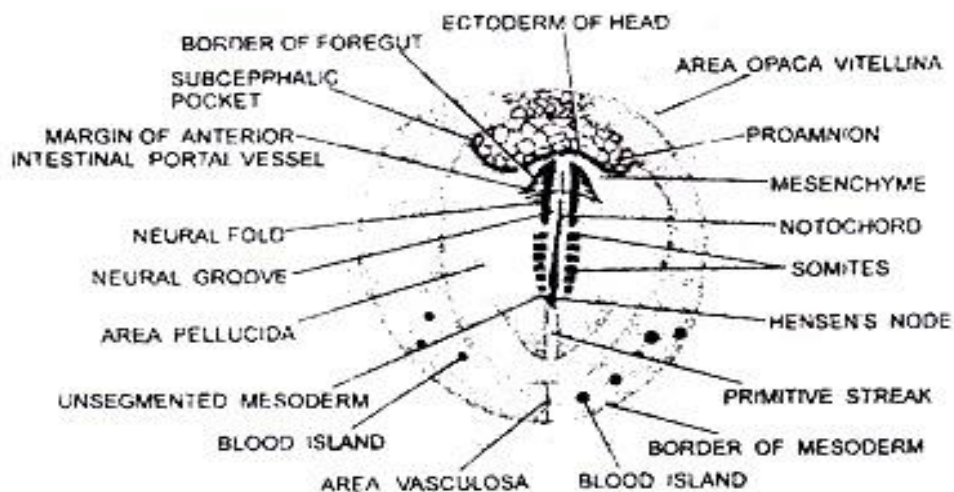


Fig. 17.5. W.M. 24 hours chick embryo.

Fig .5.10 WM of 30 hours

6. W.M. of 30 Hours of 8-10 Pairs of Somites Chick Embryo:

1. It is W.M. of 30 hours of chick embryo or 8-10 pairs of somite stage of chick embryo.
2. At this stage the dark peripheral area opaca and central translucent and clourless area pellucida are distinctly visible.
3. In the anterior part is present the proamnion, which is a small and comparatively more translucent region of area pellucida and is characterised by the absence of mesoderm.

4. In the middle of area pellucida, in the posterior half, runs a primitive streak with a primitive groove running through its centre. The primitive groove is bound by primitive folds.
5. In the anterior half of area pellucida, in the middle, runs the neural groove bound by neural folds.
6. The primitive streak and neural groove are separated by Hensen's node having a small Hensen's pit in the centre.
7. Immediately below primitive groove the primitive streak gives rise to the notochord and on either side to mesoderm.
8. At this stage embryonic and extra embryonic regions have also become distinguished in the area pellucida.
9. In the anterior-most part, the ectoderm has given rise to head fold which is a pocket like extension of neural folds. The underlying endoderm has transformed into pocket like foregut. The proamnion is reduced.
10. The mesoderm, in front of Hensen's node, has given rise to 8-10 pairs of somites.
11. In the region of head fold the anterior part of neural canal has given rise to a distinct fore brain.
12. The foregut and cardiac vesicles are sufficiently developed.
13. The extra embryonic area has grown in size.

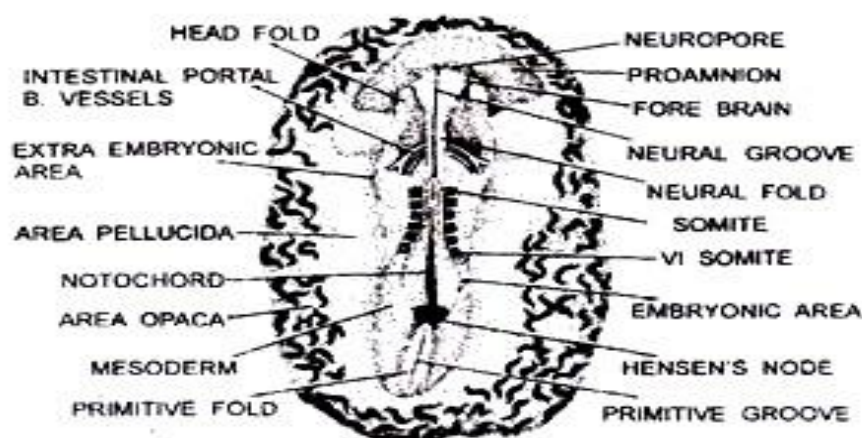


Fig. 17.6. W.M. of 30 hr chick embryo (8-10 somies)

8. W. M. of 33 Hour Chick Embryo of 11-12 Pairs Somites:

1. It is W.M. of 33 hours chick embryo.
2. At this stage the dark peripheral area opaca and central translucent area pellucida are not distinctly visible.
3. The primitive streak has been comparatively reduced because of great lengthening of neural canal and neural folds.
4. The extra embryonic area has grown in size.
5. The mesoderm, in front of Hensen's node, has given rise to 11-12 pairs of somites.
6. The foregut and cardiac vesicles are sufficiently developed.
7. The brain is differentiated into fore brain, mid- brain and hind brain.
8. The area opaca has changed into area vasculosa.
9. Proamnion has disappeared.
10. Anterior omphalomesenteric vein has developed.

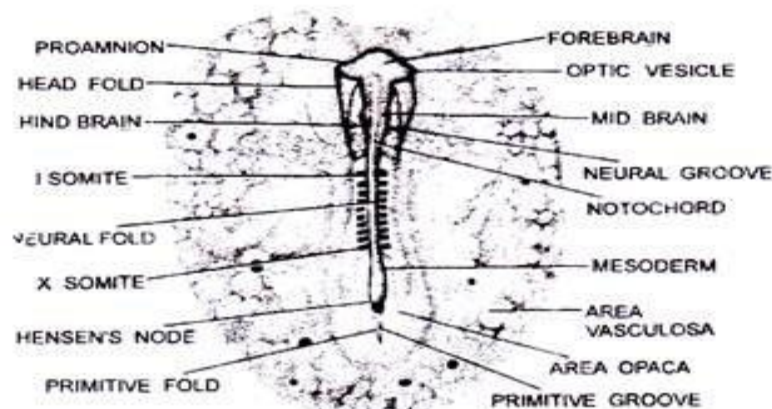


Fig. 17.7. W.M. of 33 hr (11-somies) chick embryo.

8. W.M. of Chick Embryo of 13-14 Pairs Somites or 36 Hours:

1. It is W.M. of 36 hours chick embryo.

2. At this stage the dark peripheral area opaca and central translucent and colourless area pellucida are not visible.
3. The extra embryonic area has grown in size.
4. The primitive streak is comparatively reduced because of great lengthening of neural canal and neural folds. The notochord has extended from behind the brain up to the end of body.
5. The mesoderm, in front of Hensen's node, has given rise to 13-14 pairs of somites.
6. The brain is differentiated into fore brain, mid brain and hind brain.
7. In the fore brain region optic vesicles and in the hind brain region optic vesicles have developed.
8. The area opaca has changed into area vasculosa.
9. Proamnion has disappeared.
10. Anterior omphalomesenteric vein and vitelline artery have developed.
11. The cardiac vesicle has given rise to heart.

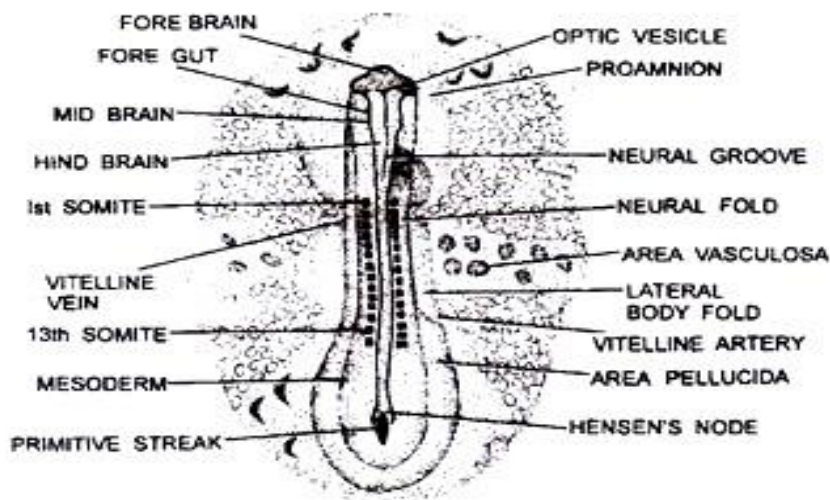


Fig. 17.8. W.M. of 36 hr (14 somits) chick embryo

9. W.M. of 48 Hours Chick Embryo of 26-28 Pairs of Somites:

1. It is W.M. of 48 hours chick embryo.
2. At this stage the area opaca and area pellucida are not visible.

3. The extra embryonic area has grown in size.
4. Primitive streak has disappeared.
5. The mesoderm, in front of Hensen's node, has given rise to 26-28 pairs of somites.
6. The brain has differentiated into telencephalon, prosencephalon, mesencephalon, metencephalon and myelencephalon.
7. The heart has been differentiated into ventricle and atrium. Sinus venosus and truncus arteriosus have also started developing.
8. The eye has been differentiated into optic cup and lens and optic vesicle has also developed sufficiently.
9. The head region has curved on right side due to cranial flexion.
10. Three pharyngeal gill-slits have also been differentiated.
11. Behind Hensen's node a tail bud has also developed.
12. Lateral amniotic folds, anterior omphalomesenteric vein and vitelline artery have appeared.

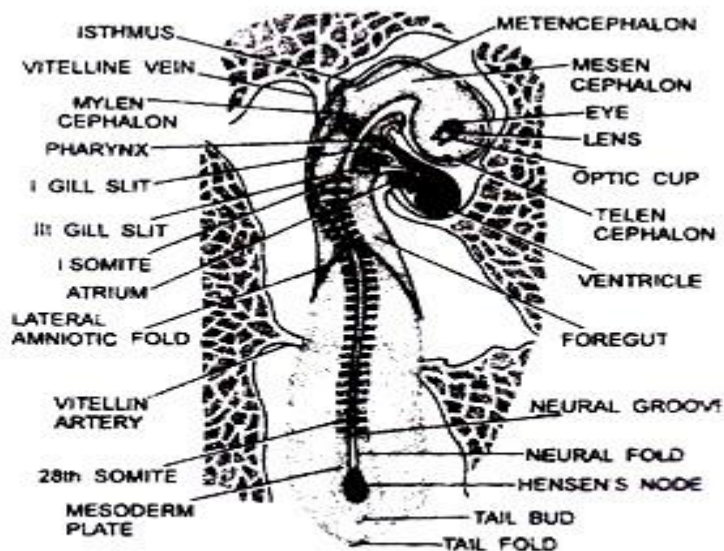


Fig. 17.9. W.M. of 48 hr (27 pairs somites) chick embryo.

10. W.M. of 72 Hours or 36 Pairs of Somites Stage of Chick Embryo:

1. It is W.M. of 72 hours chick embryo.
2. At this stage area opaca and area pellucida are not visible.

3. The extra embryonic area has grown in size.
4. Primitive streak has disappeared.
5. The mesoderm, in front of Hensen's node, has given rise to 36 pairs of somites.
6. The brain has differentiated into telencephalon, mesencephalon, metencephalon and myelencephalon.
7. The heart has been differentiated into ventricle and atrium.
8. The eye has differentiated into optic cup and lens and optic vesicle has also developed sufficiently.
9. The head region has bent on right side due to cranial flexion.
10. Four pairs of gill-slits have been differentiated.
11. Tail bud is greatly developed and has given rise to allantoic stalk and tail.
12. Lateral amniotic folds, vitelline artery and anterior omphalomesenteric vein have developed.
13. In the middle region a pair of fore limb buds and in front of tail a pair of hind limb buds have developed, which will give rise to fore and hind limbs.
14. Olfactory pit, visceral arches, amnion, allantois and amniotic cavity have also developed.

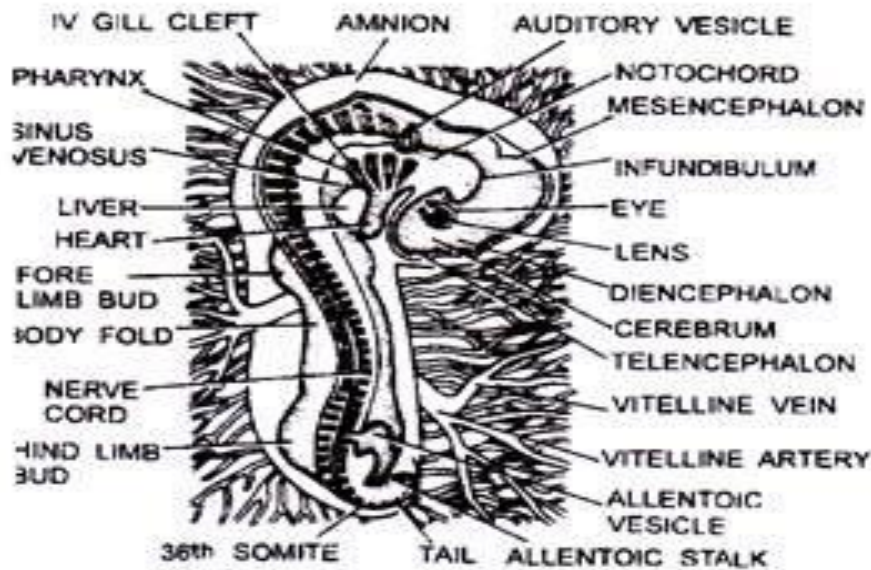


Fig. 17.10. W.M. of 72 hr (36 pairs somites) chick embryo

11. W.M. of 96 Hours Chick Embryo:

1. In the chick embryo of 96-hours of incubation, the entire body has been turned through 90 degree and the embryo lies with its left side on the yolk.
2. At the end of 96 hours the body folds have undercut the embryo so that it remains attached to the yolk only by a slender stalk.
3. The yolk salk soon become enclogated, allowing the embryo to become first straight in the mid-dorsal region and then convex dorsally.
4. The progressive increase in the cranial, cervical, dorsal and caudal flexures results in the bending of the embryo on itself so that its originally straight long axis becomes C-shaped and its head and tail lie close together.
5. Optic cup shows the more developed lens.

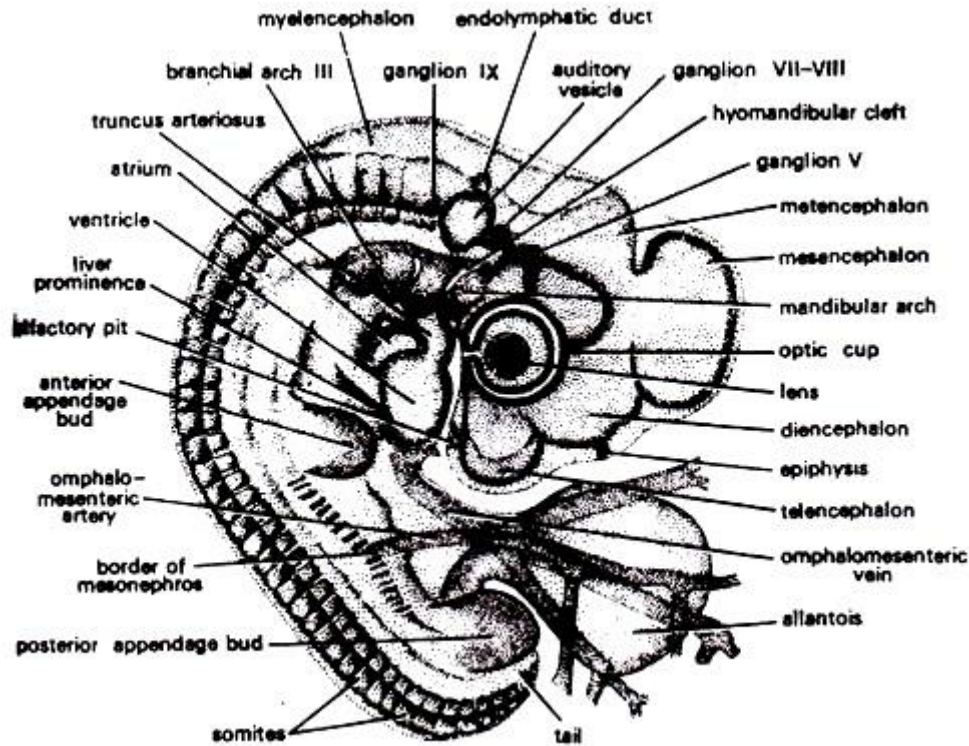


Fig. Chick embryo-96 hours (Whole mount).

6. Endo-lymphatic duct arises from the auditory vesicle.
7. Visceral arches have become very much thickened.
8. Appendage buds increase rapidly in size and become elongated.
9. The number of somites increases to 41 pairs.
10. Allantois has also appeared.
11. Omphalomesenteric artery and omphalomesenteric vein are also developed.

5.6 Study of development of chick by window preparation

In this method, the egg rests on its side and a small window is cut in the shell. After the experimental procedure, the shell is used to cover the egg for the duration of its development.

1. Remove eggs from incubator

Maintain at 37°C with relative humidity set above 60%.

- Remove the eggs; turn eggs 90° so that the large base lies horizontal.

2. Swab eggs to sterilize

- Saturate a stack of non-sterile gauze with 70% ethanol.
- Use two to three pieces to swab up to 5 eggs. Discard when the gauze is soiled.

3. Preparing albumen removal site

- Cut and place a 1" x 1" piece of 3M plastic tape just left of the base to protect the area where the albumin will be drawn out.

4. Removal of albumen

- Use the point of a pair of scissors to make a small hole in the middle of the tape.
- Using a 10 cc syringe with an 18-gauge, 1-inch needle, slowly drill the needle through the hole made by the scissors.
- Drive the needle down at a 45° angle towards the bottom of the egg.
- Tilt the needle towards the center and draw up 3 to 4 mL of albumen.

5. Windowing

- Cut a 3" x 3" piece of plastic tape and stretch it to fit on the top of the egg. Extend the corners of the square around the rounded ends of the horizontal surface of the eggs, being careful not to pull too hard. Pull the tape so that it is tight against the surface of the eggs with no folds.
- Using a pair of sharp-straight 4" dissection scissors, twist a hole into the bottom center of the area where the tape was placed. Slowly guide the lower blade of the scissors into the egg being sure to keep the tips up against the inside of the shell. Direct the blade towards the base and slowly begin to cut the shell. Proceed in a counter-clockwise fashion, stopping just before reaching the top center. Remove the scissors and repeat going in the opposite direction until only a small bit of the egg remains attached. Check to be sure the egg is fertilized. Shut the window.

6. Closing, reopening and sealing the egg.

- Cut about a 2-3" long by 1/2" wide plastic tape and shut the window so it fits back into the hole that was cut. Take another 1 x 1" piece of tape and seal the hole from which the egg was drained. Use a pair of forceps to reopen the egg to do any manipulations. When you're ready to return the eggs to the incubator, cut a piece of tape that is large enough to seal the window and cover the entire horizontal surface of the egg.

This method allows for long survival times following experimental manipulations. For example, dye-labeling studies allowed survival to E10 or later in a fate mapping study (1). In addition, it has been used for in ovo electroporation studies that provide alteration of gene expression levels and required development to proceed to later developmental stages (2-6). This windowing technique can be used in combination with any procedure that requires survival after manipulations to the embryo.

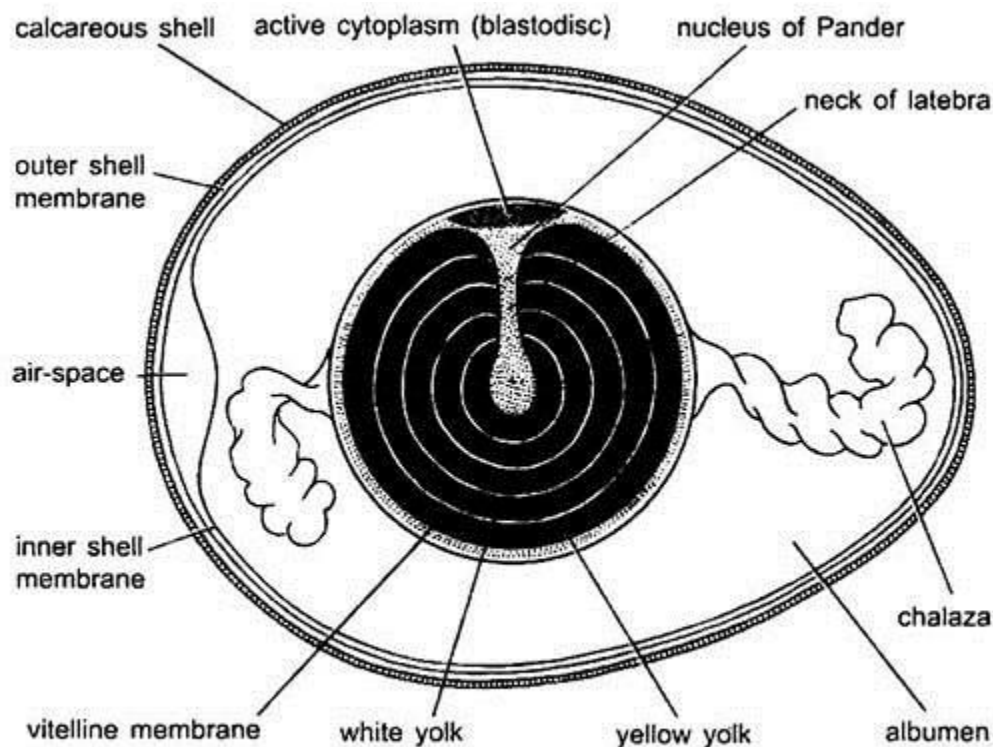


Fig. 38.1. Diagrammatic longitudinal section of a hen's egg.

5.7 Endocrine glands of rat, insect (location through models, charts)

1-Pituitary Gland

The pituitary gland (hypophysis) may be divided into two major compartments: (1) the adenohypophysis (anterior lobe) composed of the pars distalis, pars tuberalis, and pars intermedia; and (2) the neurohypophysis (posterior lobe), which includes the pars nervosa and infundibulum. The pars intermedia is separated from the pars distalis by Rathke's cleft, which is a remnant of the lumen of the craniopharyngeal duct. The pituitary lies within the sella turcica of the sphenoid bone. A hypothalamic-hypophyseal portal blood system transports hypothalamic-releasing and release-inhibiting hormones directly to the adenohypophysis for interactions with their specific target cells.

The neurohypophysis is joined to the hypothalamus via the infundibular stalk and is composed of densely packed bundles of unmyelinated axons and capillaries that are supported by modified glial cells or pituicytes. The capillaries in the pars nervosa are termination sites for unmyelinated axons, which originate from the hypothalamic neurosecretory neurons. Axons arising from supraoptic and paraventricular nuclei of the hypothalamus terminate in the pars nervosa. Both oxytocin and vasopressin (antidiuretic hormone, ADH) are synthesized in supraoptic and paraventricular nuclei as large precursor molecules, which contain both active hormones and their associated neurophysins (carrier proteins which transport the hormones). As the biosynthetic precursor molecules travel along the axons in secretion granules from the neurosecretory neurons, the precursors are cleaved into the active hormones and their respective neurophysins.

The pars distalis of the adenohypophysis represents the largest portion of the pituitary gland. The cells within this lobe are responsible for the synthesis of at least six major hormones: growth hormone (GH), prolactin (PRL), and adrenocorticotrophic hormone (ACTH), follicle-stimulating hormone (FSH), luteinizing hormone (LH), and thyroid-stimulating hormone (TSH) or thyrotropin. The GH (~50% of the pars distalis cells) and PRL-secreting cells (~15–25% of the pars distalis cells) stain as acidophils and contain abundant cytoplasmic secretory granules. Some GH cells may be chromophobic if they are in an actively synthesizing phase of the secretory cycle. Pregnancy and lactation are associated with hyperplasia of prolactin-secreting cells. These so called “pregnancy cells” are chromophobic by routine staining techniques but contain prominent arrays of granular endoplasmic reticulum, well-developed Golgi complexes, and few secretory granules. ACTH-producing cells (corticotrophs) consist of ~15% of the pars distalis cells. The cells are round to ovoid, may be chromophobic or lightly basophilic, and can stain weakly positive with PAS. Crooke’s hyaline change refers to the intracellular accumulation of an eosinophilic homogeneous material within the cytoplasm of these cells. Immunohistochemical staining reveals that this material represents a keratin-like protein, which accumulates in conditions associated with glucocorticoid hormone excess.

Thyrotropin-producing (TSH) basophils or thyrotrophs (~5% of the pars distalis cells) tend to occur in small clusters within the pars distalis and have a stellate to polygonal shape. They may be basophilic or chromophobic and are also PAS-positive. Any condition that leads to hypofunction of the thyroid or increased hepatic degradation of thyroid hormones, results in the development of “thyroidectomy cells” in the pituitary gland. “Thyroidectomy cells” are enlarged and vacuolated TSH cells that contain prominent, often dilated granular endoplasmic reticulum, conspicuous Golgi complexes, and few secretory granules. Gonadotropin-producing (GTH) basophils or gonadotrophs (~10% of the pars distalis cells) are relatively large round to oval cells, which are responsible for the production of FSH and LH. Gonadotroph cells undergo a series of changes following castration, resulting in the formation of “gonadectomy cells”. As a result of the lack of negative feedback by gonadal steroids, gonadotrophs are actively stimulated to synthesize and secrete FSH and LH. Gonadotrophs undergo hypertrophy, and the cytoplasm becomes vacuolated due to distention profiles of endoplasmic reticulum with finely granular material in response to long-term stimulation by gonadotropin-releasing hormone (GnRH) from the hypothalamus. In some cells, a single large vacuole occupies most of the cytoplasm, producing cells with a “signet ring” appearance. The pars intermedia consists of chromophobic cells that is readily identified by its location. These endocrine cells of the pars intermedia produce melanocyte-stimulating hormones (α -MSH and β -MSH), ACTH, and other peptide hormones.

In addition to specific hormone-secreting cells, a population of supporting cells is also present in the adenohypophysis. These cells have been referred to as stellate (follicular) cells and can be stained selectively with antibodies to S-100 protein or cytokeratin. Stellate cells typically have elongate processes and prominent cytoplasmic filaments. These cells provide a phagocytic or supportive function in addition to producing a colloid-like material.

The different endocrine cells of the adenohypophysis are not uniformly distributed. The regions that contain acidophils (acidophil zones) are conspicuous because there are more acidophils than other cell types and the cytoplasm stains intensely. The other zones contain a mixture of basophils and chromophobic endocrine cells, and the chromophobic cells predominate. Basophils often occur in small clusters admixed with chromophobic cells. The most efficient way to accurately identify endocrine cell types is to use immunohistochemistry

for secretory hormones. The staining intensity will vary depending on the amount of stored hormone in the cytoplasm. Hypertrophied endocrine cells with a high rate of hormone synthesis and secretion will stain lightly using immunohistochemistry due to the low number of cytoplasmic secretory granules.

The hypothalamus serves as the major regulator of the adenohypophysis. Each cell type within the adenohypophysis is under the control of a corresponding releasing hormone that is synthesized within nerve cell bodies of the hypothalamus. The releasing hormones are transported via axonal processes to the median eminence where they are released into capillaries and are carried by the hypophyseal portal system to trophic hormone-producing cells in the adenohypophysis. Specific releasing factors have been identified for TSH, FSH and LH, ACTH, and GH. PRL secretion is stimulated by a number of factors, the most important of which appears to be thyrotropin releasing hormone (TRH).

Multiple influences contribute to the control of adenohypophyseal hormone secretion. Dopamine serves as the major prolactin inhibitory factor. Dopamine also suppresses ACTH and melanocyte stimulating hormone production by corticotrophs in the pars intermedia. A second hypothalamic release inhibiting hormone is somatostatin (somatotropin release-inhibiting hormone, SRIH). This tetradecapeptide inhibits the secretion of both GH and TSH. In some situations, SRIH also inhibits the secretion of PRL and ACTH. The control of pituitary hormone secretion is also affected by negative feedback loops resulting from the interaction of end organ hormones, adenohypophyseal hormones, and corresponding hypothalamic releasing-and release-inhibiting hormones. Estrogen stimulates prolactin secretion and lactotroph proliferation, particularly in the rat.

2-Pineal Gland

The pineal gland is part of the brain and functions as a neuroendocrine organ. Its principle secretion is melatonin. The gland is located between the occipital poles of the telencephalon and the cerebellum. The gland has a superficial and deep portion connected by a stalk, and is close to the third ventricle and subarachnoid space. Calcareous concretions are common, which increase with age and apparently do not affect function of the gland. The pineal gland is composed of pinealocytes, neurons, and supporting glial cells with blood vessels. The gland is surrounded by a capsule. The pinealocytes are derivatives from pineal photoreceptors that occur in lower species, such as poikilotherms, and the cells may contain ultrastructural remnants of the photoreceptor cells. The pinealocytes produce and secrete melatonin and also contain serotonin. Dense-core secretory granules are sparse compared to other endocrine cells. The neurons of the pineal gland connect to the central nervous system and the gland is also innervated by the sympathetic system.

3-Thyroid Gland

The thyroid gland originates as a thickened plate of epithelium in the floor of the pharynx to form the thyroglossal duct, which extends along the midline to the region of the larynx in the fetus. The paired lobes of the thyroid form from the thyroglossal duct on either side of the larynx and proximal trachea. The ultimobranchial bodies fuse with the thyroid and deliver C cells (neural crest origin) to each thyroid lobe. Accessory thyroid tissue may form from small

remnants of the thyroglossal duct from the larynx to the heart, but this is rare in rodents. Accessory thyroid tissue can be identified by its general lack of C cells. Also rare in rodents are thyroglossal duct cysts, which develop in the ventral aspect of the anterior cervical region and occur as a result of persistence of a portion of the thyroglossal duct postnatally.

The basic structure of the thyroid gland is unique for endocrine glands, consisting of follicles of varying size (20–250 μm) that contain colloid produced by the follicular cells. Follicular cells are cuboidal to columnar, and their secretory polarity is directed toward the lumen of the follicles. The biosynthesis of thyroid hormones is also unique among endocrine glands because the final assembly of the hormones occurs extracellularly within the follicular lumen. The assembly of thyroid hormones within the follicular lumen is made possible by a unique protein (thyroglobulin) synthesized by follicular cells. Thyroglobulin is a high molecular weight (600,000 to 750,000) glycoprotein. The amino acid tyrosine, an essential component of thyroid hormones, is incorporated in the molecular structure of thyroglobulin. Iodine is bound to tyrosyl residues in thyroglobulin at the apical surface of follicular cells to form, successively, monoiodotyrosine (MIT) and diiodotyrosine (DIT). The resulting MIT and DIT combine to form the two biologically active iodothyronines—thyroxine, T_4 , and triiodothyronine, T_3 —secreted by the thyroid gland. The mechanism of active transport of iodide is associated with a sodium iodide (Na^+I^-) symporter (NIS). The transporter protein is in the basolateral membrane of thyroid follicular cells (thyrocytes).

Long-term perturbations of the pituitary-thyroid axis by various xenobiotics or physiologic alterations (e.g., iodine deficiency or goitrogens) are likely to predispose the laboratory rat to a higher incidence of proliferative lesions (e.g., hyperplasia and adenomas of follicular cells) in response to chronic TSH stimulation than in the human thyroid. This is particularly true in the male rat, which has higher normal circulating concentrations of TSH than females. The greater sensitivity of the rodent thyroid to derangement by drugs, chemicals, and physiologic perturbations is also related to the shorter plasma half-life of T_4 than in man due to the considerable differences between species in the transport proteins for thyroid hormones. The plasma T_4 half-life in rats is considerably shorter (12–24 hr.) than in man (5–9 days). In human beings and monkeys circulating T_4 is bound primarily to thyroxine-binding globulin (TBG) but this high-affinity binding protein is not present in rodents. Mice are less susceptible to proliferative lesions of the thyroid follicular cells when compared to rats.

Negative feedback control of thyroid hormone secretion is accomplished by the coordinated response of the adenohypophysis and certain hypothalamic nuclei to circulating and local tissue levels of T_3 . In the rat, 50% or more of the pituitary content of T_3 is generated locally from circulating T_4 by a 5'-deiodinase (type II). A decrease in thyroid hormone concentration in plasma is sensed by neurosecretory neurons in the hypothalamus that synthesize and secrete thyrotropin releasing hormone (TRH; 361 Da) into the hypophyseal portal circulation. TRH binds to receptors on the plasma membrane of thyrotrophic basophils in the adenohypophysis, which leads to release of TSH-containing secretory granules into pituitary capillaries. Thyroid-stimulating hormone is conveyed to thyroid follicular cells where it binds to the basilar aspect of the cell and increases the rate of the synthesis and secretion of thyroid hormones. If the secretion of TSH is sustained (hours or days), thyroid follicular cells become more columnar and follicular lumens become smaller due to the increased endocytosis of colloid. Numerous PAS-positive colloid droplets are present in the luminal aspect of the hypertrophied follicular cells. Conversely, in response to an increase in circulating levels of thyroid hormones (T_4 and T_3), there is a corresponding decrease in circulating pituitary TSH.

Thyroid follicles become enlarged and distended with colloid due to the decreased TSH-mediated endocytosis of colloid.

Thyroid hormones are degraded primarily by conjugation in the liver. Thyroxine is conjugated on the outer phenolic ring with glucuronic acid in a reaction catalyzed by thyroxine UDP glucuronosyltransferase, and conjugated T₄ is excreted in the bile. A wide variety of drugs and chemicals can influence thyroid hormone metabolism by inducing one or more classes of hepatic microsomal enzymes that increase the degradation of thyroid hormones. The stepwise monodeiodination of thyroxine in the liver, kidney, and elsewhere is also important in the metabolism of thyroid hormones. The removal of an iodine molecule from the 5 position on the outer phenolic ring by 5'-deiodinase results in the formation of biologically active T₃ (3,5,3'-triiodothyronine). However, if a molecule of iodine is removed from the 5 position of the inner phenolic ring of T₄ by another enzyme, 5-deiodinase, reverse T₃ (3,3',5'-triiodothyronine) is produced, which is biologically inactive.

The subcellular mechanism of action of thyroid hormones resembles that of steroid hormones because free hormone enters into target cells and binds to its receptors. Free T₃ either binds to receptors on the inner mitochondrial membrane to activate mitochondrial energy metabolism or binds to nuclear receptors and increases transcription of mRNA to facilitate new protein synthesis. The overall effects of thyroid hormones are to (1) increase the basal metabolic rate; (2) increase glycolysis, gluconeogenesis, and glucose absorption from the intestine; (3) stimulate new protein synthesis; (4) increase lipid metabolism and conversion of cholesterol into bile acids and other substances, activate lipoprotein lipase, and increase the sensitivity of adipose tissue to lipolysis by other hormones; (5) stimulate the heart rate, cardiac output, and blood flow; and (6) increase neural transmission, cerebration, and neuronal development in young animals.

C cells or parafollicular cells of the thyroid gland are located within thyroid follicles between the basal aspects of the follicular cells and the basement membrane of the follicle or are present in a parafollicular position. In addition to calcitonin, C-cells contain a variety of other peptides, including calcitonin gene-related peptide and somatostatin, and they are also positive for a wide variety of generic neuroendocrine markers, including chromogranins and synaptophysin. In most rats and mice, C-cells are concentrated within the central regions of the lobes, being most prominent at the levels of the parathyroid glands. By light microscopy, C-cells often have a clear or light appearance, but silver-positive cytoplasmic granules can be demonstrated by argyrophilic staining sequences. C cells are more easily identified in rats compared to mice because they have greater numbers of C cells that also increase with age. Immunohistochemistry for calcitonin can be helpful for evaluation of C cell numbers, particularly in mice.

Calcitonin is a 32-amino acid peptide that is derived from a 141-amino acid precursor (procalcitonin). The levels of ionized calcium in plasma and extracellular fluids are the major physiologic stimulus for the secretion of calcitonin. The cell membrane calcium-sensing receptor, cloned from parathyroid cells, is also expressed in C-cells and contributes to the regulation of calcitonin secretion. Calcitonin interacts with specific receptors in target cells, principally in bone and kidney. Calcitonin inhibits osteoclast activity in bone, renal tubular resorption of calcium, and calcium absorption by the intestines. Calcitonin secretion is increased in response to a high calcium meal often before a significant rise in plasma calcium

levels can be detected. The secretion of gastrin, cholecystokinin and glucagon is stimulated by an oral calcium load, and these hormones also serve as calcitonin secretagogues. Calcitonin also protects against calcium loss from the skeleton during periods of calcium mobilization, such as growth, pregnancy, and lactation.

4-Parathyroid Glands

The paired parathyroid glands are usually located on the anterior and lateral aspect of the thyroid lobes, and are separated from the thyroid by a thin capsule of fibrous connective tissue. Embryologically, parathyroids are of endodermal origin, derived from the pharyngeal pouches in close association with the primordia of the thymus. Accessory parathyroid tissue can occur in the thymus or dorsolateral to the esophagus near the larynx. The mass of the parathyroid glands of female rats is up to twice that of males.

Parathyroids contain a single type of secretory (chief) cell that synthesizes and secretes parathyroid hormone (PTH). Parathyroid glands are composed of chief cells in different stages of secretory activity. Oxyphil cells occur in certain animal species and humans, but do not occur in rats and mice. Oxyphil cells are larger than chief cells and their abundant eosinophilic cytoplasm is filled with numerous large, often bizarre-shaped, mitochondria.

The parenchyma of the parathyroid glands consists of densely packed, highly folded, branching cords or clusters of polygonal cells separated by a delicate stroma of reticular and collagen fibers with occasional fibrocytes. The cords are usually a single cell layer in a trabecular and acinar arrangement. The chief cells are uniform with spherical to oval to elongated nuclei and scant to moderate amounts of cytoplasm. The nuclei have loosely aggregated or finely dispersed chromatin and inconspicuous nucleoli. The cytoplasm is faintly eosinophilic. The amount of cytoplasm usually reflects the level of activity of the chief cells. Chief cells with increased synthesis and secretion of parathyroid hormone are hypertrophied with increased cytoplasm and reduced eosinophilia or vacuolation of the cytoplasm.

PTH is involved in the regulation of calcium homeostasis with calcitonin and calcitriol (the active form of vitamin D). The principal action of PTH is to maintain adequate blood calcium levels by controlling the rate of calcium resorption from bone, enhancing the absorption of calcium from the renal tubules and stimulating active absorption of calcium from the intestine (via calcitriol). The chief cells store relatively small amounts of preformed hormone but respond to minor fluctuations in blood calcium ion, and to a much lesser extent magnesium ion, by rapidly altering the rate of hormonal secretion and degradation and more slowly altering the rate of synthesis. Hypocalcemia causes the rapid release of PTH into the blood, which increases the bone reabsorbing activity of osteocytes and osteoclasts. PTH also has a rapid and direct effect on renal proximal tubules, blocking the reabsorption of phosphate as well as enhancing the absorption of calcium from the distal convoluted tubule. The rising levels of calcium ion in the plasma inhibit the secretion of PTH (negative feedback inhibition). PTH also stimulates and regulates the conversion of 25-hydroxycholecalciferol to 1,25-dihydroxycholecalciferol (calcitriol) in the kidney, which is required for PTH to regulate the activity of osteocytes and osteoclasts and for calcium absorption from the intestine.

Rising plasma levels of calcitriol provide additional feedback regulation by inhibiting further secretion of PTH.

5-Adrenal Cortex and Medulla

The adrenal glands are the most commonly affected endocrine organs secondary to chemical exposure. In the adrenal glands, chemically induced lesions are found most frequently in the *zona fasciculata* and *reticularis* and to a lesser extent in either the *zona glomerulosa* or the medulla.

The adrenal glands are located close to the anterior pole of the kidneys. They receive arterial blood from branches of the aorta or from regional arteries that result in a vascular plexus, and perfusion occurs by sinusoids that perfuse the entire gland, including both the cortex and the medulla. Venous blood flow is derived from the sinusoidal network with eventual flow into the medulla.

Grossly, a midsagittal section of the adrenal glands reveals a clear separation between the cortex and the medulla. The cortex is yellow, and occupies approximately two-thirds of the entire cross-sectional diameter of the organ. Cortical zones (from outer to inner) consist of the *zona glomerulosa*, *zona fasciculata*, and *zona reticularis*. These zones are not always clearly delineated, and the *zona reticularis* is not morphologically delineated in the mouse. The mineralocorticoid-producing *zona glomerulosa* contains cells aligned in a sigmoid pattern in relationship to the capsule. Loss of this zone or the inability to secrete mineralocorticoids (e.g., aldosterone) may result in death of the animal due to the retention of inappropriately high levels of potassium in association with an excessive loss of sodium chloride and water. The largest zone is the *zona fasciculata* (> 70% of the cortex). Cells in this zone are arranged in long anastomosing cords or columns, separated by small capillaries. They are responsible for the secretion of glucocorticoid hormones (e.g., corticosterone in the rat and mouse).

The adrenal cortical cells contain large cytoplasmic lipid droplets, which consist of cholesterol and other steroid precursors. The lipid droplets are in close proximity to the smooth endoplasmic reticulum and large mitochondria, which contain the specific hydroxylase and dehydrogenase enzyme systems required to synthesize the different steroid hormones. Unlike polypeptide hormone-secreting cells, there are no secretory granules in the cytoplasm because there is direct secretion without significant storage of preformed steroid hormones.

Adrenal steroids are synthesized from cholesterol, which is derived from acetate or circulating lipoproteins. A complex shuttling of steroid intermediates between mitochondria and endoplasmic reticulum characterizes specific synthetic processes. The specificity of mitochondrial hydroxylation reactions in terms of the steroid modified and the position of the substrate that is hydroxylated are confined to a specific cytochrome P450 (CYP). Corticosterone is the major glucocorticoid produced in rats and mice. Essentially, rodents lack CYP17 and this is an important consideration for toxicology, as compounds that inhibit this enzyme may not be fully detected in rodent species. Species with CYP17 produce cortisol and those lacking CYP17 produce corticosterone as the major glucocorticoid. CYP17

is required for androgen production by the *zona reticularis*, therefore, rats and mice synthesize no to minimal sex steroids.

The principal control for the production of steroids by the *zona fasciculata* and *zona reticularis* is mediated by adrenocorticotrophic hormone (adrenocorticotropin; ACTH) produced by corticotrophs in the adenohypophysis. ACTH release is largely controlled by the hypothalamus through the secretion of corticotropin-releasing hormone (CRH) and arginine-vasopressin. An increase in ACTH production normally results in an increase in circulating levels of glucocorticoids, although it can cause weak stimulation of aldosterone secretion as well. Negative feedback control normally occurs when the elevated blood levels of cortisol act on the hypothalamus, anterior pituitary, or both to cause a suppression of ACTH secretion.

The adrenal cortex is dependent on trophic support of hormones from the pituitary and hypothalamus, as well as, hormones from other endocrine tissues. Additionally, the adrenal cortex has both anatomic and molecular characteristics that convey vulnerability to toxic insult.

The adrenal medulla constitutes approximately 10% of the volume of the adrenal gland. Histologically, the normal adrenal medulla in the rodent is sharply demarcated from the surrounding cortex. The bulk of the medulla is composed of chromaffin cells, which are the sites of synthesis and storage of catecholamines. In the rat and mouse, norepinephrine and epinephrine are stored in separate chromaffin cell types, which can be distinguished ultrastructurally by the morphology of their secretory granules. In addition to chromaffin cells, the adrenal medulla contains variable numbers of ganglion cells. A third cell type has also been described and has been designated the small granule-containing (SGC) cell or small intensely fluorescent (SIF) cell. These cells morphologically appear intermediate between chromaffin cells and ganglion cells, and are thought to possibly function as interneurons.

6-Endocrine Pancreas (Islets of Langerhans)

The endocrine pancreas consists of discrete aggregates of cells distributed throughout the pancreas, called the islets of Langerhans. The islets comprise approximately 1–2% of the total pancreatic tissue in a normal adult rat. The main function of the endocrine pancreas is the regulation of blood glucose. Diabetes mellitus (DM) is the clinical condition where there is failure of the control of blood glucose with the development of hyperglycemia and hyperglucosuria. While lesions in the islets of Langerhans are infrequently observed in toxicity studies, the mouse and rat have been important for studying the pathogenesis of diabetes mellitus resulting from obesity, genetic predisposition, autoimmune disease, or chemically induced islet cell injury.

The pancreas is formed from two distinct outgrowths of endoderm located in the foregut at the level of the duodenum. The larger dorsal anlage and smaller ventral bud fuse to form the dorsal and ventral portions of the pancreas. The islets are formed from a progenitor cell population located in the small ducts of the pancreatic primordium from which the pancreatic acinar cells arise. Clusters of immunoreactive endocrine cells recognized as primitive islets are present by day 14 of gestation. As the fetal islets develop, a proportion of them detach

from the duct system. α and β cell numbers increase rapidly during late fetal life, and they make up a majority of the islet cell population at birth.

Pancreatic endocrine cells are arranged in small aggregates, the islets of Langerhans, or are located individually or in small clusters in contact with acini or ducts. Islets of Langerhans range from 100 to 200 μm in diameter in adult rats, and consist of closely apposed branching cords of pale-staining polygonal cells surrounded by a basal lamina, a delicate network of reticulum fibers, and frequent interspersed capillaries. A fibrous tissue capsule is not present. The cells are homogeneous with finely granular, lightly eosinophilic cytoplasm and round to oval nuclei containing finely stippled chromatin and a single nucleolus. The nuclei are usually located opposite the secretory pole which is adjacent to the capillary.

Multiple cell types, each capable of secreting one or more hormones, are present in the pancreatic islets. These cells, which contain glucagon (α cells), insulin (β cells), somatostatin (δ cells), pancreatic polypeptide (PP or F cells), substance P (enterochromaffin cells), or ghrelin (ϵ cells) are not randomly distributed in the islets, but rather are located in specific areas. In rodents, the α cells, δ cells, and less numerous PP cells occur at the periphery of the islet, whereas the β cells are located in the center and are the most numerous, comprising about 60–80% of the islet volume. The α cells and δ cells comprise approximately 2–28% and < 10% of the islet cells, respectively.

The individual cell types within the islets of Langerhans are differentiated most readily by electron microscopy or immunohistochemical techniques, since the hormone-containing secretory granules are unique biochemically and structurally. The blood vessels of the islets are lined with fenestrated endothelium. Some islet capillaries also supply pancreatic acinar cells in the peri-islet zone. The arrangement of the microvasculature may be important for the paracrine activity of islet hormones.

The islets in the dorsal and ventral portions of the pancreas arise from different anlagen and contain different cell populations. Islets in the tail, body, or superior part of the head of the pancreas (collectively the dorsal or “splenic” part of the pancreas) contain a greater proportion of glucagon-containing α cells (~28%) than PP cells (2%). The reverse is true in the middle and inferior part of the head (ventral or “duodenal” region with ~2% α cells and 20% PP cells).

The various islet hormones are involved in regulation of multiple metabolic activities. Insulin accounts for approximately 85% of the hormone production of the endocrine pancreas, and has the primary function of facilitating entry of glucose through cell membranes. In addition, it influences glucose utilization by controlling gluconeogenesis in liver, muscle, and adipose tissue. By these dual mechanisms, insulin maintains blood glucose levels within the appropriate physiological range. Glucagon promotes glucose mobilization by stimulating hepatic glycogenolysis and gluconeogenesis from amino acids and fatty acids.

Somatostatin, named for its action in suppressing secretion of growth hormone, inhibits secretion of insulin and glucagon. Control of the release of islet cell hormones is influenced by four major mechanisms: (1) blood levels of nutrients including glucose, fatty acids, and amino acids; (2) postprandial secretion of incretin hormones (such as glucagon-like peptide-

1, GLP-1, and gastric inhibitory peptide, GIP) from enteric endocrine cells that stimulate glucose-dependent insulin secretion; (3) activity of the autonomic nervous system (parasympathetic stimulation favors secretion of both insulin and glucagon, whereas sympathetic activity inhibits insulin release and promotes glucagon secretion); and (4) paracrine activity of islet hormones on neighboring cells. By this latter mechanism insulin inhibits glucagon release, glucagon stimulates release of insulin, and somatostatin inhibits release of both insulin and glucagon. Insulin secretion by β cells declines with age.

The diminished insulin responsiveness may be partly attributable to increased somatostatin. However, the mass of the endocrine pancreas is three- to four-fold greater in the mature *ad libitum*-fed rat than in 2-month-old rats and therefore the total insulin secretion of the pancreas is nearly the same. The greater islet cell mass is due to larger number and volume density of β cells while α and δ -cell populations remain approximately the same.

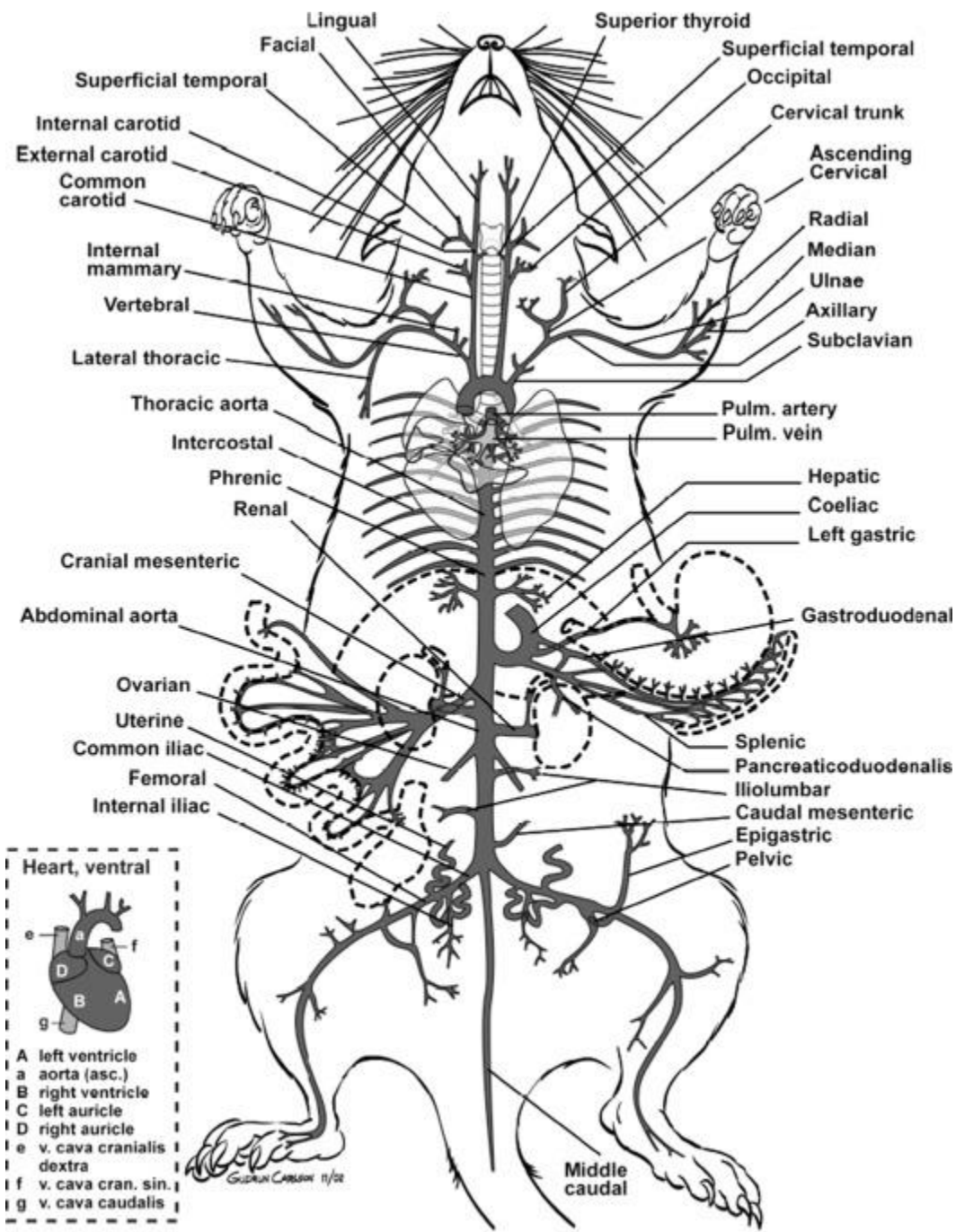


Fig .5.8-Endocrine Pancreas (Islets of Langerhans)

Endocrine gland in insect

Organs of Nervous Origin:

In insects, neurosecretory cells are numerous and have important functions. Recent work has revealed that there are two types of neurosecretory cells: type A which stain with para-aldehyde fuchsin, and type B which do not. All cells possess electron dense granules. The neurosecretory cells can produce blue colour from the reflected light due to the light scattering effect of colloidal-sized particles.

Protocerebrum:

It is the most complex part of the insect brain consisting of several distinct cell masses and regions of neuropile. The pars intercerebralis, part of protocerebrum is located in the dorsal median region above the proto-cerebral bridge and central body. It contains two groups of neurosecretory cells that transport their secretions to the corpus cardiacum.

Sub-esophageal and ventral chain ganglia:

Neurosecretory cells are also found to be located in sub-esophageal and ventral chain ganglia. The sub-esophageal ganglia are composed of three fused ganglia that innervate sense organs, and muscles associated with mouth parts, salivary glands and neck region.

Corpora cardiaca:

The corpora cardiaca arise from the nervous system and are situated behind the brain in close association with the dorsal aorta. They receive axons from the neurosecretory cells in the brain and serves as storage and release sites for their secretions. That is why it also acts as neuro- haemal organ.

Four cellular elements have been recognised in this organ:

- (1) The bulbous endings of neurosecretory axons whose perikarya are located in the dorsum of the brain,
- (2) The perikarya of neurosecretory cells that send axons into nerves that supply various peripheral organs,
- (3) Glia-like cells and
- (4) Intrinsic corpus cardiacum cells.

Although, the corpora cardiaca are storage release centres, there are evidences that their own cells are capable of producing secretions.

Endocrine Organs of Epithelial Origin:

Corpora allata:

Aggregation of ectodermal cells proliferated from the surface epithelium in the vicinity of the mouth parts are seen in the posterior margin of the brain. These cells form the gland, corpora allata. These glands are commonly paired and laterally placed (*Periplaneta*) or they may fuse to form a single structure (*Rhodnius*).

In the butterfly *Pieris*, few large cells with polymorphic nuclei are found in corpora allata. The corpus allatus of bug (*Pentatoma rufipes*) consists of almost syncytial mass of small cells with cell boundaries barely distinguishable. In phasmid (*Bacillus rossii*), a nearly columnar epithelium surrounding the embryonic lumen persists in the adult phasmsids (Fig. 7.55).

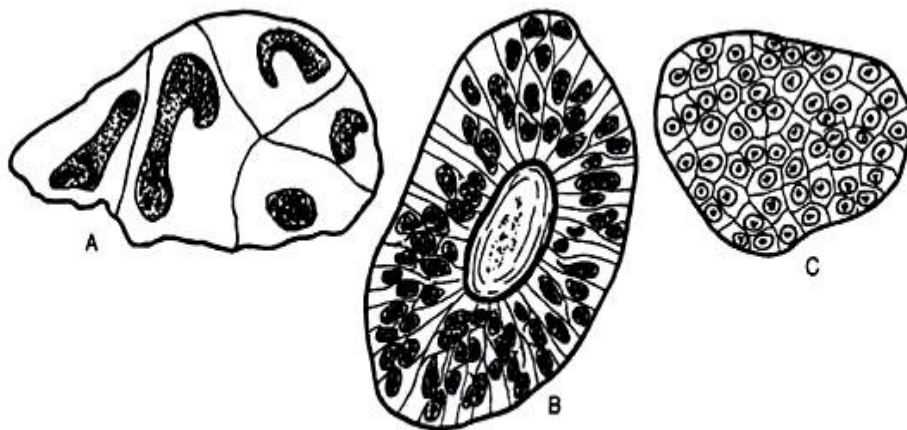


Fig. 7.55 : Histological structure of corpora allata of different insects : A. *Pieris brassicae*, few large cells with polymorphic nuclei, B. *Pentatoma rufipes*, an almost syncytial mass of small cells, and C. *Bacillus rossii*, a nearly columnar epithelium surrounding the embryonic lumen

Fig .5.9

Thoracic gland:

These glands are found only in immature insects, with the exception of the Apterygotes. These are also called prothoracic glands or ecdysial glands. These glands consist of irregular masses of tissue of ectodermal origin that are usually intimately associated with tracheae.

The glands may or may not be innervated. Depending upon its final location, these glands are also identified as peri-tracheal or ventral glands. The cells of these glands show cyclic secretory activity, reaching a maximum between moults. The glands atrophy in the adults.

Ring gland:

The larvae of higher Diptera (true flies) contain a small ring of tissue, supported by tracheae, called the ring gland or Weismann's ring. The different cells that compose it are considered to be homologous with corpora allata, corpora cardiaca and the thoracic glands.

Some Other Endocrine Glands:

In *Aeschnia cyanea*, two types of endocrine cells were found to be located in midgut. One type is filled with dense granules and the other includes vesicles with an excentric core or has a loose filamentous appearance. These cells discharge their contents into the internal medium at the level of the basement membrane.

1. Neurohormones of the Brain:

Ecdysiotropin:

Protocerebrum secretes ecdysiotropin or prothoracicotropic hormone (PTTH) or brain hormone (BH) that acts on ecdysial glands.

Bursicon (Tanning hormone):

Neurosecretory cells within the brain produce a blood borne hormone which triggers the tanning or darkening of adult cuticle. It is a protein hormone with a molecular weight of about 40,000. It is released into the fused thoracoabdominal ganglia. Bursicon is released after the emerged fly has dug its way out of the soil, but in some insects this hormone may be secreted slightly before or during the loss of the old skin.

Eclosion hormone:

Median neurosecretory cells of the brain produce eclosion hormone, which collects in the corpora cardiaca and is released into the blood at the time of switchover from pupal to adult stage. In most insects it acts upon neurons within the abdominal ganglia to initiate the pre-eclosion behaviour. Other neurohormones released from the brain and their target organs, and their functions are mentioned in Table 7.21.

Table 7.21 : A selected list of Insect nonneural, neural and peptide hormones

Active Principle	Origin	Target	Functional Role
I. Nonneural hormones			
A. Immature insects			
Ecdysone (moulting hormone)	ecdysial gland	epidermis	Initiates moult
Juvenile hormone	corpora allata	epidermis	controls or directs facets metamorphosis of male
B. Adult insects			
Ovarian hormone (= ecdysone)	ovarian tissue and probably follicle cells	fat body	initiates and regulates production of vitellogenin
Juvenile hormone	corpora allata	fat body	primes the fat body to become competent to produce vitellogenin
Juvenile hormone	corpora allata	follicle cells	activates uptake of vitellogenin in follicle cells
II. Neural hormones and peptide hormones			
Ecdysiotropin (= prothoracicotropic hormone)	brain (protocerebrum)	ecdysial glands	developmental—stimulus and regulates production and release of ecdysone
Bursicon	MNSC and thoracoabdominal ganglion, brain of pre-ecdysis moths	epidermis	developmental—stimulus sclerotisation and melanisation of cuticle
Eclosion hormone		abdominal ganglia (possibly the epitracheal glands, corpora allata)	behavioural—synchronisation of eclosion
Allatostatins	brain	corpora allata	developmental/behaviour and homeostasis—inhibit JH production
Allatotropin	brain	corpora allata	developmental/behavioural and homeostasis—stimulates JH production and release
Diuretic hormone	brain/corpora cardiaca and thoracic ganglia	Malpighian tubules and rectum	homeostasis—controls diuresis or fluid secretion
Mating inhibition hormone	accessory reproductive glands of male	brain	behavioural—prevents remating
Oviposition initiation hormone	accessory reproductive glands of male	oviduct ?	behavioural—initiates egg laying
Cardioaccelerator hormone	brain/corpora cardiaca	myocardium	homeostasis—increase in frequency and amplitude of muscle contraction
Proctolin	brain/corpora cardiaca	hindgut and possibly visceral muscle in general (heart and oviduct)	homeostasis—muscle contraction, defecation, egg-laying,

2. Hormones of Corpora Allata:

Juvenile hormone:

Juvenile hormone is produced by the corpora allata. Chemically the hormone is methyl 10-epoxy-7-ethyl-3, 11-dimethyl-2, 6-tridecadienoate in moth *Hyalophora cecropia* (Fig. 7.56A). It is likely that considerable species variability may be found in chemistry of this hormone since the corpora allata vary in functional importance.

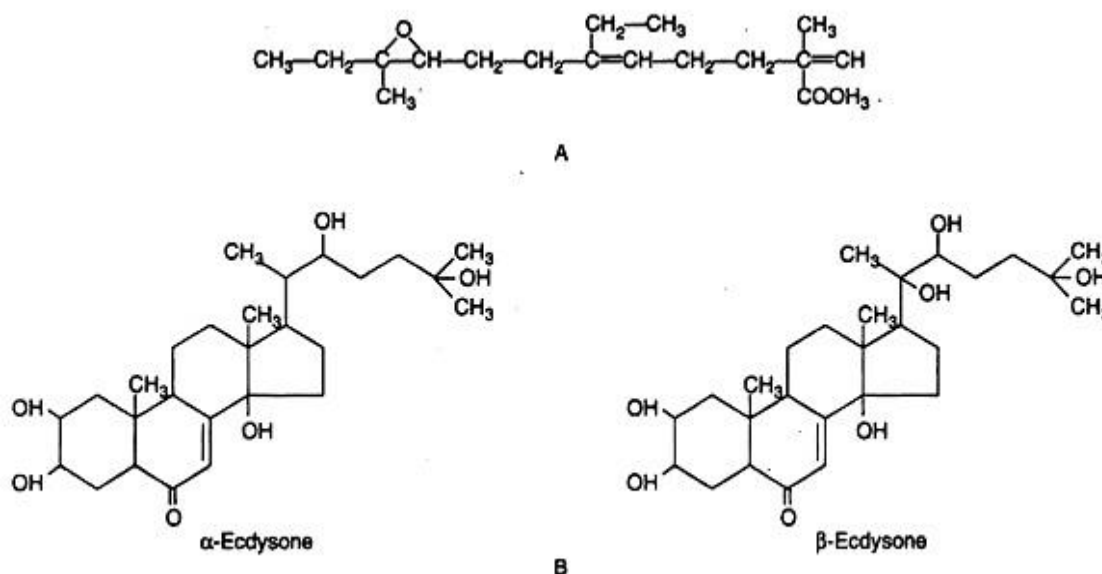


Fig. 7.56 : A. Structure of Juvenile hormone of the moth *H. cecropia*, B. Structures of ecdysones

3. Hormones of Ecdysial Gland:

Moulting hormone (Ecdysone):

Ecdysial gland secretes the moulting hormone. It is a steroid, called ecdysone. Two types of ecdysones can be synthesised by insects – α -ecdysone and β -ecdysone. The latter steroid differs from α -ecdysone only by having a hydroxyl group at position 20 (Fig. 7.56B). Similar β -ecdysone is also produced by crustacean arthropods (for functions see Table 7.21).

Functions of endocrine organs in insects:

Insect hormones and neurohormones have been studied with respect to their involvement in a number of general physiological functions (Fig. 7.57). Specifically, hormones and neurohormones influence development, diapause, mating and oviposition, metabolism, development of nervous system, control of circadian rhythms, regulation of dormancy, pheromone production and regulation of migratory behaviour.

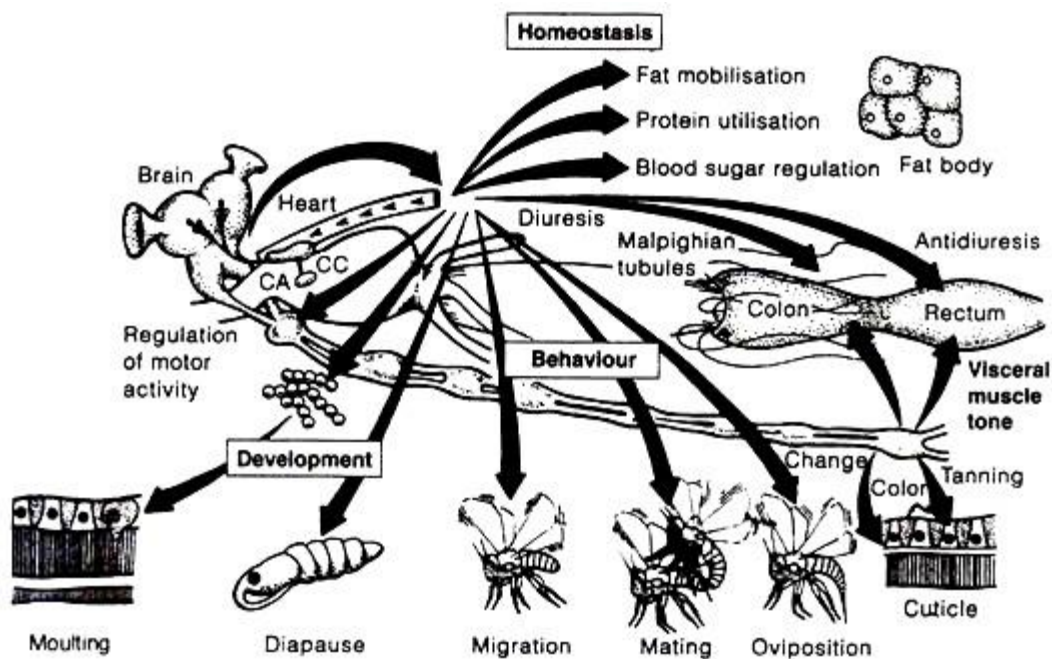


Fig. 7.57 : Major physiological functions regulated by neurohormones in insects

Fig .5.10

Endocrine Control of Growth and Metamorphosis:

Upon emergence from the egg, the immature insects gradually increase in size to reach adults through some mechanisms called moulting. Moulting involves the periodic digestion of old cuticle, secretion of new cuticle (usually with larger surface area than the older one) and shedding of undigested old cuticle.

The last step – shedding of undigested old cuticle- is commonly referred to as ecdysis. Sometimes the term moult is also used synonymously with ecdysis. A typical insect goes through a series of moults, increasing in size with each step. Each developmental stage of the insect itself is called an instar, and the interval of time passed in that instar is referred to as stadium.

These glands are found only in immature insects, with the exception of the Apterygotes. These are also called prothoracic glands or ecdysial glands. These glands consist of irregular masses of tissue of ectodermal origin that are usually intimately associated with tracheae.

The glands may or may not be innervated. Depending upon its final location, these glands are also identified as peri-tracheal or ventral glands. The cells of these glands show cyclic secretory activity, reaching a maximum between moults. The glands atrophy in the adults.

Ring gland:

The larvae of higher Diptera (true flies) contain a small ring of tissue, supported by tracheae, called the ring gland or Weismann's ring. The different cells that compose it are considered to be homologous with corpora allata, corpora cardiaca and the thoracic glands.

Some Other Endocrine Glands:

In *Aeschnia cyanea*, two types of endocrine cells were found to be located in midgut. One type is filled with dense granules and the other includes vesicles with an excentric core or has a loose filamentous appearance. These cells discharge their contents into the internal medium at the level of the basement membrane.

1. Neurohormones of the Brain:**Ecdysiotropin:**

Protocerebrum secretes ecdysiotropin or prothoracicotropic hormone (PTTH) or brain hormone (BH) that acts on ecdysial glands.

Bursicon (Tanning hormone):

Neurosecretory cells within the brain produce a blood borne hormone which triggers the tanning or darkening of adult cuticle. It is a protein hormone with a molecular weight of about 40,000. It is released into the fused thoracoabdominal ganglia. Bursicon is released after the emerged fly has dug its way out of the soil, but in some insects this hormone may be secreted slightly before or during the loss of the old skin.

Eclosion hormone:

Median neurosecretory cells of the brain produce eclosion hormone, which collects in the corpora cardiaca and is released into the blood at the time of switchover from pupal to adult stage. In most insects it acts upon neurons within the abdominal ganglia to initiate the pre-eclosion behaviour. Other neurohormones released from the brain and their target organs, and their functions are mentioned in Table 7.21.

Table 7.21 : A selected list of Insect nonneural, neural and peptide hormones

Active Principle	Origin	Target	Functional Role
I. Nonneural hormones			
A. Immature insects			
Ecdysone (moulting hormone)	ecdysial gland	epidermis	initiates moult
Juvenile hormone	corpora allata	epidermis	controls or directs facets metamorphosis of male
B. Adult insects			
Ovarian hormone (= ecdysone)	ovarian tissue and probably follicle cells	fat body	initiates and regulates production of vitellogenin
Juvenile hormone	corpora allata	fat body	primes the fat body to become competent to produce vitellogenin
Juvenile hormone	corpora allata	follicle cells	activates uptake of vitellogenin in follicle cells
II. Neural hormones and peptide hormones			
Ecdysiotropin (= prothoracicotropic hormone)	brain (protocerebrum)	ecdysial glands	developmental—stimulus and regulates production and release of ecdysone
Bursicon	MNSC and thoracoabdominal ganglion, brain of pre-ecdysis moths	epidermis	developmental—stimulus sclerotisation and melanisation of cuticle
Eclosion hormone		abdominal ganglia (possibly the epitracheal glands,	behavioural—synchronisation of eclosion
Allatostatins	brain	corpora allata	developmental/behaviour and homeostasis—inhibit JH production
Allatotropin	brain	corpora allata	developmental/behavioural and homeostasis—stimulates JH production and release
Diuretic hormone	brain/corpora cardiaca and thoracic ganglia	Malpighian tubules and rectum	homeostasis—controls diuresis or fluid secretion
Mating inhibition hormone	accessory reproductive glands of male	brain	behavioural—prevents remating
Oviposition initiation hormone	accessory reproductive glands of male	oviduct ?	behavioural—initiates egg laying
Cardioaccelerator hormone	brain/corpora cardiaca	myocardium	homeostasis—increase in frequency and amplitude of muscle contraction
Proctolin	brain/corpora cardiaca	hindgut and possibly visceral muscle in general (heart and oviduct)	homeostasis—muscle contraction, defecation, egg-laying,

2. Hormones of Corpora Allata:

Juvenile hormone:

Juvenile hormone is produced by the corpora allata. Chemically the hormone is methyl 10-epoxy-7-ethyl-3, 11-dimethyl-2, 6-tridecadienoate in moth *Hyalophora cecropia* (Fig. 7.56A). It is likely that considerable species variability may be found in chemistry of this hormone since the corpora allata vary in functional importance.

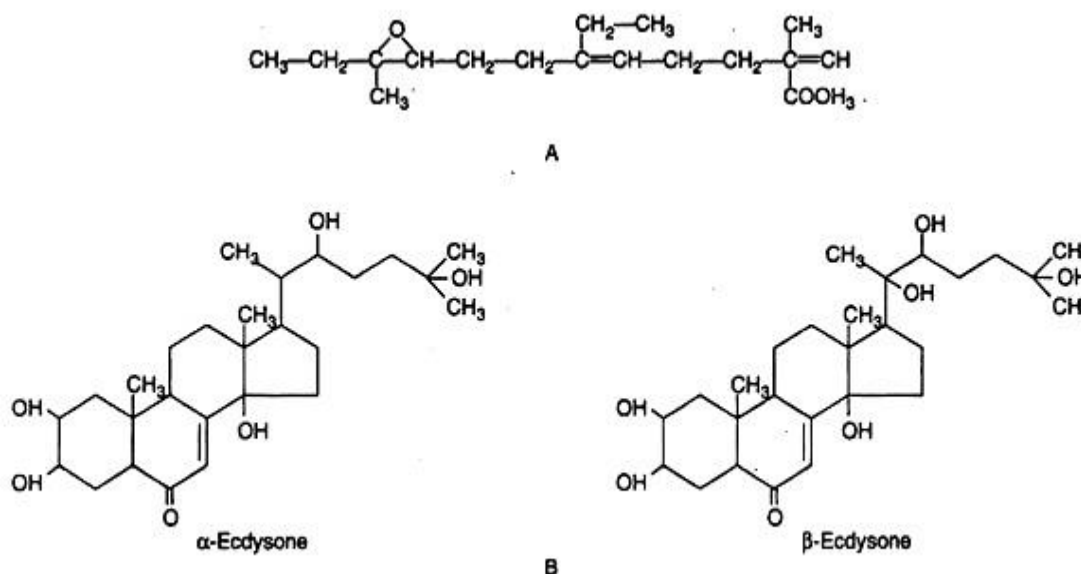


Fig. 7.56 : A. Structure of Juvenile hormone of the moth *H. cecropia*, B. Structures of ecdysones

Fig .5.11

3. Hormones of Ecdysial Gland:

Moulting hormone (Ecdysone):

Ecdysial gland secretes the moulting hormone. It is a steroid, called ecdysone. Two types of ecdysones can be synthesised by insects – α -ecdysone and β -ecdysone. The latter steroid differs from α -ecdysone only by having a hydroxyl group at position 20 (Fig. 7.56B). Similar β -ecdysone is also produced by crustacean arthropods (for functions see Table 7.21).

Functions of endocrine organs in insects:

Insect hormones and neurohormones have been studied with respect to their involvement in a number of general physiological functions (Fig. 7.57). Specifically, hormones and neurohormones influence development, diapause, mating and oviposition, metabolism, development of nervous system, control of circadian rhythms, regulation of dormancy, pheromone production and regulation of migratory behaviour.

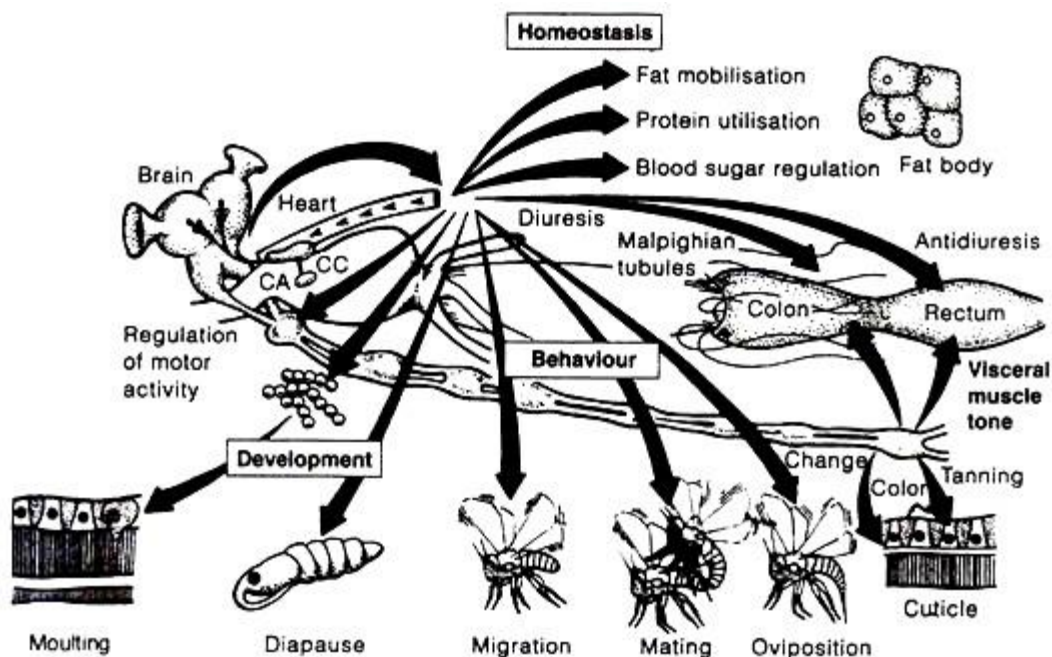


Fig. 7.57 : Major physiological functions regulated by neurohormones in insects

Fig .5.12

Endocrine Control of Growth and Metamorphosis:

Upon emergence from the egg, the immature insects gradually increase in size to reach adults through some mechanisms called moulting. Moulting involves the periodic digestion of old cuticle, secretion of new cuticle (usually with larger surface area than the older one) and shedding of undigested old cuticle.

The last step – shedding of undigested old cuticle- is commonly referred to as ecdysis. Sometimes the term moult is also used synonymously with ecdysis. A typical insect goes through a series of moults, increasing in size with each step. Each developmental stage of the insect itself is called an instar, and the interval of time passed in that instar is referred to as stadium.

The whole developmental process by which the first instar immature stage of an insect is transformed into the adult insect is called metamorphosis. Metamorphosis can occur slowly in some insects or abruptly in others. The insects are divided into groups based on the type of metamorphosis.

During metamorphosis apterygote insects undergo very minor changes in form, as the immature instars differ from the adult only in size and development of gonads and external genitalia. These insects are called ametabola and undergo ametabolous development. Members of pterygota can be divided into two groups exopterygota where wings develop externally and endopterygota where wings develop inside the body of larvae.

The metamorphosis of exopterygotes is referred to as hemimetabolous or simple or incomplete development where the immature instars, commonly referred to as nymph, resembles the adults in many respects, including the presence of compound eyes, but they lack functional wings, gonads and external genitalia.

The remaining group of pterygota, those classified as endopterygota, undergo the developmental process referred to as holometabolous development or complete metamorphosis.

In these insects, the immature instars are referred to as larvae, which are quite dissimilar to the adults and are adapted to different environmental situations. The larvae typically lack compound eyes, may have mandibulate mouthparts and may or may not have thoracic or abdominal legs. In these insects, the changes in the transformation from the last instar larva to the adult are compressed into a single intervening instar, called pupa.

In most endopterygotes, the larval instars resemble one another except for a few minor morphological details and in size. However, some holometabolous insects pass through one or more larval instars that are totally different from the others (e.g., some members of Coleoptera, Diptera). This is called hyper-metamorphosis.

Endocrine Control of Growth and Metamorphosis:

Hormones required:

Brain hormone, Ecdysone, Juvenile hormone.

Tissues involved:

Lateral neurosecretory cells of the brain, corpus cardiacum, corpora allata, prothoracic gland.

Hormonal involvement:

Protocerebrum secretes brain hormone (BH) or prothoracicotrophic hormone (PTTH) or ecdysiotropin which accumulate in the corpora allata and subsequently released into the haemolymph (except in Lepidoptera, in other insects BH is stored in corpora cardiaca). Through the haemolymph, PTTH reach to prothoracic gland and stimulate its secretory activity.

Secretion of PTTH from brain requires different stimuli in different insects. For example, in blood-sucking bug *Rhodnius*, abdominal distension resulting from feeding as well as a nutritional component of the diet stimulates secretion of PTTH from the brain. In *Locusta*, stretch receptors on the wall of pharynx seem to be involved whereas in Lepidoptera, the increasing weight of larva was thought to be the cue.

The prothoracic glands secrete α -ecdysone or moulting hormone (MH) which through haemolymph reach the target (epidermis) and is converted into active hormone 20-hydroxyecdysone, which initiates the growth and moulting activities of the cells.

Ecdysone favours the development of adult structures and favours the moulting processes that terminate into successive larval instars. During pupal stage, ecdysone is needed for differentiation of the adult structures and the final pupal moult.

The corpora allata secrete juvenile hormone (JH), which promote larval development and inhibit development of adult characteristics. It has been described to have a “status quo” effect, which implies that it is more of an inhibitory substance than an active growth factor (Williams).

During the early larval instars, both MH and JH are produced prior to moult. In fact, JH interacts with MH to stimulate larval maturation during each stage of development. The concentration of JH evidently decreases toward the end of a larval instar, allowing the ecdysone to cause moulting.

The total picture here should be one of balanced interaction-synergism—between these two hormones to induce normal growth and differentiation, rather than a simple antagonism.

During the last immature instar, two separate and distinct peaks of ecdysone are present in both the holometabola and hemimetabola. The first one is low and in absence of JH, the epidermal cells are reprogrammed from larval to pupal commitment in holometabolous insects (Fig. 7.58) and from nymphal to adult stage in hemimetabolous insects.

Neuroendocrine System

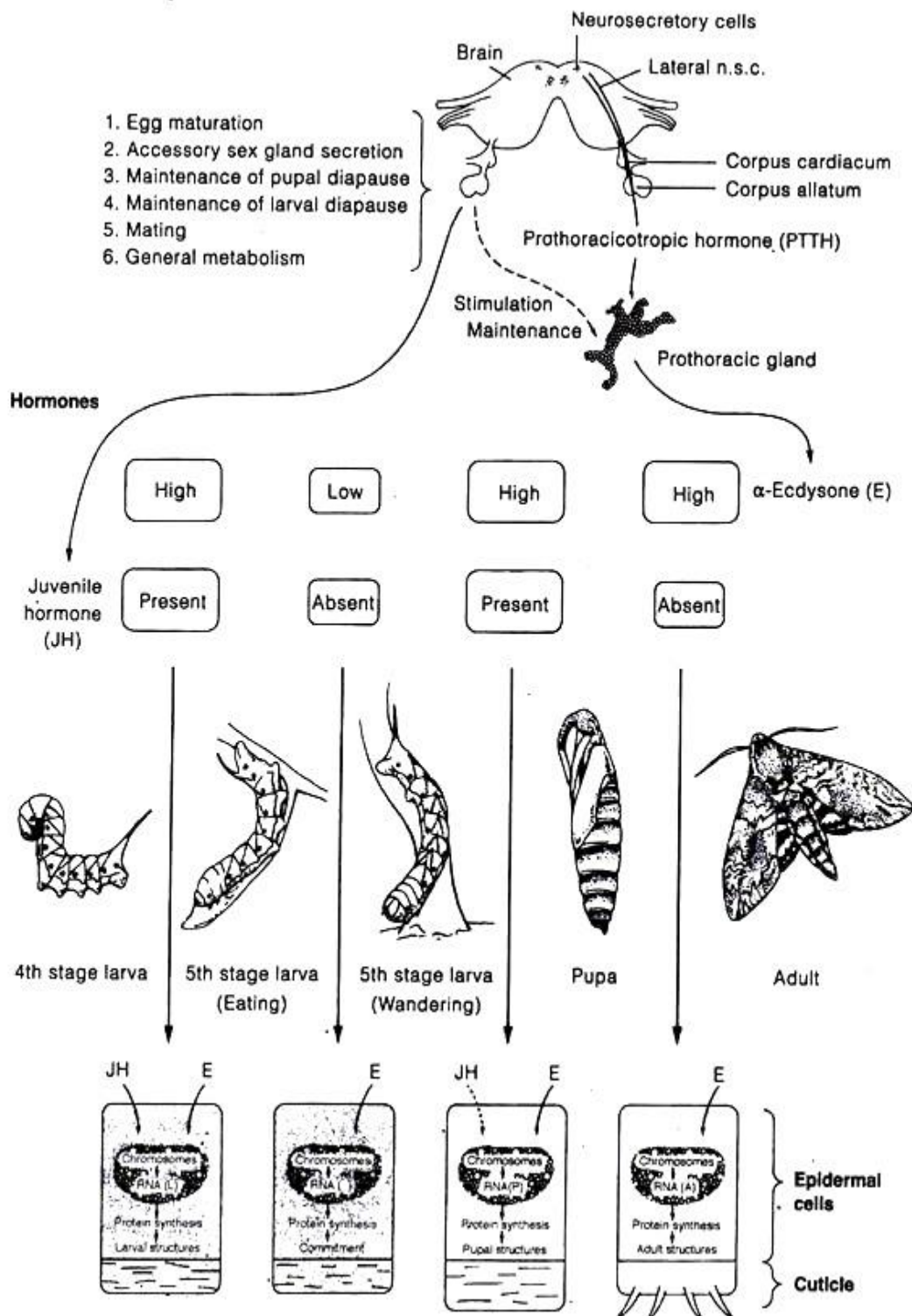


Fig. 7.58 : Hormonal control of development and metamorphosis in insect

Fig .5.13

The second ecdysone peak being high causes moulting (i.e. pupa in holometabolous form) in association with JH. The presence of JH at this stage prevents the imaginal discs (which have been growing slowly in the larval stages) from developing into adult structures during the

pupal stage. Finally, the next high peak of ecdysone in the absence of JH causes adult development.

In hemimetabolous insects, there is a gradual progression toward adult stage, but there are also two ecdysone peaks prior to adult moult. In holometabolous form, on the other hand, the changes from immature to adult are compressed into the pupal stage. Thus, other than the pupal stage, there are no significant differences in the basic physiological processes controlling growth and metamorphosis in either of these two groups.

Molecular mechanism:

Ecdysone acts on several genes through receptor mediated processes and as a result, influences the synthesis of a number of enzymes as well as structural proteins. It has been shown that in *Chironomus* larvae, ecdysone produces puffing patterns in chromosomes identical to those patterns that occur during pupation. The puffing areas are the regions of newly synthesised mRNA. Ecdysone is thought to activate a gene that directs the synthesis of key enzyme of sclerotisation process.

In *Drosophila*, ecdysone was shown to cause two puffing patterns. First, it combines with ecdysone receptor, which in turn, causes early puff patterns. These early puff produces proteins that activate late puff patterns and also inhibit protein synthesis of the early puffs. At the same time, the late puff proteins are initially inhibited by the ecdysone.

The mode of action of JH is not known clearly, but is suggested that the hormone may activate or repress target gene or genes by binding with a specific receptor on a regulatory sequence of the DNA. It also acts by altering the number of ecdysone receptors present in a target tissue and JH may also influence the rate of target gene transcription in both larvae and adults.

Role of other hormones in metamorphosis:

Eclosion:

Eclosion hormone or EH is released from brain by a circadian clock and declining ecdysteroid titers. If ecdysone titer is artificially kept high, the release of eclosion and its activity are inhibited. This hormone influences many aspects of pupal-adult ecdysis, including the behaviour associated with ecdysis and subsequent degeneration of abdominal inter-segmental muscles used in the act of ecdysis.

Isolation of eclosion hormone gene from different insects suggested that EH hormone as well as the mechanism by which ecdysis behaviour is triggered is conserved among insects.

Ecdysis triggering hormone:

It is the most recent hormone discovered that plays an important role in ecdysis. This 26 amino acid peptide hormone is synthesised by the epitracheal glands that are located segmentally in larvae, pupae and adults of *Manduca sexta*. According to Zitnan (1996), this hormone may act upstream from the eclosion hormone in a series of cascade events leading to ecdysis.

Bursicon (Tanning hormone):

Bursicon, commonly found in neurohaemal organs associated with the ventral chain ganglia is suggested to stimulate tanning and sclerotisation of the cuticle following ecdysis.

Hormonal control of reproduction:

Like other higher multicellular organisms, reproduction in insects is a complex process. Different stages of reproduction, starting from the production of male and female gametes to oviposition, are seem to be influenced by several hormones.

(i) Spermatogenesis:

Ecdysone controls the permeability of the testis walls to the humoral factor differentiating the spermatocytes. Juvenile hormone is shown to have some inhibitory effects on spermatogenesis in many insects.

(ii) Vitellogenesis:

Vitellogenesis or egg yolk synthesis is also known to depend on JH from the corpora allata. In mosquitoes, juvenile hormone is required for egg development only during the early previtellogenic stages of development of the follicles. It promotes the growth of existing primary follicles up to the “resting stage”. The allatohibin (20-HE) from the ovary has two important effects.

It promotes early growth of secondary follicles leading to their separation as identifiable follicles, and is also important in initiating and sustaining synthesis and release from the fat body of vitellogenin. The third hormone necessary for ovarian follicular development is egg development neurosecretory hormone (EDNH). This peptide from the brain, controls ecdysone synthesis by ovary.

(iii) Oogenesis:

The complex process of oogenesis differs among species. However, role of brain neurosecretory cells, ecdysone, corpora allata and ovary has been postulated in general. Hormones from corpora allata help in egg maturation through the incorporation of yolk into the oocyte.

Some substances like farnesol and farnesyl methyl ether can mimic the effects of allata hormone and have a gonadotropic action. The secretions from the median neurosecretory cells of brain stimulate corpus allatum and protein synthesis (required for yolk formation).

In addition to secretions from brain cells and corpora allata, ecdysone has been found to be involved in control of oogenesis in female mosquitoes. Following a blood meal, lateral neurosecretory cells secrete egg development neurosecretory hormone, which in turn, induces the ovary to secrete ecdysone. Ecdysone, in turn triggers the synthesis of yolk protein vitellogenin in the fat bodies. Juvenile hormones secreted by corpora allata also activate fat body and ovaries.

(iv) Fertilization:

In many insects studied, ovulation (the passage of egg from the ovary into the oviduct) and oviposition, (passage of fertilized eggs to the outside, are closely linked. Both these events are affected by some peptides secreted by male accessory glands and neurosecretory products of brain. In *Rhodnius*, ovulation is controlled by a myotropic peptide originating in 10 identified neurosecretory cells of the pars intercerebralis.

The process of reproduction involves both the nervous and endocrine systems. The major centres are the neurosecretory cells of brain and the major events are the secretion of juvenile hormone by corpora allata, and either ecdysone production by ecdysial gland in immature insects or ecdysone biosynthesis by the ovary in adult insects. Both hormones act either independently or together in association with nervous system to make reproduction success (Fig. 7.59).

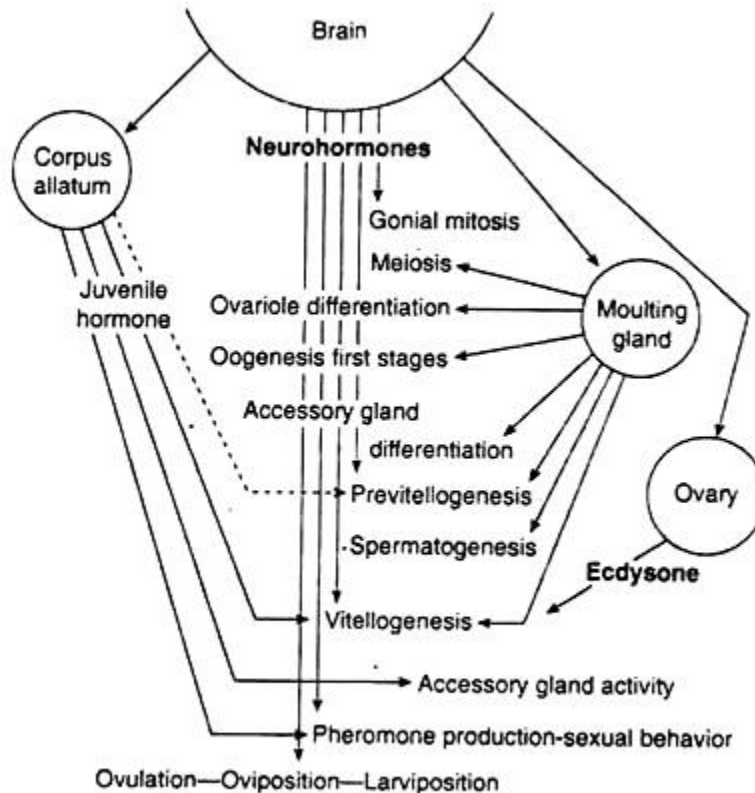


Fig. 7.59 : Hormonal control of reproductive events in insect

Fig .5.14

Hormonal Control of General Body Function:

Digestion and Nutrition:

In some insects movements of alimentary canal that complement the action of digestive enzymes and absorption of food is reported to be controlled partly by neurosecretory cells. In cockroaches, proctolin, a neurohormone, regulates peristalsis of hindgut. In Diptera, production and secretion of saliva are under control of a neurohormone (supposed to be 5-hydroxytryptamine, 5HT).

Circulation:

Eclosion is known to control the eclosion heart-beat. At the time of adult eclosion from the pupal case and cocoon, the eclosion hormone influences cardio acceleration, which lasts only for 75 minutes of the eclosion period.

Excretion:

The production of urine in insects is controlled by diuretic or antidiuretic hormones that are synthesised by pars intercerebralis of brain, corpus cardiacum, ventral chain ganglia and sub-esophageal ganglia. In Locusta, an antidiuretic hormone and a chloride transport-stimulating hormone have been shown to regulate both ion and water balance. In Periplaneta, proctolin is

responsible for the hindgut motility which also acts as a neuromodulator helping in the excretion process.

Hormonal Control of Metabolism:

Lipid metabolism:

In most insects, lipid remains stored in the fat body, an organ often suggested to be analogous to mammalian liver. Many hormones in different insects are known to stimulate lipid content of haemolymph. The adipokinetic hormone or AKH released from corpora cardiaca and prawn red pigment concentrating hormone (PRCH), an octapeptide have considerable adipokinetic activity. Interestingly, in cockroaches, AKH has no adipokinetic effect. In Locusta, storage of lobe of corpora cardiaca produces a hypolipartric factor that opposes the action of AKH.

Carbohydrate metabolism:

In mosquitoes, median neurosecretory cell hormone (MNCH) suppresses glycogen synthesis. Diapause hormone is suggested to stimulate glycogen synthesis during diapause. Hormones secreted by corpora cardiaca inhibit oxidation of glucose in many insects.

Protein metabolism:

In insects hormonal control of protein metabolism has not been studied in detail (except for the tanning factors). However, it is reasonable to assume that some hormones may directly or indirectly influence the metabolism of amino acids in general.

Hormonal control of behaviour:

Hormones play a very important role in insect behaviour. They either act as modifiers or as releasers of behaviour. As a modifier, a hormone alters the responsiveness of an organism. For example, the influence of ecdysone on the biting behaviour of female Anopheles, which does not take blood meals once ovarian development, has been initiated.

Ecdysone secreted by ovaries, inhibits biting when a hormone acts as a releaser, a specific behavioural pattern is exhibited within a few minutes of the secretion of that hormone. For example, ecdysis-triggering hormone and eclosion hormone in the moth *Antheraea*, act both as releasers in triggering the pre-eclosion behaviour and as modifiers in 'turning on' adult behaviour.

Migration:

Migration in some insects occurs on the basis of endocrine changes correlated with particular environmental effects, such as crowding, food deficiency, and short day. For example, in

aphids, crowding results in the production of winged forms (alate) instead of wingless, non-migrant (apterous) forms.

This is associated with the activity of corpus allatum. It has also been suggested that migratory behaviours depend on a particular balance between ecdysone and juvenile hormone in the haemolymph.

Dormancy:

In response to the changes in the abiotic environment, insect development and general activity may undergo two kinds of suppression or dormancy. In response to adverse environmental condition, insects may slowdown metabolism and development; when conditions are no longer adverse, both functions resume immediately. This type of dormancy is referred to as quiescence.

Insects may enter into a state of metabolic and developmental arrest in response to certain environmental conditions which may or may not be adverse, but serve as indicators of the imminent onset of adverse condition. Development does not necessarily resume immediately with the return of favourable conditions. This type of dormancy is called diapause.

Diapause is controlled by hormones. The activity of the prothoracic gland is required for the termination of post embryonic diapause in silk moth, *Platysamia*. In other moths like *Bombyx* and *Phalaenoides*, a secretion from the sub-esophageal ganglia of the females induces diapause in the embryos. The arrest of development in larval and pupal diapause has classically been ascribed to an arrest of PTTH secretion.

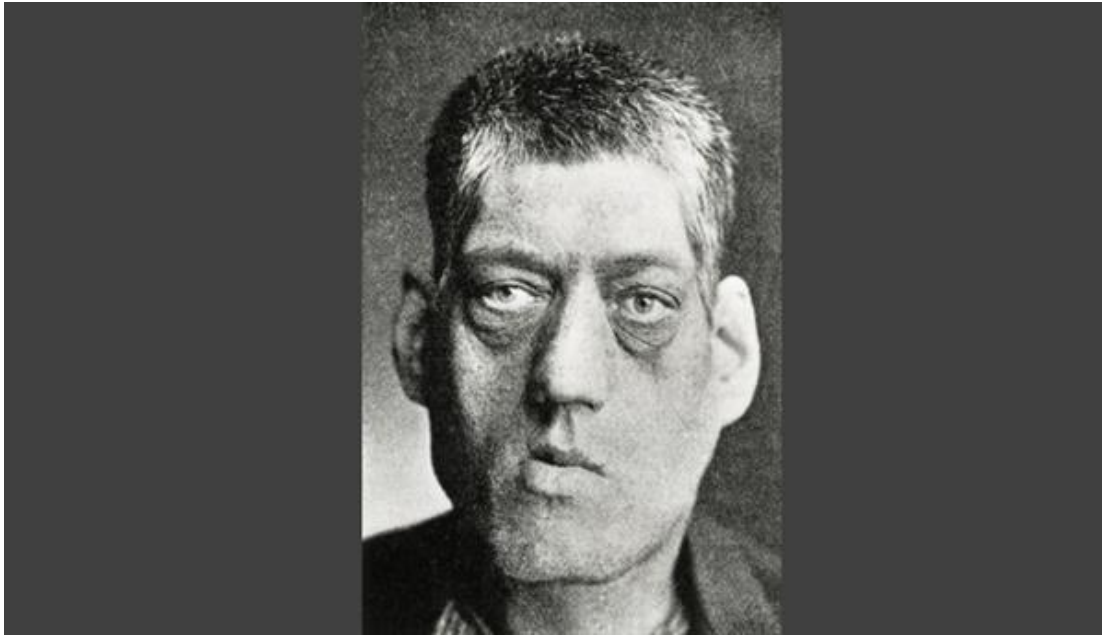In some species, the biological clock directly regulates PTTH secretion by a mechanism located entirely within the brain while in other species PTTH secretion may be restrained by high levels of JH. Indeed, high JH levels during larval diapause lead to the invocation of JH in regulation of PTTH release in non-diapausing moults. In some parasitic insects, development is closely attuned to the hormonal changes in the host. In these insects, diapause is induced in synchrony with diapause in the host.

5.8 Endocrine disorders (photographs)

Types of Endocrine Disorders

There are many different types of endocrine disorders.

1- Acromegaly.



Acromegaly.*Fig .5.14*

Acromegaly is a hormonal disorder that develops when your pituitary gland produces too much growth hormone during adulthood.

When you have too much growth hormone, your bones increase in size. In childhood, this leads to increased height and is called gigantism. But in adulthood, a change in height doesn't occur. Instead, the increase in bone size is limited to the bones of your hands, feet and face, and is called acromegaly.

Symptoms

- Enlarged hands and feet
- Enlarged facial features, including the facial bones, lips, nose and tongue
- Coarse, oily, thickened skin
- Excessive sweating and body odor
- Small outgrowths of skin tissue (skin tags)
- Fatigue and joint or muscle weakness
- Pain and limited joint mobility
- A deepened, husky voice due to enlarged vocal cords and sinuses
- Severe snoring due to obstruction of the upper airway
- Vision problems

- Headaches, which may be persistent or severe
- Menstrual cycle irregularities in women
- Erectile dysfunction in men
- Loss of interest in sex

Treatment

Acromegaly treatment varies by person. Your treatment plan will likely depend on the location and size of your tumor, the severity of your symptoms, and your age and overall health.

To help lower your GH and IGF-1 levels, treatment options typically include surgery or radiation to remove or reduce the size of the tumor that is causing your symptoms, and medication to help normalize your hormone levels.

If you're experiencing health problems as a result of acromegaly, your doctor may recommend additional treatments to help manage your complications.

Surgery

Doctors can remove most pituitary tumors using a method called transsphenoidal surgery. During this procedure, your surgeon works through your nose to remove the tumor from your pituitary gland. If the tumor causing your symptoms isn't located on your pituitary gland, your doctor will recommend another type of surgery to remove the tumor.

In many cases — especially if your tumor is small — removal of the tumor returns your GH levels to normal. If the tumor was putting pressure on the tissues around your pituitary gland, removing the tumor also helps relieve headaches and vision changes.

In some cases, your surgeon may not be able to remove the entire tumor. If this is the case, you may still have elevated GH levels after surgery. Your doctor may recommend another surgery, medications or radiation treatments.

Medications

Your doctor may recommend one of the following medications — or a combination of medications — to help your hormone levels return to normal:

- **Drugs that reduce growth hormone production (somatostatin analogues).** In the body, a brain hormone called somatostatin works against (inhibits) GH production. The drugs octreotide (Sandostatin) and lanreotide (Somatuline Depot) are man-made (synthetic) versions of somatostatin. Taking one of these drugs signals the pituitary gland

to produce less GH, and may even reduce the size of a pituitary tumor. Typically, these drugs are injected into the muscles of your buttocks (gluteal muscles) once a month by a health care professional.

- **Drugs to lower hormone levels (dopamine agonists).** The oral medications cabergoline and bromocriptine (Parlodel) may help lower levels of GH and IGF-1 in some people. These drugs may also help decrease tumor size. To treat acromegaly, these medications usually need to be taken at high doses, which can increase the risk of side effects. Common side effects of these drugs include nausea, vomiting, stuffy nose, tiredness, dizziness, sleep problems and mood changes.
- **Drug to block the action of GH (growth hormone antagonist).** The medication pegvisomant (Somavert) blocks the effect of GH on the body's tissues. Pegvisomant may be particularly helpful for people who haven't had good success with other treatments. Given as a daily injection, this medication can help lower IGF-1 levels and relieve symptoms, but it doesn't lower GH levels or reduce tumor size.

Radiation

If your surgeon wasn't able to remove the whole tumor during surgery, your doctor may recommend radiation treatment. Radiation therapy destroys any lingering tumor cells and slowly reduces GH levels. It may take years for this treatment to noticeably improve acromegaly symptoms.

Radiation treatment often lowers levels of other pituitary hormones, too — not just GH. If you receive radiation treatment, you'll likely need regular follow-up visits with your doctor to make sure that your pituitary gland is working properly, and to check your hormone levels. This follow-up care may last for the rest of your life.

2- Adrenal Insufficiency & Addison's Disease.

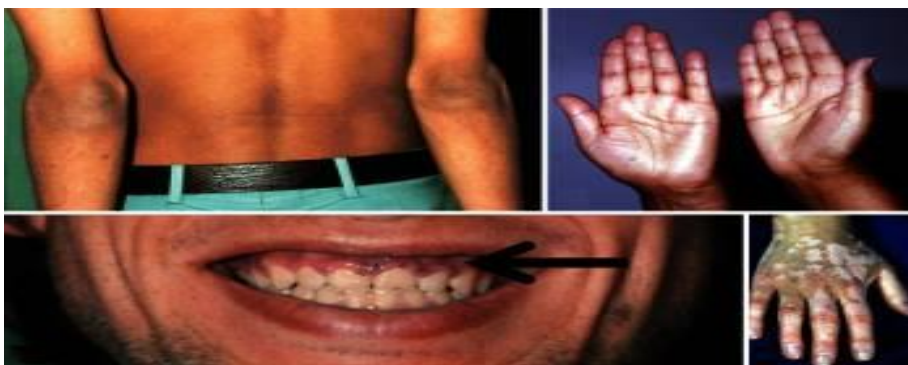

Fig .5.15
Adrenal Insufficiency & Addison's Disease.

adrenal insufficiency

Adrenal insufficiency is a disorder that occurs when the adrenal glands don't make enough of certain hormones. The adrenal glands are located just above the kidneys. Adrenal insufficiency can be primary, secondary, or tertiary. Primary adrenal insufficiency is often called Addison's disease.

Adrenal insufficiency can affect your body's ability to respond to stress and maintain other essential life functions. With treatment, most people with adrenal insufficiency can have a normal, active life.

Addison's disease

Addison's disease occurs when the adrenal glands are damaged and can't make enough of the hormone cortisol and sometimes the hormone aldosterone.

Secondary adrenal insufficiency

Secondary adrenal insufficiency starts in the pituitary—a pea-sized gland at the base of the brain. The pituitary makes adrenocorticotropin (ACTH), a hormone that tells the adrenal glands to make cortisol. If the pituitary doesn't make enough ACTH, the adrenal glands don't make enough cortisol. Over time, the adrenal glands can shrink and stop working.

Tertiary adrenal insufficiency

Tertiary adrenal insufficiency starts in the hypothalamus, a small area of the brain near the pituitary. The hypothalamus makes corticotropin-releasing hormone (CRH), a hormone that tells the pituitary to make ACTH. When the hypothalamus doesn't make enough CRH, the pituitary gland doesn't make enough ACTH. In turn, the adrenal glands don't make enough cortisol.

Symptoms and causes-The most common symptoms are fatigue, muscle weakness, loss of appetite, weight loss, and abdominal pain. Adrenal insufficiency can be caused by autoimmune disease or suddenly stopping steroid medicines used to treat other conditions, among other causes.

Treatment-

Doctors treat adrenal insufficiency with medicines that replace the hormones your body isn't making. Your doctor will adjust your dose in special situations, such as during surgery, illness, or pregnancy; or after a serious injury.

3- Cushing's Syndrome- Cushing syndrome from endogenous cortisol production can be difficult to diagnose because other conditions have similar signs and symptoms. Diagnosing Cushing syndrome can be a long and extensive process. You'll likely need to see a doctor who specializes in hormonal disorders (endocrinologist).

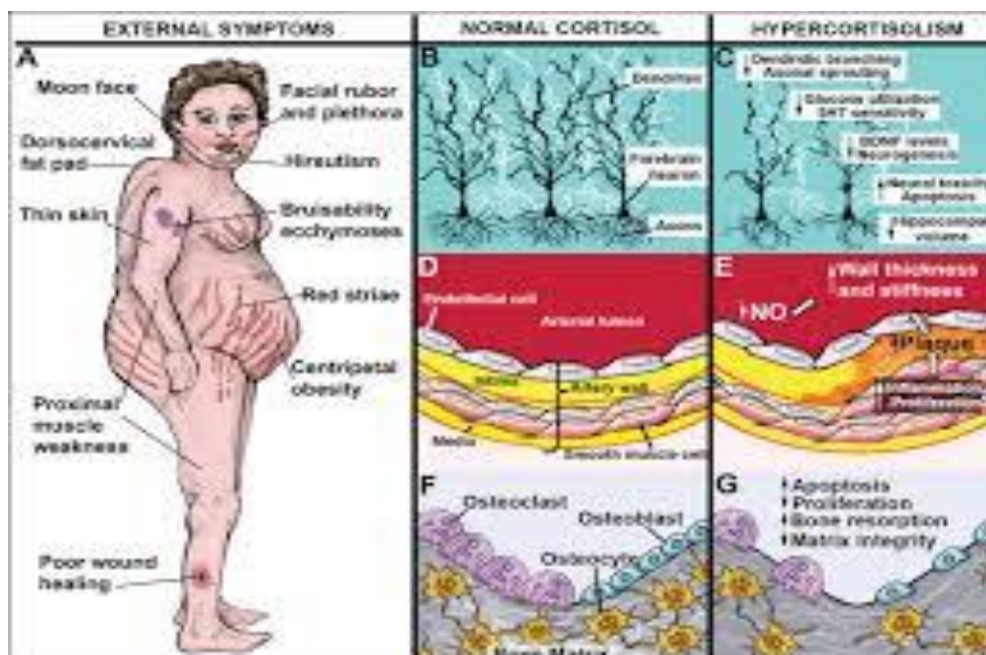


Fig .5.16

Cushing's Syndrome.

Treatment

Treatments for Cushing syndrome are designed to lower the high level of cortisol in your body. The best treatment for you depends on the cause of the syndrome. Options include:

Reducing corticosteroid use

If the cause of Cushing syndrome is long-term use of corticosteroid medications, your doctor may be able to keep your Cushing syndrome signs and symptoms under control by reducing the dosage of the drug over a period of time, while still managing the condition for which you take it. Don't reduce the dose of corticosteroid drugs or stop taking them on your own. Do so only under your doctor's supervision.

Abruptly discontinuing these medications could lead to deficient cortisol levels. Slowly tapering off corticosteroid drugs allows your body to resume normal cortisol production.

Surgery

If the cause of Cushing syndrome is a tumor, your doctor may recommend complete surgical removal. Pituitary tumors are typically removed by a neurosurgeon, who may perform the procedure through your nose. For a tumor in the adrenal glands, lungs or pancreas, the surgeon can remove it through a standard operation or by using minimally invasive surgical techniques, with smaller incisions.

After the operation, you'll need to take cortisol replacement medications to provide your body with the correct amount of cortisol. In most cases, you'll eventually return to normal adrenal hormone production, and your doctor can taper off the replacement drugs. Your endocrinologist will use blood tests to help determine if you need cortisol replacement and when it may be stopped.

However, this process can take up to a year or longer. In some instances, people with Cushing syndrome never return to normal adrenal function. They then need lifelong replacement therapy.

Radiation therapy

If the surgeon can't totally remove a pituitary tumor, he or she will usually prescribe radiation therapy as well as surgery. Additionally, radiation may be used for people who aren't suitable candidates for surgery.

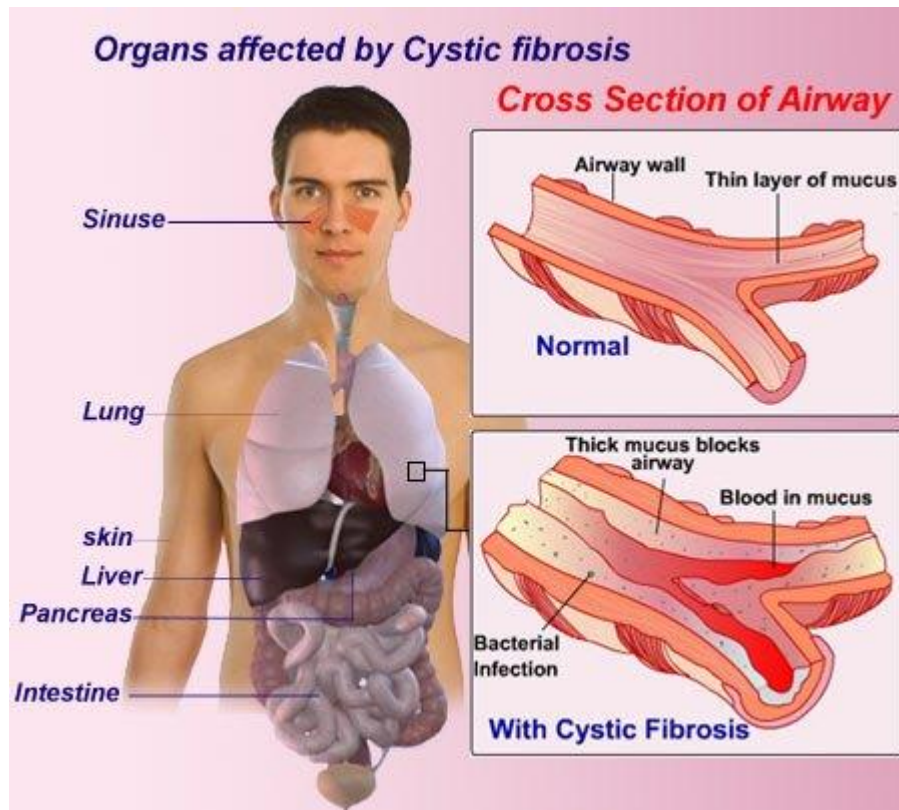
Radiation can be given in small doses over a six-week period, or with a technique called stereotactic radiosurgery. In the latter procedure, a large, one-time dose of radiation is delivered to the tumor, and the radiation exposure to surrounding tissues is minimized.

Medications.

4- Cystic Fibrosis link-

conditions caused by cystic fibrosis include:

- Nasal and sinus surgery. Your doctor may recommend surgery to remove nasal polyps that obstruct breathing. ...
- Oxygen therapy. ...
- Noninvasive ventilation. ...
- Feeding tube. ...
- Bowel surgery. ...
- Lung transplant. ...
- Liver transplant.



Cystic Fibrosis link.*Fig .5.17*

Treatment

There is no cure for cystic fibrosis, but treatment can ease symptoms, reduce complications and improve quality of life. Close monitoring and early, aggressive intervention is recommended to slow the progression of CF, which can lead to a longer life.

Managing cystic fibrosis is complex, so consider getting treatment at a center with a multispecialty team of doctors and medical professionals trained in CF to evaluate and treat your condition.

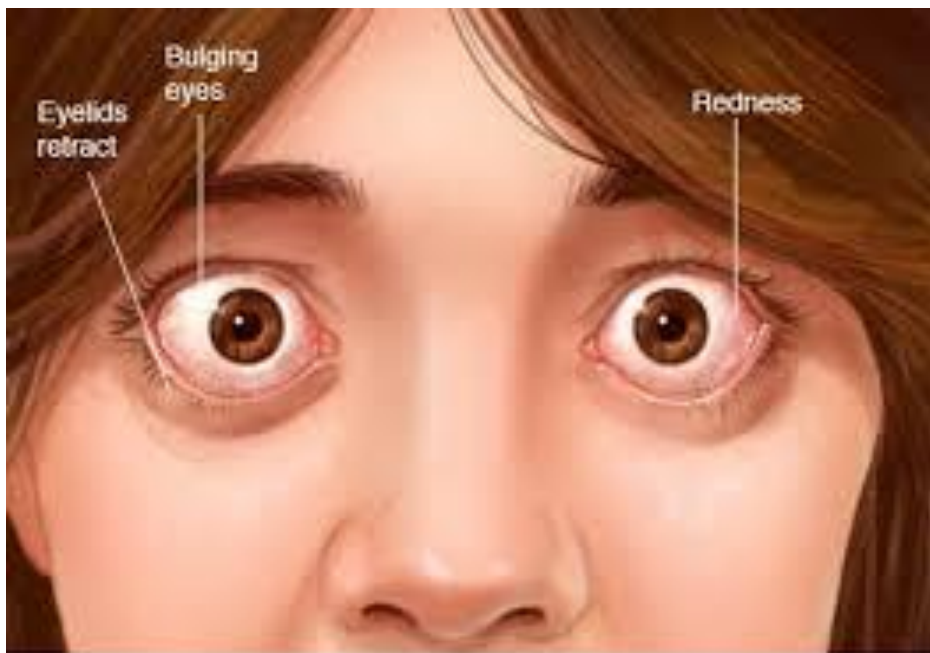The goals of treatment include:

- Preventing and controlling infections that occur in the lungs
- Removing and loosening mucus from the lungs
- Treating and preventing intestinal blockage
- Providing adequate nutrition.

6- Graves 'disease.

Graves' disease is an autoimmune disorder that can cause hyperthyroidism, or overactive thyroid. The thyroid is a small, butterfly-shaped gland in the front of your neck. Thyroid hormones control the way your body uses energy, so they affect nearly every organ in your body, even the way your heart beats. With Graves' disease, your immune system attacks your thyroid gland, causing it to make more thyroid hormones than your body needs. As a result, many of your body's functions speed up.

Graves' disease often causes symptoms of hyperthyroidism. Graves' disease can also affect your eyes and skin. Symptoms can come and go over time.



© MAYO FOUNDATION FOR MEDICAL EDUCATION AND RESEARCH. ALL RIGHTS RESERVED.

Graves' Disease. *Fig .5.17*

Hyperthyroidism

Symptoms of hyperthyroidism can vary from person to person and may include⁵

- weight loss, despite an increased appetite
- rapid or irregular heartbeat
- nervousness, irritability, trouble sleeping, fatigue
- shaky hands, muscle weakness
- sweating or trouble tolerating heat
- frequent [bowel movements](#)
- an enlarged thyroid gland, called a [goiter](#)

Treatment-

Your thyroid uses iodine to make thyroid hormones. If you have Graves' disease or another autoimmune thyroid disorder, you may be sensitive to harmful side effects from too much iodine in your diet. Eating foods that have large amounts of iodine—such as kelp, dulse, or other kinds of seaweed—may cause or worsen hyperthyroidism. Taking iodine supplements can have the same effect.

Talk with your health care professional about

- what foods to limit or avoid
- any iodine supplements you take
- any cough syrups or multivitamins you take, because some may contain iodine

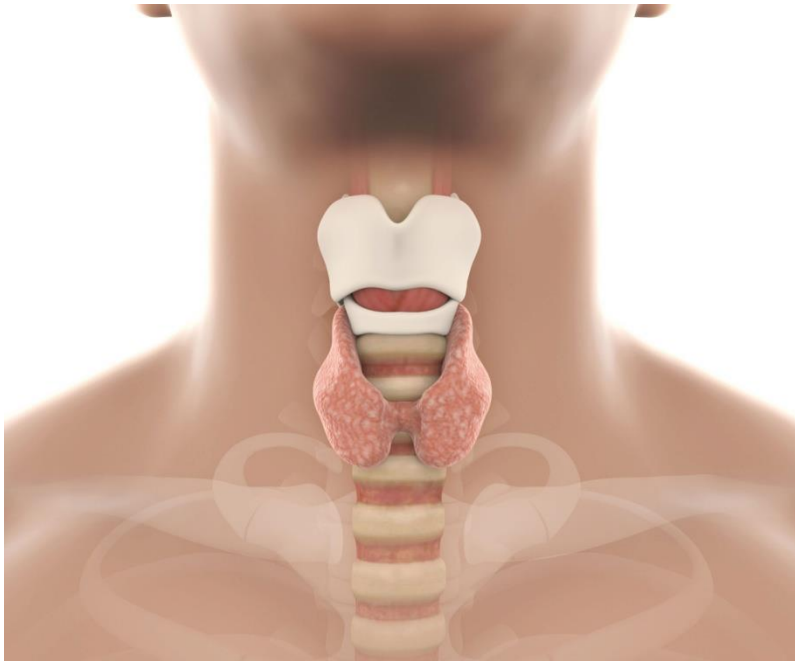7 Hashimoto's Disease-

Hashimoto's disease is an autoimmune disorder that can cause hypothyroidism or underactive thyroid. Rarely, the disease can cause hyperthyroidism or overactive thyroid.

The thyroid is a small, butterfly-shaped gland in the front of your neck. In people with Hashimoto's disease

- the immune system makes antibodies that attack the thyroid gland
- large numbers of white blood cells, which are part of the immune system, build up in the thyroid
- the thyroid becomes damaged and can't make enough thyroid hormones

Thyroid hormones control how your body uses energy, so they affect nearly every organ in your body—even the way your heart beats.



Hashimoto's Disease **Fig .5.18**

Symptoms

Many people with Hashimoto's disease have no symptoms at first. As the disease progresses, you may have one or more of the symptoms of hypothyroidism.

Some common symptoms of hypothyroidism include

- fatigue
- weight gain
- trouble tolerating cold
- joint and muscle pain
- constipation
- dry skin or dry, thinning hair
- heavy or irregular menstrual periods or fertility problems
- slowed heart rate
- **Treatment-**

The thyroid uses iodine, a mineral in some foods, to make thyroid hormones. However, if you have Hashimoto's disease or other types of autoimmune thyroid disorders, you may be sensitive to harmful side effects from iodine. Eating foods that have large amounts of iodine—such as kelp, dulse, or other kinds of seaweed, and certain iodine-rich medicines—may cause hypothyroidism or make it worse. Taking iodine supplements can have the same effect.

8-Goiter-

A goiter (GOI-tur) is the irregular growth of the thyroid gland. The thyroid is a butterfly-shaped gland located at the base of the neck just below the Adam's apple. A goiter may be an overall enlargement of the thyroid, or it may be the result of irregular cell growth that forms one or more lumps (nodules) in the thyroid. A goiter may be associated with no change in thyroid function or with an increase or decrease in thyroid hormones.

The most common cause of goiters worldwide is a lack of iodine in the diet. In the United States, where the use of iodized salt is common, goiters are caused by conditions that change thyroid function or factors that affect thyroid growth. Treatment depends on the cause of the goiter, symptoms, and complications resulting from the goiter. Small goiters that aren't noticeable and don't cause problems usually don't need treatment.



Goiter Fig .5.19

Symptoms

Most people with goiters have no signs or symptoms other than a swelling at the base of the neck. In many cases, the goiter is small enough that it's only discovered during a routine medical exam or an imaging test for another condition.

Other signs or symptoms depend on whether thyroid function changes, how quickly the goiter grows and whether it obstructs breathing.

Underactive thyroid (hypothyroidism)

Signs and symptoms of hypothyroidism include:

- Fatigue
- Increased sensitivity to cold
- Increased sleepiness
- Dry skin
- Constipation
- Muscle weakness
- Problems with memory or concentration

Overactive thyroid (hyperthyroidism)

Signs and symptoms of hyperthyroidism include:

- Weight loss
- Rapid heartbeat (tachycardia)
- Increased sensitivity to heat
- Excess sweating
- Tremors
- Irritability and nervousness
- Muscle weakness
- Frequent bowel movements
- Changes in menstrual patterns
- Sleep difficulty
- High blood pressure
- Increased appetite

Children with hyperthyroidism might also have the following:

- Rapid growth in height

- Changes in behavior
- Bone growth that outpaces expected growth for the child's age

Obstructive goiter

The size or position of a goiter may obstruct the airway and voice box. Signs and symptoms may include:

- Difficulty swallowing
- Difficulty breathing with exertion
- Cough
- Hoarseness
- Snoring

Causes of goiter

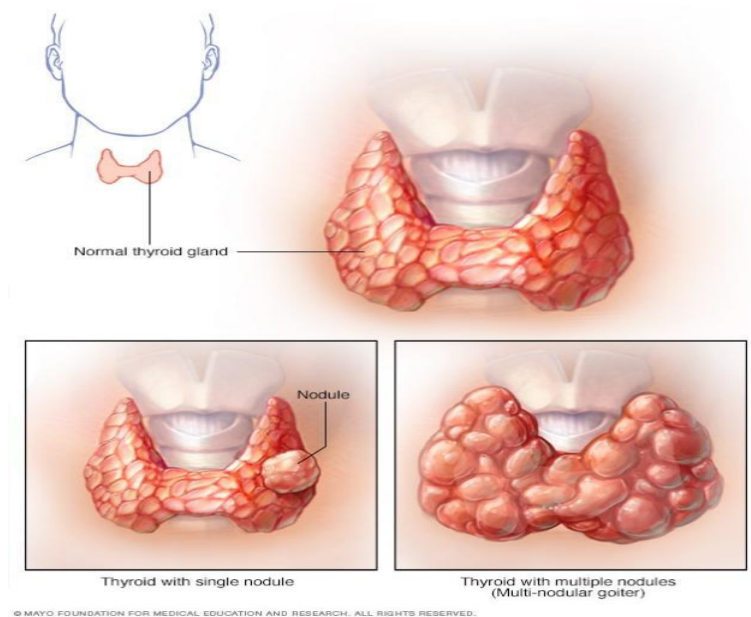


Fig .5.20
Thyroid nodules

A number of factors that influence thyroid function or growth can result in a goiter.

- **Iodine deficiency.** Iodine is essential for the production of thyroid hormones. If a person does not get enough dietary iodine, hormone production drops and the pituitary gland signals the thyroid to make more. This increased signal results in thyroid growth. In the United States, this cause is uncommon because of iodine added to table salt.

- **Hashimoto's disease.** Hashimoto's disease is an autoimmune disorder, an illness caused by the immune system attacking healthy tissues. The damaged and inflamed tissues of the thyroid don't produce enough hormones (hypothyroidism). When the pituitary gland detects the decline and prompts the thyroid to create more hormones, the thyroid can become enlarged.
- **Graves' disease.** Another autoimmune disorder called Graves' disease occurs when the immune system produces a protein that mimics TSH. This rogue protein prompts the thyroid to overproduce hormones (hyperthyroidism) and can result in thyroid growth.
- **Thyroid nodules.** A nodule is the irregular growth of thyroid cells that form a lump. A person may have one nodule or several nodules (multinodular goiter). The cause of nodules is not clear, but there may be multiple factors — genetics, diet, lifestyle and environment. Most thyroid nodules are noncancerous (benign).
- **Thyroid cancer.** Thyroid cancer is less common than other cancers and generally treatable. About 5% of people with thyroid nodules are found to have cancer.
- **Pregnancy.** A hormone produced during pregnancy, human chorionic gonadotropin (HCG), may cause the thyroid gland to be overactive and enlarge slightly.
- **Inflammation.** Thyroiditis is inflammation of the thyroid caused by an autoimmune disorder, bacterial or viral infection, or medication. The inflammation may cause hyperthyroidism or hypothyroidism.

Treatment

Goiter treatment depends on the size of the goiter, your signs and symptoms, and the underlying cause. If your goiter is small and your thyroid function is healthy, your health care provider may suggest a wait-and-see approach with regular checkups.

Medications

Medications for goiters may include one of the following:

- **For increasing hormone production.** An underactive thyroid is treated with a thyroid hormone replacement. The drug levothyroxine (Levoxyl, Thyquidity, others) replaces T-4 and results in the pituitary gland releasing less TSH. The drug liothyronine (Cytomel) may be prescribed as a T-3 replacement. These treatments may decrease the size of the goiter.
- **For reducing hormone production.** An overactive thyroid may be treated with an anti-thyroid drug that disrupts hormone production. The most commonly used drug, methimazole (Tapazole), may also reduce the size of the goiter.

- **For blocking hormone activities.** Your health care provider may prescribe a drug called a beta blocker for managing symptoms of hyperthyroidism. These drugs — including atenolol (Tenormin), metoprolol (Lopressor) and others — can disrupt the excess thyroid hormones and lower symptoms.
- **For managing pain.** If inflammation of the thyroid results in pain, it's usually treated with aspirin, naproxen sodium (Aleve), ibuprofen (Advil, Motrin IB, others) or related pain relievers. Severe pain may be treated with a steroid.

Surgery

You may need surgery to remove all or part of your thyroid gland (total or partial thyroidectomy) may be used to treat goiter with the following complications:

- Difficulty breathing or swallowing
- Thyroid nodules that cause hyperthyroidism
- Thyroid cancer

You may need to take thyroid hormone replacement, depending on the amount of thyroid removed.

Radioactive iodine treatment

Radioactive iodine is a treatment for an overactive thyroid gland. The dose of radioactive iodine is taken orally. The thyroid takes up the radioactive iodine, which destroys cells in the thyroid. The treatment lowers or eliminates hormone production and may decrease the size of the goiter.

As with surgery, you may need to take thyroid hormone replacement to maintain the appropriate levels of hormones.

5.9 Summary

Developmental biology displays a rich array of material and conceptual practices that can be analyzed to better understand the scientific reasoning exhibited in experimental life science. This entry briefly reviews some central phenomena of ontogeny and then explores four domains that represent some of the import and promise of conceptual reflection on the epistemology of developmental biology. In this unit we are learn about egg, development stages of frog, development stages of chick embryos and process of window formation in egg.

Endocrinology is the study of hormones. Hormones are essential for our every-day survival. They control our temperature, sleep, mood, stress, growth and more. . In this unit we are learn about endocrine glands of rat, endocrine glands of insects and endocrine disorders in mammals.

5.10 Terminal questions and answers-

Q1- Write to short notes on study of eggs in yours practical file.

Q2- Discuss to development of frog/chick with diagrams.

Q3-To draw chick embryos from 16-18hrs, 24-28hrs, 33-36hrs, 42-72hrs of development.

Q4-Write to study of development of chick by window preparation.

Q5-To draw and comment on endocrine glands of rat/ insects

Q6-Write a short note on endocrine disorders.

References

1. Cramer KS, Fraser SE, Rubel EW. *Dev Biol.* 2000;224:138–151. [[PubMed](#)] [[Google Scholar](#)]
2. Cramer KS, Bermingham-McDonogh O, Krull CE, Rubel EW. *Dev Biol.* 2004;269:26–35. [[PubMed](#)] [[Google Scholar](#)]
3. Cramer KS, Cerretti DP, Siddiqui SA. *Dev Biol.* 2006;295:76–89. [[PubMed](#)] [[Google Scholar](#)]
4. Huffman KJ, Cramer KS. *Dev Neurobiol.* 2007;67:1655–1668. [[PubMed](#)] [[Google Scholar](#)]
5. Krull CE. *Dev Dyn.* 2004;229:433–439. [[PubMed](#)] [[Google Scholar](#)]
6. Gerlach-Bank LM, Cleveland AR, Barald KF. *Dev Dyn.* 2004;229:219–230. [[PubMed](#)] [[Google Scholar](#)]
7. www.onlinebiologynotes.com
8. [Growth and Metamorphosis in Insects | Zoology](#)
9. [Function of Hormones in the Endocrine System | Animals](#)
10. [Endocrine and Exocrine Glands in Vertebrates | Chordata | Zoology](#)
11. [Endocrine Glands in Vertebrates \(With Diagram\) | Chordata | Zoology](#)

Unit 6: Instrumentation

6.1 Objective

6.2 Introduction

6.3 General principle, functioning and utility of some common instruments

6.3.1 Microscopes, Microtome's, Colorimeter

6.3.2 Spectrophotometer, centrifuge, autoclave and electrophoresis

6.4 Summary

6.5 Terminal questions and answers

6.1 OBJECTIVE

To study the principle, functioning and utility of:

- Microscopes
- Microtome
- Colorimeter
- Spectrophotometer
- Centrifuge
- Autoclave
- Electrophoresis

6.2 INTRODUCTION

Bio-Instrumentation deals with the study of various instruments which plays important role in understanding biological processes in detail. Different areas of biology utilize separate technique and instrument to understand the process. For example, in cell biology we learn about shape, size, type of cell division (meiosis and mitosis), cell organelles, and other, this process can only be studied with the help of microscope. Simple microscope is with just one lens is used to learn about cell shape, size, mitosis in root tip, etc. Compound microscopes have multiple lenses. Because of the way these lenses are arranged, they can bend light to produce a much more magnified image than that of a magnifying glass. Electron microscope is used to study cell organelles in detail.

The property of colorimetric analyses is to determine the intensity or concentration of compounds in coloured solution. Microtome is defined as a device for advancing a block of tissue a given amount, cutting a slice from it, and then advancing it for same amount, and so on. A spectrophotometer consists of a light source, a monochromator, sample holder (cuvette) and a light detector. The spectrophotometer used to assess the wavelength range over both ultraviolet and visible light and obtain absorption spectra. Centrifugation is a process used to separate or concentrate materials suspended in a liquid medium.

6.3 GENERAL PRINCIPLE, FUNCTIONING AND UTILITY OF SOME COMMON INSTRUMENTS

6.3.1 MICROSCOPES, MICROTOME'S, COLORIMETER

A microscope is an instrument that magnifies object otherwise too small to be seen, producing an image in which the object appears larger.

Principles of Microscope: The microscope works on three principles of physics:

1. Magnification
2. Resolving power
3. Numerical aperture

1. **Magnification:** The magnification or linear magnification of a microscope is defined as the ratio of the image size to the object (specimen) size. If the image and object are in the same medium, then it is just the image distance divided by the object distance. There is a difference in the meaning of the two terms, magnification and magnifying power. Magnifying power or angular magnification is the ratio of the angle subtended by objects and image.

If the magnifying power of lens is 10X it means that the given lens can enlarge the object up to 10 times. In compound microscope, the magnification is the product of magnifying power of both the lenses. The magnifying power of lens depends on focal length. Lower the focal length, higher is the magnifying power of lens.

2. **Resolution:** The resolving power is the ability of magnifying instrument to distinguish two objects that are closely placed. The resolution power of lens is inversely related to the limit of resolution. The resolution of microscope can find out by using Abbe's equation.

Where,

d – Distance between two closely distant points

λ – Wavelength of light

$n \sin \theta$ – numerical aperture

The microscope with higher magnification has small d value. λ is the wavelength of light, shorter is the wavelength; higher is the resolution. The wavelength of visible light is from 300 to 700 nm. The best resolution for light microscope is obtained in the range of 450 to 500 nm. 'n' is the refractive index of medium. Refractive index is the ability of the medium to bend the light. The angle of cone of light is affected by the refractive index of medium. The refractive index of air is 1. ' θ ' is the half of the angle of the cone of light that enters the

microscope. The value of 'Sin θ ' cannot be more than 1 because angle of entering cone of light cannot be more than 90° and value of sin 90 is 1.

$$d = 0.5 \times 450 \text{ nm}$$

$$d = 225 \text{ nm Or } 0.2 \text{ } \mu\text{m}$$

Hence, the resolution limit of light microscope is $0.2 \text{ } \mu\text{m}$.

Parts of Microscope:

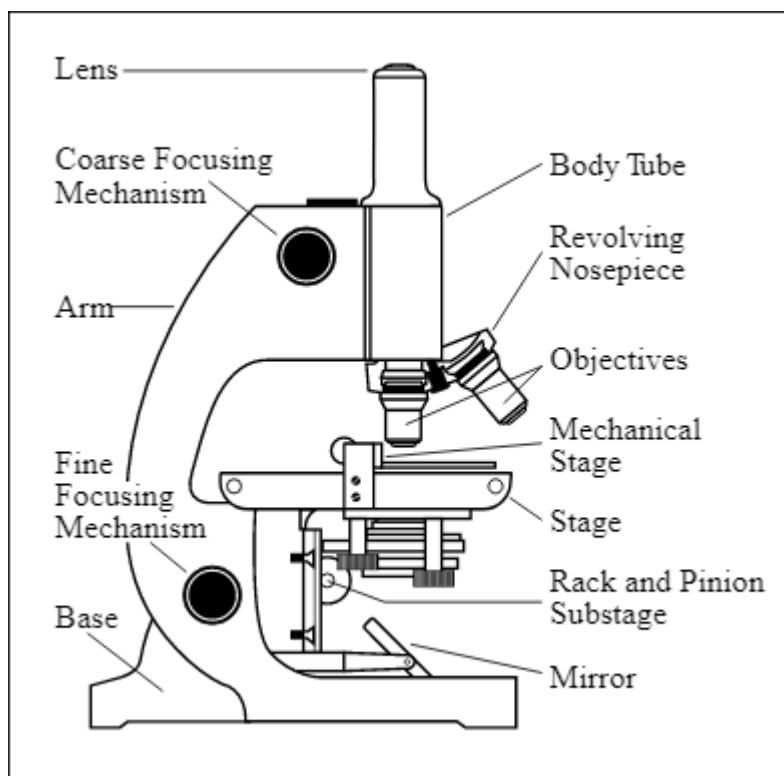


Fig. 6.1: Compound microscope (source: study.com)

The body is made from metal and the parts are divided into mechanical and ocular parts.

1. **Base:** The bottom part is called as base. It gives support to the body. The illuminating source of microscope is placed at the base of microscope
2. **Arm:** It connects the ocular part with the base. The arm is used to hold and carry the microscope. The coarse and fine focusing knobs are placed on the arm.
3. **Eyepiece:** It is present at the top of microscope. It is the part through which we observe the sample/object. The magnifying power of the eyepiece lens is generally 10X.
4. **Eyepiece tube or body tube:** The function of eyepiece tube is to hold the eyepiece and hence it is names as eyepiece tube.

5. **Nosepiece:** This part connects the eyepiece tube to objective lenses. The flexibility of nosepiece allows switching the objective lenses.
6. **Objective lens:** In compound microscope, in general 3 objective lenses are placed. Their magnifying power is 10X, 40X and 100X respectively. The total magnification of respective lenses would be $10X \times 10X = 100X$, $40X \times 10X = 400X$ and $100X \times 10X = 1000X$ (the magnifying power of eyepiece lens is 10X).
7. **Focusing mechanism (Adjacent knobs):** The coarse and fine adjustment knobs are used for right placing of sample and for focusing it.
8. **Stage:** It is place where sample or object is kept for viewing. For accurate placement, the stage is provided with clips that hold the slide firmly. The adjustment knobs are used to move the clips as per requirement.
9. **Aperture:** It is present on the stage that allows the entry of light from illuminator to fall on sample or object.
10. **Source of Illumination:** In non-electric microscope, the sunlight is used as source of illumination and hence mirror is placed to focus the sunlight. In electric microscope, lamp is placed of specific wavelength.
11. **Condenser:** It is placed at the bottom of the stage. Its function is to focus the light on sample form illuminator. The lens quality of condenser equally affects the superiority of image.
12. **Diaphragm:** It is generally associated with condenser. And it is also placed at the bottom of the stage, beside condenser. The diaphragm and condenser together produce hollow cone of light that strikes the sample and illuminate it.

Microtome:

A microtome (from the Greek mikros, meaning “small”, and temnein, meaning “to cut”) is a tool used to cut extremely thin slices of material, known as sections. The structure of cells and their nature of arrangement etc, cannot be sectioned by the freehand method. Materials, especially unicellular forms and those that are not stiff to withstand the action of the knife, and those containing cavities, which would be crushed out of shape if sectioned, require a mechanical device, which cuts sections after surrounding and supporting such materials, with some substance like wax which impregnates them. Another drawback of freehand sectioning is that sections of uniform thickness cannot be produced by that method. Further, sections of less than 10 μm thickness cannot be cut by the freehand method. These drawbacks are overcome by the use of the instrument called the microtome.

Microtome is defined as a device for advancing a block of tissue a given amount, cutting a slice from it, and then advancing it for same amount, and so on.

Microtomes are broadly classified into two categories:

- 1) Those in which the block remains stationary and the knife moves across it; and
- 2) Those in which the block moves across a stationary knife.

The first group includes several types known by names like: Bench microtome, Clinical microtome, Sliding microtome, Sledge microtome and so on.

These are not useful in producing serial sections.

They are, however, used in producing thin sections of wood and other materials, of which serial sections are not required.

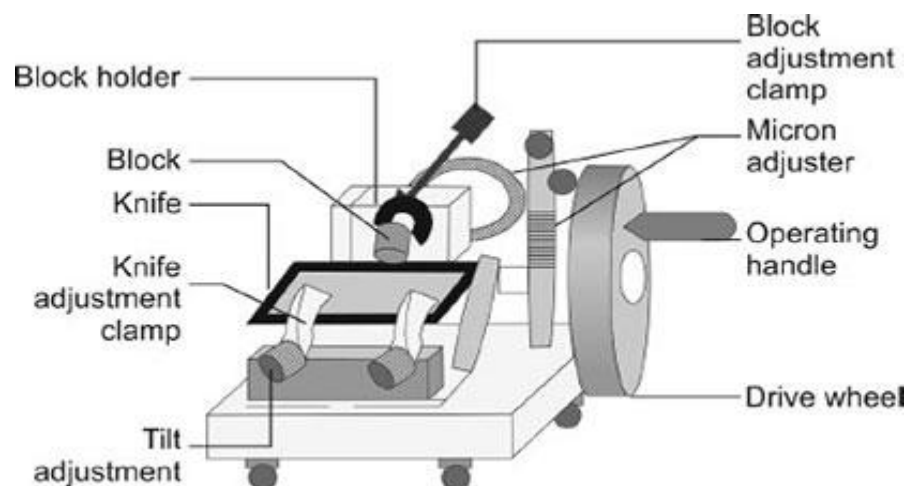


Fig6. 2: Microtome instrument (source: jaypeedigital.com)

Colorimeter:

The colorimeters are highly sensitive devices that can measure the concentration and intensity of a particular color that is used in a product. There are mainly two different types of colorimeters that are used in industries that are color densitometers and color photometers. The color densitometers measure the color density of primary color in a color combination in a test sample. The color photometers are used for measuring the reflectance of a color as well as the transmission.

Principle of Colorimeter:

The working of colorimeters is mainly based on the Beer-Lambert's Law. This law states that the light absorption when passes through a medium are directly proportional to the concentration of the medium. When a colorimeter is used, there is a ray of light with a certain wavelength is directed towards a solution. Before reaching the solution the ray of light passes through a series of different lenses. These lenses are used for navigation of the colour light in the colorimeter. The colorimeter analyses the reflected light and compares with a predetermined standard. Then a microprocessor installed in the device is used for calculation of the absorbance of the light by the solution. If the absorption of the solution is higher than there will be more light absorbed by the solution and if the concentration of the solution is low then more lights will be transmitted through the solution.

Thus both the laws can be expressed as:

Lambert's law: $\log_{10} I_0/I = K_1 l$

Beer's law: \log_{10}

$I_0/I = K_2 c$

[Where I_0 = Intensity of incident light (light entering a solution); I = Intensity of transmitted light (light leaving a solution); l = Length of absorbing solution; c = Concentration of coloured substance in solution; K_1 and K_2 = Constants.]

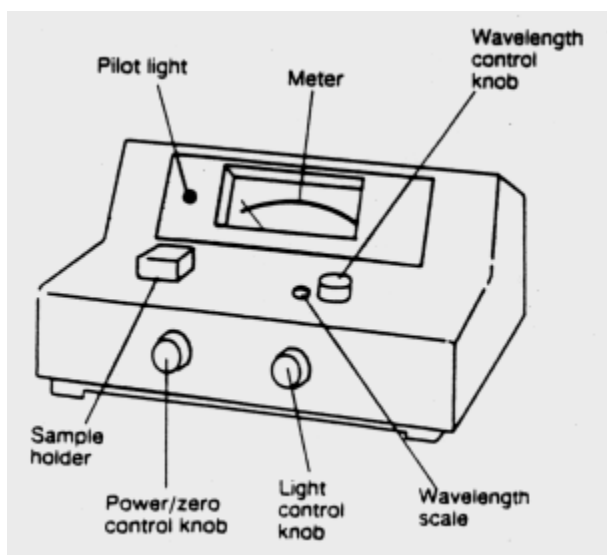


Fig.6.3: Colorimeter instrument (source: pirate.shu.edu)

- To analyse the concentration of an unknown sample, there are several specimen prepared from the test sample and then tested using an efficient colorimeter.
- After analysis, the transmittance and concentration of the tested specimen are plotted on a graph to obtain a graphical representation of the concentration creating a calibration curve.
- This curve is then compared with the curve of a known sample, and the concentration is measured.

Applications of Colorimeters

- Food ingredients,
- Building materials,
- Textile products,
- Beverages,
- Chemical solutions and many others.

6.3.2 SPECTROPHOTOMETER, CENTRIFUGE, AUTOCLAVE AND ELECTROPHORESIS

1) Spectrophotometer:

A photometer is a device for measuring 'light', and 'spectro' implies the whole range of continuous wavelengths that the light source is capable of producing. The detector in the photometer is generally a photo cell in which a sensitive surface receives photons; and a current is generated that is proportional to the intensity of the light beam, reaching the surface.

An instrument used to measure the absorbance by measuring the amount of light of a given wavelength that is transmitted by a sample is termed spectrophotometer. A spectrophotometer consists of a light source, a monochromator, sample holder (cuvette) and a light detector.

The spectrophotometer used to assess the wavelength range over both ultraviolet and visible light and obtain absorption spectra.

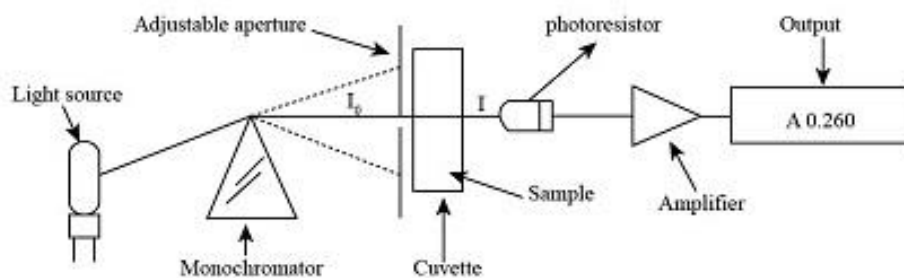


Fig6.4: Spectrophotometer (source: paramedicworld.com)

Principle:

The spectrophotometer technique is to measure light intensity as a function of wavelength. It does this by diffracting the light beam into a spectrum of wavelengths, detecting the intensities with a charge-coupled device, and displaying the results as a graph on the detector and then on the display device.

1. In the spectrophotometer, a prism (or) grating is used to split the incident beam into different wavelengths.
2. By suitable mechanisms, waves of specific wavelengths can be manipulated to fall on the test solution. The range of the wavelengths of the incident light can be as low as 1 to 2nm.
3. The spectrophotometer is useful for measuring the absorption spectrum of a compound, that is, the absorption of light by a solution at each wavelength.

The essential components of spectrophotometer instrumentation include:

1. A table and cheap radiant **energy source**
2. Materials that can be excited to high energy states by a high voltage electric discharge (or) by electrical heating serve as excellent radiant energy sources.
3. A **monochromator**, to break the polychromatic radiation into component wavelength (or) bands of wavelengths.
4. A monochromator resolves polychromatic radiation into its individual wavelengths and isolates these wavelengths into very narrow bands.

2) Centrifugation:

Centrifugation is a process used to separate or concentrate materials suspended in a liquid medium. It is a method to separate molecules based on their sedimentation rate under

centrifugal field. It involves the use of the centrifugal force for the sedimentation of molecules. It is also used to measure physical properties (such as molecular weight, density and shape) of molecules. If centrifugation is used for separation of one type of material from others; it is termed as preparative centrifugation; whereas if it is used for measurement of physical properties of macromolecules then termed as analytical centrifugation.

Principle of Centrifugation: Particles suspended in a solution, particles whose mass or density is higher than that of the solvent sink or sediment, and particles that are lighter than it float to the top.

The greater the difference in mass or density, the faster they sink. The sedimentation movement is partially offset by the buoyancy of the particle. Because the Earth's gravitational field is weak, a solution containing particles of very small masses usually remain suspended due to the random thermal motion. However, sedimentation of these particles can be enhanced by applying centrifugal forces.

A centrifuge does the same thing. It increases the sedimentation by generating centrifugal forces. A centrifuge does the same thing. It increases the sedimentation by generating centrifugal forces as great as 1,000,000 times the force of gravity.

Let us consider a solution being spun in centrifuge tube. The centrifugal force acting on a solute particle of mass m ,

$$\text{Centrifugal force} = m\omega^2 r$$

Where, ω is the angular velocity in radians per second,

' r ' is the distance from the centre of rotation to the particle, and

$\omega^2 r$ is the centrifugal acceleration.

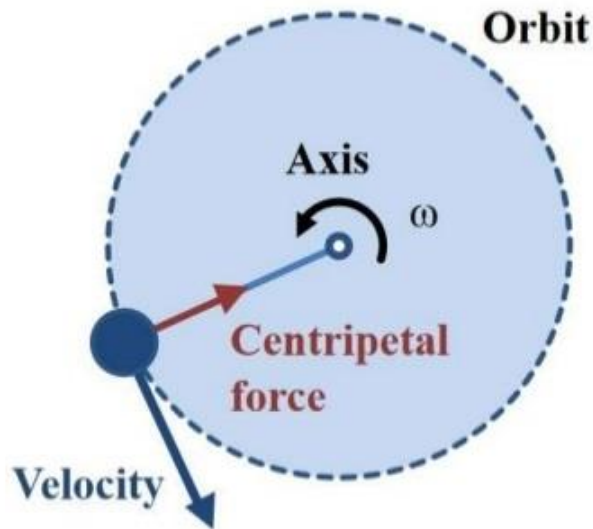


Fig6.5: Principle of centrifugation (source: iqsdirectory.com)

- In a solution, a particle whose density is higher than that of the solvent sink (sediment), and particles that are lighter than it floats to the top.
- The greater the difference in density, the faster they move. If there is no difference in density (isopycnic conditions), the particles stay steady.
- To take advantage of even tiny differences in density to separate various particles in a solution, gravity can be replaced with the much more powerful “centrifugal force” provided by a centrifuge.
- A centrifuge is a piece of equipment that puts an object in rotation around a fixed axis (spins it in a circle), applying a potentially strong force perpendicular to the axis of spin (outward).
- The centrifuge works using the sedimentation principle, where the centripetal acceleration causes denser substances and particles to move outward in the radial direction.
- At the same time, objects that are less dense are displaced and move to the centre.
- In a laboratory centrifuge that uses sample tubes, the radial acceleration causes denser particles to settle to the bottom of the tube, while low- density substances rise to the top.

3) Autoclave

Introduction:

An autoclave is a machine in which steam is circulated for sterilization of object. It is a physical method of killing bacteria, viruses, and even spores present in the material put inside of the vessel using steam under pressure. Autoclave sterilizes the materials by heating them up to a particular temperature for a specific period of time. It is just like a pressure cooker which is based on the steam under pressure principle. With the help of steam, autoclave destroys the microorganisms which are present on the object.

The autoclave is also called a steam sterilizer that is commonly used in healthcare facilities and industries for various purposes. The autoclave is considered a more effective method of sterilization as it is based on moist heat sterilization.

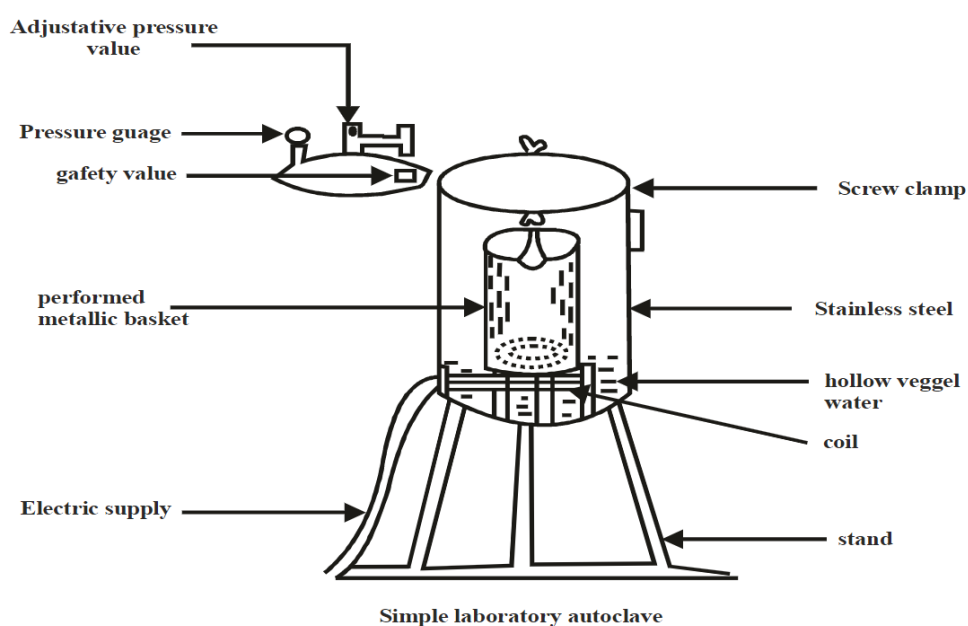


Fig. 6.6: Autoclave instrument (source: biologybase.com)

Principle:

The autoclave works on the principle of moist heat sterilization. The high pressure inside the chamber increases the boiling point of water for the sterilization of equipment. The higher pressure also ensures the rapid penetration of heat into the deeper parts of equipment. Moist heat generated by autoclave is more effective than dry heat for thermal

sterilization. Moist heat causes coagulation of cell protein at much lower temperature than dry heat. Additionally, thermal capacity is much greater than hot air. In autoclave, water is boiled till its vapour pressure equals that of surrounding. When pressure inside the vessel increases to 15 lb/sq. inch, it also increase temperature of steam from 100°C to 121°C. When saturated steam strikes with cold subject it undergoes condensation where it liberates heat equal to 524 calories per gram which is around 500 times more than hot air. Consequently, object get heated rapidly and undergoes sterilization. Time required for sterilization is variable depending on condition of temperature and pressure.

Temperature (°C)	Steam pressure (lb/sq. inch)	Holding time (minutes)
115-118	10	30
121-124	15	15
126-129	20	10
135-138	30	3

Working:

A sufficient quantity of water is poured into the chamber and the level of water is adjusted in such a way that it is slightly touching to the bottom of the perforated chamber. The material is packed in the perforated chamber. The lid is then closed with the screw and the autoclave is switched on. Initially, discharge tap is kept open and safety valve is adjusted to required pressure. As the temperature of water increases, it starts to vaporise and result in the formation of stem. This steam removes the air from autoclave which is indicated by formation of air bubble at discharge valve. When air bubbles stop emitting from discharge tap, it indicates that complete air has been removed out. At this stage the discharge valve is closed. Once steam pressure reaches to desired value, safety valve is set open. From this point subject is hold for time as specified in table 1. After holding time autoclave is switched off and allows cooling. Then lid is opened and sterilized materials are taken out

Components:

Autoclave comprised of three parts: a pressure chamber, a lid and an electrical heater.

Pressure chamber consists of: Large cylinder (vertical or horizontal) in which the materials to be sterilized are placed made up of gunmetal or stainless steel and placed in a supporting iron case.

A steam jacket (water compartment)

The lid is fastened by screw clamps and rendered airtight by an asbestos washer.

Safety valve: An electrical heater is attached to the jacket; that heats the water to produce steam.

Application:

1. Autoclaves are widely used in microbiology, veterinary science, mycology etc.
2. It is used to sterilize wide range of material including but not limited to laboratory glass wares, laboratory equipment's and instruments, surgical material including needles, seizures, heat-stable hand gloves, containers, and closures etc.
3. Autoclave is most commonly involved in the sterilization of biological media.
4. A growing application of autoclave is the pre-disposal treatment and sterilization of waste materials which are released from pathogenic area like Hospitals waste.

Advantages:

1. Autoclave is more efficient than dry heat.
2. It kills all types of bacteria, fungi including spores.
3. A large number of materials can be sterilized in one batch by using a big autoclave.

Disadvantages:

1. Not suitable for heat-labile substances.
2. Normal cycle fails to destroy pyrogens.
3. It is not suitable for the sterilization of powders and oils.

4) Electrophoresis:

Electrophoresis is used to separate macromolecules in a fluid or gel based on their charge, binding affinity under electric field. Ferdinand Frederic Reuss was the first person to observe electrophoresis. Electrophoresis technique is widely used for the separation and analysis of biomolecules such as proteins, plasmids, RNA, DNA, nucleic acids.

Principle:

The basic principle of electrophoresis is that charged particles in a supporting medium will move toward an electrode with the opposite charge when an electrical field is applied. Nucleic acid has a negative charge and therefore it migrates towards the anode.

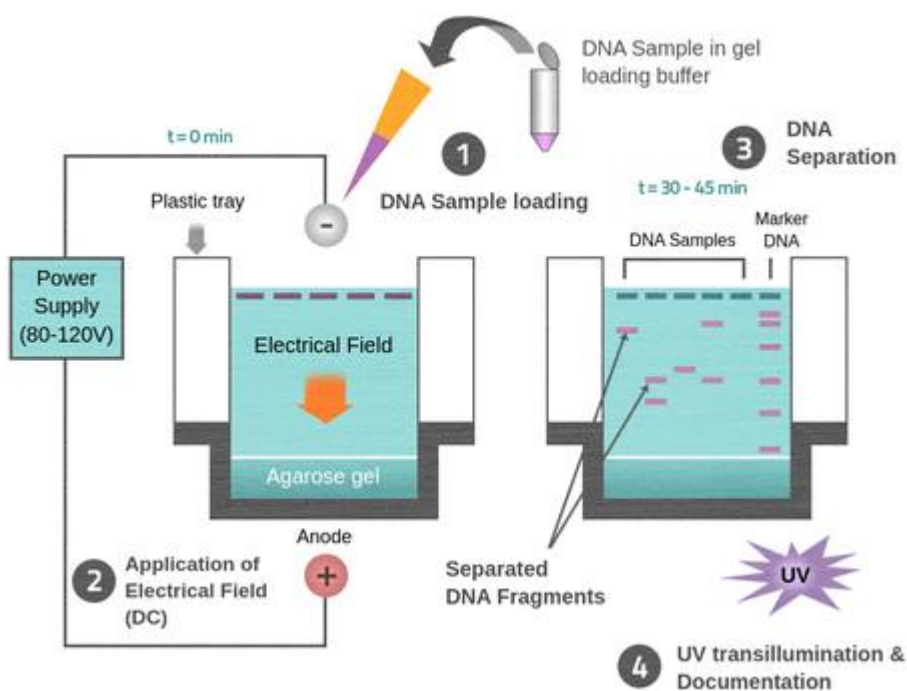


Fig6.7: Electrophoresis procedure (source: theory.labster.com)

In gel electrophoresis, gel serves as molecular sieve. There are two basic types of materials used to make gels: agarose and polyacrylamide. Agarose is a natural colloid extracted from seaweed. Agarose have a very large pore size and are used primarily to separate very large

molecules with a molecular mass greater than 200kDa. Agarose is a linear polysaccharide made up of the basic repeat unit agarobiose, which comprises alternating units of galactose and 3, 6-anhydrogalactose. Agarose is usually used at concentrations between 1 % and 3 %. Agarose gel is used for the electrophoresis of both proteins and nucleic acids.

A polyacrylamide gel consists of chains of acrylamide monomers cross-linked with N, N-methylene bis -acrylamide units. The pore size of the gel is determined by both the total concentration of monomers (acrylamide - bis) and the ratio of acrylamide to bis. Polymerization of the acrylamide: bis solution is initiated by ammonium persulfate and catalyzed by TEMED.

Gel formed by polymerization of acrylamide has several positive features in electrophoresis:

1. High resolving power for small and moderately sized proteins and nucleic acids (up to approximately 1×10^6 Da),
2. Acceptance of relatively large sample sizes,
3. Minimal interactions of the migrating molecules with the matrix, and
4. Physical stability of the matrix

The resolving power and molecular size range of a gel depend on the concentration of acrylamide and bis acrylamide. The acrylamide concentration of the gel normally varies from 5 % to 25 %. Lower percentage gels are better for resolving very high molecular weight molecules, while much higher percentage is needed to resolve smaller. A standard polyacrylamide gel formed by polymerization of 7.5 % acrylamide. It can be used over the molecular size range of 10,000 to 1,000,000 Da; however, the best resolution is obtained in the range of 30,000 to 300,000 Da.

SDS-Polyacrylamide gel electrophoresis (SDS-PAGE)

Electrophoretic separation of proteins is most commonly performed in polyacrylamide gels. The relative movement of proteins through a polyacrylamide gel depends on the charge density (charge per unit mass), mass (or size) and shape of the molecules. If two proteins have the same mass and shape, the one with the greater charge density will move faster through the gel. Similarly, if two proteins having same charge density and shape, the one of smaller mass or size will migrate faster than the large size protein. Shape is also factor

compact globular proteins move more faster than elongated fibrous proteins of comparable mass

In SDS PAGE, proteins are exposed to the negatively charged anionic detergent sodium dodecylsulfate (SDS) before and during gel electrophoresis. SDS binds to main chains at a ratio of about one SDS for every two amino acid residues, which imparts a large net negative charge on protein. The negative charge acquired by protein due to binding of SDS is usually much greater than the charge on native protein; this native charge thus becomes insignificant. If the protein itself has a very large positive or negative charge, this charge may not be negligible compared with the charge produced by the bound SDS.

6.4 SUMMARY

Instrumentation is a tool to understand biological process in a better way. In this unit detailed study of principle and uses of various instruments used in biology are studied. A microscope is an instrument that magnifies object otherwise too small to be seen, producing an image in which the object appears larger. Spectrophotometer is an instrument used to measure the absorbance by measuring the amount of light of a given wavelength. Centrifugation is a method to separate molecules based on their sedimentation rate under centrifugal field. The greater the difference in mass or density, the faster they sink. The sedimentation movement is partially offset by the buoyancy of the particle. Colorimetry is a widely used technique applied in biological system. It involves the measurement of a compound or a group of compounds present in a complex mixture. The autoclave works on the principle of moist heat sterilization. The high pressure inside the chamber increases the boiling point of water for the sterilization of equipment. The higher pressure also ensures the rapid penetration of heat into the deeper parts of equipment. Electrophoresis is a technique utilized in research and in the clinical setting for separation of proteins, isoenzymes, lipoproteins, transport proteins, and nucleotides in various body fluids. It is especially useful as an analytical tool, permitting visualization of proteins and nucleotides after electrophoresis by treatment with dyes, as well as estimation of the number of protein in a mixture.

6.5 TERMINAL QUESTIONS AND ANSWERS

Question 1. Write short note on

A) Magnification

B) Resolving power

C) SDS PAGE

D) Beer lambert law

E) Colorimeter

D) Microtome

E) Centrifuge

Question2. Long answer questions:

A) Write the principle of microscopy.

B) Explain beer lambert law in detail.

C) Write the advantages and disadvantages of autoclave.

D) Explain the principle of autoclave.

E) Explain the process of electrophoresis.

6.6 REFERENCES

- Frazier WC and Westhoff DC. Food Microbiology. Tata McGraw Hill Publishing Company Limited. 1995.
- Banwart GJ (1989). Basic Food Microbiology. Chapman & Hall, New York, NY.
- Jay JM (2000). Modern Food Microbiology. CBS Publications and Distribution. Delhi.
- Collins CH, Patricia M, and Lyne JM (1995). Collins and Lynes Microbiological Methods 7th edition. Grange, Butter Worth, Oxford.
- Cappucino JG and Sherman N (1996). Microbiology, A Laboratory Manual 4th edition. Benjamin Cumings Inc. California.
- Alberts B et al (2018), Molecular biology of the cell, 5th ed. Garland Science Publishing.
- Brown TA (2007), Genomes, 3rd ed. Garland Science Publishing.

UNIT-7: BIOSTATISTICAL EXERCISE

7.1 Introduction

7.2 Objectives

7.3 .1- Calculation of mean, median, mode, standard deviation, standard error

7.3.2-Chi-square test and student t-test from the data provided.

7.4 Results

7.5 Summary

7.6 Terminal Questions and answers

7.1-INTRODUCTION-

Statistics is the study of methods and techniques for collection, analysis, organization, interpretation and presentation of numerical data.

Father of biostatistics- Francis Galton.

BIOMETRY firstly used- W.F.R.WELDON

Biostatistics may be defined as the application of the statistical methods to the problems of biology, including human biology, medicine and public health. It is also known as BIOMETRY (literally meaning biological measurements).

Biostatistics is the application of statistics to biology. It is frequently associated with application to medicine and to agriculture.

Application of Biostatistics- importance of biostatistics in the following areas-

- 1-statistical genetics
- 2-environmental statistics
- 3- Numerical taxonomy
- 4- Statistical methods for longitudinal studies.
- 5-statistical ecology
- 6- Statistical ethology
- 7-forest mensuration
- 8-forest and agricultural yield tables. Etc.

Central tendency- any tendency in the statistical data of a series which cluster round a central value of the same series, is called a central tendency. The measurements of central tendency has three types-

Mean, Median, Mode

7.2- OBJECTIVE-

- 1- Mean and measurement of mean
- 2- Median and measurement of median
- 3- Mode and measurement of mode

4- Standard deviation and standard error with measurement

5- Chi-square test and measurement

6- Student *t*-test and measurement

7.3.1 Mean- the concept of the mean as the center of gravity was used by L.A.J. Quetlet in 1846. It has three types.

- 1- Arithmetic mean
- 2- Harmonic mean
- 3- Geometric mean

Arithmetic mean (\bar{x}) - the arithmetic mean of a group is the simple arithmetic average of the observations. This is calculated by dividing the total of all the observations by the number of observation.

$$\bar{X} = \frac{\sum X}{N}$$

or frequency distribution

$$\bar{x} = \frac{\sum fx}{\sum n}$$

Example- calculation of arithmetic mean for a series of serum albumin levels (%) of 24 children.

2.90, 2.98, 3.30, 3.43, 3.57, 3.61, 3.62, 3.69, 3.73, 3.75, 3.76, 3.77, 3.55, 3.45, 3.38, 3.43, 3.72, 3.71, 3.66, 3.68, 3.88, 3.84, 3.76, 3.76.

Ans- the total of all these values $\sum x = 85.93$

Total number of observations (*n*) = 24

$$\bar{X} = \frac{\sum X}{N}$$

The arithmetic mean

$$= 85.93/24 = 3.58\%$$

Example- calculation of arithmetic mean of protein intake of 400 families-

Protein intake/unit/day(g)	No. of families
15-25	30
25-35	40
35-45	100
45-55	110

55-65	80
65-75	30
75-85	10

Ans- arithmetic mean $\bar{x} = \frac{\sum fx}{\sum n}$

Class interval	F (frequency)	X (mid value)	fx
15-25	30	20	600
25-35	40	30	1200
35-45	100	40	4000
45-55	110	50	5500
55-65	80	60	4800
65-75	30	70	2100
75-85	10	80	800
total	$\sum n = 400$		$\sum fx = 19000$

arithmetic mean $\bar{x} = \frac{\sum fx}{\sum n}$, $19000/400 = 47.50\text{gm.}$

Harmonic mean (HM) - harmonic mean is the reciprocal of the arithmetic mean.

$$HM = n / [(1/x_1) + (1/x_2) + (1/x_3) + \dots + (1/x_n)]$$

Example- find out HM the given distribution 2,4,5.

$$HM = n / [(1/x_1) + (1/x_2) + (1/x_3)]$$

$$= 3 / [(1/2) + (1/4) + (1/5)]$$

$$= 60/19 = 3.16$$

Geometric mean (GM)- the geometric mean of a set of observation is the nth root of their product. The computation of the geometric mean requires that all observation be positive, that is greater than zero.

$$GM = \sqrt[n]{x_1 \cdot x_2 \cdot \dots \cdot x_n}$$

or

$$GM = (x_1 \cdot x_2 \cdot \dots \cdot x_n)^{1/n}$$

Example- find out geometric mean (GM) 4 and 9.

$$GM = \sqrt[n]{x_1 \cdot x_2 \cdot \dots \cdot x_n}$$

or

$$GM = (x_1 \cdot x_2 \cdot \dots \cdot x_n)^{1/n}$$

$$GM = \sqrt[4]{4 \times 9} = \sqrt[4]{36} = 6.$$

Median- the concept of the median was conceived as early as 1816, by K. F. Gauss, enunciated and reinforced by other including F. Galton in 1869.

Median is the value situated just at the middle position of a series when items are arranged in the form of an ascending or descending. Median is an average of position.

- 1- When the number of items in the series is odd-

Median= value of $n+1/2$ item

n = total number of items in the series.

- 2- When the number of items in the series is even-

$$\text{Median} = \frac{(n/2) + (n/2) + 1 \text{ item}}{2}$$

Example- find the median of the following number-

94,33,86,68,80,48,70

Ans- ascending - 33,48,68,**70**,80,86,94.

$n = 7$ (odd)

Median= value of $n+1/2$ item

$$7+1/2 = 8/2 = 4 \text{ item}$$

Median = 70

Example- find the median of the following number-

88,72,33,29,70,86,54,91,60,57

Ans- ascending- 29,33,54,57,**60,70**,72,86,88,91

$n = 10$ (even)

$$\text{Median} = \frac{(n/2) + (n/2) + 1 \text{ item}}{2}$$

$$= \frac{(10/2) + (10/2) + 1 \text{ item}}{2}$$

$$= \frac{(5 \text{ item}) + (6 \text{ item})}{2}$$

$$= 60+70/2$$

$$= 65$$

3- Frequency distribution

$$M_m = l + \left(\frac{\frac{n}{2} - cf}{f} \right) h$$

Where

l = lower limit of median class,

n = number of observations,

cf = cumulative frequency of class preceding the median class,

f = frequency of median class,

h = class size (assuming class size to be equal)

Example -find out median for following data-

Class interval	frequency
15-25	30
25-35	40
35-45	100
45-55	110
55-65	80
65-75	30
75-85	10

Ans-

Class interval	frequency	Cumulative frequency
15-25	30	30
25-35	40	70
35-45	100	170 (cf)

45-55	110 (f)	280
55-65	80	360
65-75	30	390
75-85	10	400
total	n = 400 = 400/2 = 200	

$$M_m = l + \left(\frac{\frac{n}{2} - cf}{f} \right) h$$

Where

l = lower limit of median class,

n = number of observations,

cf = cumulative frequency of class preceding the median class,

f = frequency of median class,

h = class size (assuming class size to be equal)

$$n = 400 = 400/2 = 200$$

$$l = 45$$

$$cf = 170$$

$$f = 110$$

$$h = 10$$

$$\frac{45 + (200 - 170) \times 10}{110} = 45 + 300/110 = 45 + 2.73 = \mathbf{47.73}$$

MODE

The term “mode” was introduced by Karl Pearson in 1894. Mode is the value which occurs most frequency in a series. It is the value of maximum concentration and greatest density.

Example- find the mode of the following numbers-

4,3,2,5,3,4,5,1,7,3,2,1,3.

Ans- mode = 3.

Frequency distribution-

$$M_o = l + \left(\frac{f_1 - f_0}{2f_1 - f_0 - f_2} \right) h$$

Where:
l = lower limit of the modal class,
h = size of the class interval (assuming all class sizes to be equal),
f₁ = frequency of the modal class,
f₀ = frequency of the class preceding the modal class,
f₂ = frequency of the class succeeding the modal class.

Example- Find the mode for following data-

CI	Frequency
15-25	30
25-35	40
35-45	100
45-55	110
55-65	80
65-75	30
75-85	10

Ans-

CI	Frequency
15-25	30
25-35	40
35-45	100(f1)

45-55 (l)	110(fm)
55-65	80(f2)
65-75	30
75-85	10
total	400

$$M_o = l + \left(\frac{f_1 - f_0}{2f_1 - f_0 - f_2} \right) h$$

Where
 l = lower limit of the modal class,
 h = size of the class interval (assuming all class sizes to be equal),
 f₁ = frequency of the modal class,
 f₀ = frequency of the class preceding the modal class,
 f₂ = frequency of the class succeeding the modal class.

$$l = 45$$

$$fm = 110$$

$$f_1 = 100$$

$$f_2 = 80$$

$$h = 10$$

$$M = 45 + 100/40 = 47.5$$

STANDARD DEVIATION (σ or s)-

It was the great English statistician Karl Pearson (1857-1936) who coined the term SD and its symbol “ σ ” in 1893, prior to which this quantity was called the “mean error”.

The standard deviation is the square root of the average of the squared deviation of the observations from the arithmetic mean.

The process of omitting the algebraic signs + 1 and -1 of the deviations in mean deviation is avoided in standard deviation (σ).

1- Direct method-

$$SD = \sqrt{\frac{\sum |x - \bar{x}|^2}{n}}$$

Standard deviation (σ) =

$(x - \bar{x})^2 = D$, deviation of individual observation from arithmetic mean.
 Σ = summation
 n = total no. of items in the series.

Example- find the SD for the following data-49,63,46,59,65,52,60,54.

Ans- ascending order- 46, 49, 52, 54, 59, 60, 63, 65

$$\bar{x} = \Sigma x/n = \frac{46+49+52+54+59+60+63+65}{8}$$

$$= 448/8 = 56$$

Number (x)	D = (x - \bar{x})	D ²
46	-10	100
49	-7	49
52	-4	16
54	-2	4
59	+3	9
60	+4	16
63	+7	49
65	+9	81
		$\Sigma D^2 = 324$

$$SD = \sqrt{\frac{\Sigma |x - \bar{x}|^2}{n}}$$

$$\sqrt{324/8} = \sqrt{40.5} = 6.36.$$

2- Frequency distribution-

$$SD = \sqrt{\Sigma fD^2/n}$$

$(x - \bar{x})^2 = D$, deviation of individual observation from arithmetic mean.
 Σ = summation
 n = total no. of items in the series.
 F = frequency distribution

Example- calculate the SD of the following data-

CI	f
5-15	2
15-25	4
25-35	7
35-45	4
45-55	3

$$\text{Ans- SD} = \sqrt{\sum fD^2/n}$$

$$AM = 620/20 = 31$$

CI	x	f	fx	D=((x- \bar{x}))	fD ²
5-15	10	2	20	-21	882
15-25	20	4	80	-11	484
25-35	30	7	210	+1	7
35-45	40	4	160	+9	324
45-55	50	3	150	+19	1083
		N= 20	$\sum fx = 620$		$\sum fD^2 = 2780$

$$\begin{aligned}
 SD &= \sqrt{\sum fD^2/n} \\
 &= \frac{\sqrt{2780}}{20} \\
 &= 11.78
 \end{aligned}$$

Standard Error (SE)-

The relationship between the standard deviation of the mean and the SD was published by Karl Friedrich Gauss in 1809.

The term standard error was introduced in 1897 by G.U.Yule.

The average amount of the variability of the observations of a population is computed it is known as SD and when the average amount of the variability of the observation of a sampling distribution is computed it is known as SE or standard error.

The SE is usually for large sample and gives us an idea about the average amount of error which actually occurs estimating the value of a parameter on the basis of statistic.

$$SE(\bar{x}) = \sigma/\sqrt{n}$$

Example- a random sample of size 100 has mean 15, the population variance being 25. Find the SE.

$$\begin{aligned} SE(\bar{x}) &= \sigma/\sqrt{n} \\ &= 5/\sqrt{100} \\ &= 0.5 \end{aligned}$$

7.3.2 CHI-SQUARE TEST (χ^2)-

Chi-square is a quantity that measures the extent to which a set of the observed frequencies of a sample deviates from the corresponding set of the theoretical frequencies of the same sample. It is a measure of the aggregate discrepancy between the actual frequencies and the theoretical frequencies in a sample.

Chi-square is used as a test statistic in testing a hypothesis that provides a set of theoretical frequencies with which observed frequencies are compared.

A chi-square test refers to a test of hypothesis concerning the difference between the observed frequencies and the theoretical frequencies in a sample.

$\chi^2 = \sum \frac{(O - E)^2}{E}$ <p> χ^2 = the test statistic \sum = the sum of O = Observed frequencies E = Expected frequencies </p>

The degrees of freedom play a very important role in the χ^2 test of a hypothesis. The chi-square test depends on the number of degrees of freedom.

Example- the numbers of automobile accidents per week in a certain community were as follows-

12,8,20,2,14,10,15,6,9,4. Are these frequencies in agreement with the belief that accident conditions were the same during the 10 weeks period?

Ans 1- null hypothesis – the frequencies are in agreement with the belief that accident conditions were same during the 10 weeks period.

2-Computation of test statistics-

$$\begin{aligned} \text{Expected frequency of each week} &= \sum x/n = \frac{12+8+20+2+14+10+15+6+9+4}{10} \\ &= 100/10 = 10 \end{aligned}$$

week	O=observe frequency	E=expecte d frequency	O-E	(O-E) ²	(O-E) ² /E
1	12	10	2	4	0.4
2	8	10	-2	4	0.4
3	20	10	10	100	10.0
4	2	10	-8	64	6.4
5	14	10	4	16	1.6
6	10	10	0	0	0.0
7	15	10	5	25	2.5
8	6	10	-4	16	1.6
9	9	10	-1	1	0.1
10	4	10	-6	36	3.6
	100	100			$\chi^2=26.6$

Test statistic $\chi^2 = 26.6$

3-Degrees of freedom = $n-1 = 10-1 = 9$

4-Decision- at 5% level of significance the critical value of $\chi^2 = 16.919$ for 9 degrees of freedom. But the computed value of $\chi^2 = 26.6$ is greater than the critical value of $\chi^2 = 16.919$. ($\chi^2 = 26.6 > \chi^2 = 16.919$).

Hence the computed value of $\chi^2 = 26.6$ falls in the rejection region. Thus the null hypothesis is rejected. So it may be concluded that the observed frequencies are not in agreement with the belief that accident conditions were the same during the 10 weeks period.

STUDENT'S *t*-DISTRIBUTION (*t*-test)

The theory of small (or exact) sample was developed by Irish statistician William S. Gosset, who used to write under pseudonym (pen name) of student in 1908. Gosset gave his statistic name as Student's *t*-distribution or *t*-test.

When the sample is small ($n \leq 30$) then the distribution of the standardized variable *Z* of the statistic *t* will be far from normality and as a result the normal test cannot be applied. In order to deal with small samples ($n \leq 30$) new techniques and tests to significance known as EXACT SAMPLE TECHNIQUES (TESTS) have been developed.

It is important to note the “exact sample technique can be applied even for large samples but large sample theory cannot be applied for small samples”.

The quantity *t* is defined as

$$t = \frac{\text{difference of population parameter and the corresponding statistic}}{\text{Standard error of the statistic}}$$

With (n-1) degrees of freedom for $t = (\text{size of sample}) - 1$.

The degree of freedom for $t = (\text{size of sample}) - 1$.

Student's t - distribution: if x_1, x_2, \dots, x_n is a random sample size of n drawn from normal population with mean μ and variance σ^2 (not non) then the student t statistic (mean) is defined as

$$t = \frac{\bar{x} - \mu}{(\text{SE of mean})}$$

$$= \frac{\bar{x} - \mu}{s/\sqrt{n-1}}$$

(n-1) degrees of freedom.

S = standard deviation of the sample.

7.5 SUMMARY

The arithmetic mean of a group is the simple arithmetic average of the observations.

Harmonic mean is the reciprocal of the arithmetic mean

The geometric mean of a set of observation is the n th root of their product. The computation of the geometric mean requires that all observation be positive, that is greater than zero.

Median is the value situated just at the middle position of a series when items are arranged in the form of an ascending or descending.

Mode is the value which occurs most frequency in a series.

The standard deviation is the square root of the average of the squared deviation of the observations from the arithmetic mean.

The SE is usually for large sample and gives us an idea about the average amount of error which actually occurs estimating the value of a parameter on the basis of statistic.

Chi- square is used as a test statistic in testing a hypothesis that provides a set of theoretical frequencies with which observed frequencies are compared.

The theory of small (or exact) sample was developed by Irish statistician William S. Gosset, who used to write under pseudonym (pen name) of student in 1908. Gosset gave his statistic name as Student's t - distribution or t -test.

7.6 TERMINAL QUESTIONS AND ANSWERS-

a- what is biostatistics? Write the application of biostatistics.

b- Define mean?

c- 1-find out mean to given sample- 25,30,21,55,47,10,15,17,45,35. (ans-30)

2- Calculate the mean of the following data-

Class interval	frequency
10-20	2
20-30	7
30-40	17
40-50	29
50-60	29
60-70	10
70-80	3
80-90	2
90-100	1

(ans-48.4)

d-1- define median.

2- find out median to given data- 5,19,42,11,50,30,21,0,52,36,27.(ans-27)

3- find out median to given data-

Class interval	frequency
20-30	3
30-40	5
40-50	20
50-60	10
60-70	5

(Ans-46.75)

e-1- Define mode?

2- find out mode- 2,3,8,9,7,2,6,2,2,0,6,5,2.(ans-2)

3-find out mode-

Class interval	frequency
15-25	30
25-35	40
35-45	100
45-55	110
55-65	80
65-75	30
75-85	10

Ans-(47.5)

f-1- Define standard deviation. Write difference between standard deviation and standard error.

2-find out standard deviation-

Class interval	frequency
15-25	30
25-35	40
35-45	100
45-55	110
55-65	80
65-75	30
75-85	10

Ans-(14.10)

g-Define chi-square test, a survey of 200 families having three children selected at random gave the following results

Male births	No. of families
0	40
1	58
2	62
3	40

Test the hypothesis that male and female births are equally likely at 5% level of significance.

h- Define t -test called student's t -test?

Unit 8-Microbiology Experiments-

8.1 Introduction

8.2 Preparation of culture media for bacteria

8.3 Staining of microorganisms

8.4 Antibiotic sensitivity test

8.5 Bacteriological testing of milk

8.6 Summary

8.7 Terminal Questions and Answers

8.1 INTRODUCTION :

Microbial culture media preparation is the process of mixing nutrients, agents for buffering and maintaining the osmotic balance, as well as selective inhibitors or indicators to create an agar or broth that supports the growth and the differentiation of microorganisms. Microbial culture media preparation is a routine task in the regular monitoring of spoilage and pathogenic microbes in microbiological testing.

8.2 PREPARATION OF CULTURE MEDIA FOR BACTERIA-

Microbial culture media should provide optimal growth conditions for all or specific types of microorganisms. The precise composition of a medium depends on the species being cultivated and the application goal. The medium pH needs to be adjusted depending on the microorganisms. Microbial culture media is classified based on several parameters, like chemical constituents, physical nature, and function. Types of media defined by these parameters are described below.

CLASSIFICATION OF MICROBIAL CULTURE MEDIA BY CHEMICAL COMPOSITION

Synthetic (Defined) medium is a media with defined chemical commonly used to culture photoautotrophs, such as cyanobacteria and photosynthetic protists. It is widely used in research, to study microorganism metabolism.

Complex media is a media containing non-defined chemical components, such as peptone, meat extract, and yeast extract, that meet the nutritional requirements of different microorganisms. It is used to culture fastidious microbes with complex nutritional requirements.

MICROBIAL CULTURE MEDIA BASED ON PHYSICAL NATURE

Solid medium uses 1-7% agar-agar or 10-20% gelatin to solidify the liquid broth. Solid media is used to isolate different microbes from each other, establish pure cultures, make agar slants, and make agar stabs.

Liquid medium does not contain any solidifying agents. After inoculation and incubation, cells become visible in the form of a small mass or broth blurring.

MICROBIAL CULTURE MEDIA BASED ON PREPARATION METHOD

Ready-to-use medium is a solid or liquid medium supplied in plates, bottles, tubes or other containers, in ready-to-use form or ready-to-use after re melting and supplementing.

Medium prepared from commercially dehydrated formulations is a medium in dry form which requires rehydration and processing before use, resulting in either a complete medium or an incomplete medium to which supplements are added before use.

Medium prepared from individual components is a medium produced by a microbiology laboratory entirely from its individual ingredients.

On-demand medium is produced by a system that keeps highly concentrated, sterile culture medium available in a laboratory over several days. By dilution with sterile water it can produce a required amount of ready-to-use medium on demand, without the need for autoclaving.

PREPARATION OF MICROBIAL CULTURE MEDIA

Media preparation from dehydrated commercial formulations should be performed by following manufacturer's instructions.

The formulation of basic ingredients, like peptones, yeast extracts, agar, buffering substances, and antibiotics, is modified to achieve consistency of the medium.

The required amount of dehydrated medium or individual ingredients is dissolved in distilled water by continuous stirring followed by heating (if necessary).

Media containing agar should be adequately soaked with proper agitation before heating.

The pH must be adjusted, and the medium is dispensed into appropriate containers for sterilization by moist heat in an autoclave.

Heat-sensitive substances (e.g., proteins, enzymes) are sterilized by using membrane filters.

Culture media must be stored at specified temperatures to prevent modification of the composition, and no longer than the product shelf-life.

Aseptic preparation and storage are essential to protect culture media from microbial infection. Water loss on storage can be minimized by impermeable wrapping and/or storage at $5\text{ }^{\circ}\text{C} \pm 3\text{ }^{\circ}\text{C}$.

Chemical degradation, e.g. oxidation or antimicrobial loss, can be retarded by protection from light, heat, and dehydration.

8.3 STAINING OF MICROORGANISM

Because microbial cytoplasm is usually transparent, it is necessary to stain microorganisms before they can be viewed with the light microscope. In some cases, staining is unnecessary, for example when microorganisms are very large or when motility is to be studied, and a drop of the microorganisms can be placed directly on the slide and observed. A preparation such as this is called a wet mount. A wet mount can also be prepared by placing a drop of culture on a cover-slip (a glass cover for a slide) and then inverting it over a hollowed-out slide. This procedure is called the hanging drop.

In preparation for staining, a small sample of microorganisms is placed on a slide and permitted to air dry. The smear is heat fixed by quickly passing it over a flame. Heat fixing kills the organisms, makes them adhere to the slide, and permits them to accept the stain.

Simple stain techniques. Staining can be performed with basic dyes such as crystal violet or methylene blue, positively charged dyes that are attracted to the negatively charged materials of the microbial cytoplasm. Such a procedure is the simple stain procedure. An alternative is to use a dye such as nigrosin or Congo red, acidic, negatively charged dyes. They are repelled by the negatively charged cytoplasm and gather around the cells, leaving the cells clear and unstained. This technique is called the negative stain technique.

Differential stain techniques. The differential stain technique distinguishes two kinds of organisms. An example is the Gram stain technique. This differential technique separates bacteria into two groups, Gram-positive bacteria and Gram-negative bacteria. Crystal violet is first applied, followed by the mordant iodine, which fixes the stain. Then the slide is washed with alcohol, and the Gram-positive bacteria retain the crystal-violet iodine stain; however, the Gram-negative bacteria lose the stain. The Gram-negative bacteria subsequently stain with the safranin dye, the counterstain, used next. These bacteria appear red under the oil-immersion lens, while Gram-positive bacteria appear blue or purple, reflecting the crystal violet retained during the washing step.

Another differential stain technique is the acid-fast technique. This technique differentiates species of *Mycobacterium* from other bacteria. Heat or a lipid solvent is used to carry the first stain, carbolfuchsin, into the cells. Then the cells are washed with a dilute acid-alcohol solution. *Mycobacterium* species resist the effect of the acid-alcohol and retain the

carbolfuchsin stain (bright red). Other bacteria lose the stain and take on the subsequent methylene blue stain (blue). Thus, the acid-fast bacteria appear bright red, while the nonacid-fast bacteria appear blue when observed under oil-immersion microscopy.

Other stain techniques seek to identify various bacterial structures of importance. For instance, a special stain technique highlights the flagella of bacteria by coating the flagella with dyes or metals to increase their width. Flagella so stained can then be observed.

A special stain technique is used to examine bacterial spores. Malachite green is used with heat to force the stain into the cells and give them color. A counterstain, safranin, is then used to give color to the nonsporeforming bacteria. At the end of the procedure, spores stain green and other cells stain red.

Another differential stain technique is the acid-fast technique. This technique differentiates species of *Mycobacterium* from other bacteria. Heat or a lipid solvent is used to carry the first stain, carbolfuchsin, into the cells. Then the cells are washed with a dilute acid-alcohol solution. *Mycobacterium* species resist the effect of the acid-alcohol and retain the carbolfuchsin stain (bright red). Other bacteria lose the stain and take on the subsequent methylene blue stain (blue). Thus, the acid-fast bacteria appear bright red, while the nonacid-fast bacteria appear blue when observed under oil-immersion microscopy.

Other stain techniques seek to identify various bacterial structures of importance. For instance, a special stain technique highlights the flagella of bacteria by coating the flagella with dyes or metals to increase their width. Flagella so stained can then be observed.

A special stain technique is used to examine bacterial spores. Malachite green is used with heat to force the stain into the cells and give them color. A counterstain, safranin, is then used to give color to the nonsporeforming bacteria. At the end of the procedure, spores stain green and other cells stain red.

Stain Bacteria-

Most types of cells do not have much natural pigment and are therefore difficult to see under the light microscope unless they are stained. Several types of stains are used to make bacterial cells more visible. In addition, specific staining techniques can be used to determine the cells' biochemical or structural properties, such as cell wall type and presence or absence of endospores. This type of information can help scientists identify and classify microorganisms, and can be used by health care providers to diagnose the cause of a bacterial infection.

The simple stain

One type of staining procedure that can be used is the simple stain, in which only one stain is used, and all types of bacteria appear as the color of that stain when viewed under the microscope. Some stains commonly used for simple staining include crystal violet, safranin, and methylene blue. Simple stains can be used to determine a bacterial species' morphology and arrangement, but they do not give any additional information. Living bacteria are almost colorless, and do not present sufficient contrast with the water in which they are suspended to be clearly visible. The purpose of staining is to increase the contrast between the organisms and the background so that they are more readily seen in the light microscope. In a simple stain, a bacterial smear is stained with a solution of a single dye that stains all cells the same color without differentiation of cell types or structures. The single dye used here in our lab is methylene blue, a basic stain. Basic stains, having a positive charge, bind strongly to negatively charged cell components such as bacterial nucleic acids and cell walls.

fig1: Microscopic view of Bacillus (rod) shaped bacteria simple stained with crystal violet. Isolated and imaged by Muntasir Alam, University of Dhaka, Department of Microbiology in 2007. <https://commons.wikimedia.org/wiki/File:Micrograph.jpg>

The Gram Stain

Scientists will often choose to perform a differential stain, as this allows them to gather additional information about the bacteria they are working with. Differential stains use more than one stain, and cells will have a different appearance based on their chemical or structural properties. Some examples of differential stains are the Gram stain, acid-fast stain, and endospore stain. You will learn how to prepare bacterial cells for staining, and learn about the gram staining technique.

This very commonly used staining procedure was first developed by the Danish bacteriologist Hans Christian Gram in 1882 (published in 1884) while working with tissue samples from the lungs of patients who had died from pneumonia. Since then, the Gram stain procedure has been widely used by microbiologists everywhere to obtain important information about the bacterial species they are working with. Knowing the Gram reaction of a clinical isolate can help the health care professional make a diagnosis and choose the appropriate antibiotic for treatment.

Gram stain results reflect differences in cell wall composition. Gram positive cells have thick layers of a peptidoglycan (a carbohydrate) in their cell walls; Gram negative bacteria have very little. Gram positive bacteria also have teichoic acids, whereas Gram negatives do not. Gram negative cells have an outer membrane that resembles the phospholipid bilayer of the cell membrane. The outer membrane contains lipopolysaccharides (LPS), which are released as endotoxins when Gram negative cells die. This can be of concern to a person with an infection caused by a gram negative organism.

Fig 2: Microscopic image of a Gram stain of mixed Gram-positive cocci (*Staphylococcus aureus* ATCC 25923, purple) and Gram-negative bacilli (*Escherichia coli* ATCC 11775, red). Magnification:1,000. Image by Y Tambe.
https://commons.wikimedia.org/wiki/File:m_stain_01.jpg

Gram stains are best performed on fresh cultures—older cells may have damaged cell walls and not give the proper Gram reaction. Certain species are known as Gram-variable, and so both Gram positive and Gram negative reactions may be visible on your slide.

Poor staining technique could lead to inaccurate results. One of the most important steps in Gram staining is the decolorizing step (use of alcohol/acetone). If the decolorizer is not left on long enough, then it will not be able to differentiate between Gram positive and Gram negative bacteria. This step uses decolorizer, made of an alcohol/acetone mixture. Its function in Gram negative bacteria is to remove the outer cell membrane and thin layer of peptidoglycan. The cell membrane is mostly made of lipids and are sensitive to alcohols. By dissolving these layers, the crystal violet-iodine complex is also removed, and thus Gram negatives are now able to take up the secondary stain, safranin, which is used in the last step of the Gram stain, staining them pinkish-red and differentiating between them and the Gram positives, who with their thick peptidoglycan layer has retained the primary stain, crystal violet, and appears purple/blue. On the flip side, if you use too much decolorizer, it can decolorize your sample on the slide, leading to loss of crystal violet (the primary stain)-iodine complex. The decolorizing step is sensitive because of the cell wall structure. Even Gram positive bacteria with their thick cell walls could become excessively decolorized, resulting in the loss of the peptidoglycan layer and the crystal violet-iodine complex. When the use of the secondary stain, safranin, is applied in the last step, the Gram positive bacteria will pick up this stain and look reddish-pink instead of purple/blue. Watch video 2 for an example of this.

Another common mistake is in the preparation of the bacterial smear, which is in the first step of any staining procedure. This involves applying a thin film of bacteria on your microscope slide and then heat fixing it with either your bunsen burner, bacticinerator, or slide warmer. The main purpose of this step is to adhere the bacterial cells to the microscope slide (it also denatures the proteins and kills them too). If you forget to do this step, then the cells will be 'washed' off in all the subsequent steps of your staining process. You will literally have no cells on your slide to stain!

Although the vast majority of bacteria are either Gram positive or Gram negative, it is important to remember that not all bacteria can be stained with this procedure (for example, *Mycoplasmas*, which have no cell wall, stain poorly with the Gram stain).

Figure 3: Gram positive and Gram negative cell walls

Special Stains

There are a variety of staining procedures used to identify specific external or internal structures that are not found in all bacterial species, such as a capsule stain and a flagella stain. For images and more examples of specialized stains,

Capsule Stain

Some bacteria secrete a polysaccharide-rich structure external to the cell wall called a glycocalyx. If the glycocalyx is thin and loosely attached, it is called a slime layer; if it is thick and tightly bound to the cell, it is called a capsule. The glycocalyx can protect the cell from desiccation and can allow the cell to stick to surfaces like tissues in the body. They may also provide cells with protection against detection and phagocytosis by immune cells and contribute to the formation of a biofilm: in this way a glycocalyx can act as a virulence factor; (contributes to the ability of an organism to cause disease).

Capsules can be detected using a negative staining procedure in which the background (the slide) and the bacteria are stained, but the capsule is not stained. The capsule appears as a clear unstained zone around the bacterial cell. Since capsules are destroyed by heat, the capsule staining procedure is done without heat-fixing the bacteria.

Silver Stain

Flagella (long whip-like structures used for bacterial motility) and some bacteria (e.g. spirochetes) are too thin to be observed with regular staining procedures. In these cases, a silver stain is used. Silver nitrate is applied to the bacteria along with a special mordant; the silver nitrate precipitates around the flagella or the thin bacteria, thus thickening them so they can be observed under the light microscope.

8.4 Antibiotic sensitivity test

Antibiotics are medicines used to fight bacterial infections. There are different types of antibiotics. Each type is only effective against certain bacteria. An antibiotic sensitivity test can help find out which antibiotic will be most effective in treating your infection.

The test can also be helpful in finding a treatment for antibiotic-resistant infections. Antibiotic resistance happens when standard antibiotics become less effective or ineffective against certain bacteria. Antibiotic resistance can turn once easily treatable diseases into serious, even life-threatening illnesses.

Other names: antibiotic susceptibility test, sensitivity testing, antimicrobial susceptibility test

An antibiotic sensitivity test is used to help find the best treatment for a bacterial infection. It may also be used to find out which treatment will work best on certain fungal infections.

You may need this test if you have an infection that has been shown to have antibiotic resistance or is otherwise hard to treat. These include tuberculosis, MRSA, and C. diff. You may also need this test if you have a bacterial or fungal infection that is not responding to standard treatments.

The test is done by taking a sample from the infected site. The most common types of tests are listed below.

Blood culture

- A health care professional will take a blood sample from a vein in your arm, using a small needle. After the needle is inserted, a small amount of blood will be collected into a test tube or vial.

Urine culture

- You will provide a sterile sample of urine in a cup, as instructed by your health care provider.

Wound culture

- Your health care provider will use a special swab to collect a sample from the site of your wound.

Sputum culture

- You may be asked to cough up sputum into a special cup, or a special swab may be used to take a sample from your nose.

Throat culture

- Your health care provider will insert a special swab into your mouth to take a sample from the back of the throat and tonsils.
- There is very little risk to having a blood culture test. You may have slight pain or bruising at the spot where the needle was put in, but most symptoms go away quickly.
- There is no risk to having a throat culture, but it may cause slight discomfort or gagging.
- There is no risk to having a urine, sputum, or wound culture.

Results are usually described in one of the following ways:

- Susceptible. The tested medicine stopped the growth or killed the bacteria or fungus causing your infection. The medicine may be a good choice for treatment.
- Intermediate. The medicine may work at a higher dose.
- Resistant. The medicine did not stop the growth or kill the bacteria or fungus causing the infection. It would not be a good choice for treatment.

The determination of antibiotic susceptibility of a pathogen is important in selecting the most appropriate one for treating a disease. There are several different procedures used by clinical

microbiologists to determine the sensitivity of microorganisms to antibiotics. Two such procedures are described below.

The first one (the Kirby-Bauer Disc Method) is used to determine which antibiotic is the most effective against a certain pathogen. The second (MIC) is used to determine the lowest concentration that is needed to kill the pathogen at the site of infection.

The Kirby-Bauer Disc Method –

This method is also called the agar diffusion method or the disk diffusion method. The procedure followed is simply that a filter disk impregnated with an antibiotic is applied to the surface of an agar plate containing the organism to be tested and the plate is incubated at 37°C for 24-48 hours.

As the substance diffuses from the filter paper into the agar, the concentration decreases as a function of the square of the distance of diffusion. At some particular distance from each disk, the antibiotic is diluted to the point that it no longer inhibits microbial growth. The effectiveness of a particular antibiotic is shown by the presence of growth-inhibition zones.

These zones of inhibition (ZOIs) appear as clear areas surrounding the disk from which the substances with antimicrobial activity diffused. The diameter of the ZOI can be measured with a ruler and the results of such an experiment constitute an antibiogram.

The agar diffusion method uses commercially available filter paper disks, each containing a defined concentration of a specific antibiotic. The relative effectiveness of different antibiotics provides the basis for a sensitivity spectrum of the organism. This information, together with various pharmacological considerations, is used in the selection of an antibiotic for treatment.

It should be emphasized that chemotherapeutic agents are not chosen simply on the basis of the drug producing the widest ZOI.

This is because of the nature of the growth-inhibition substances. The size of the zone may be affected by the density or viscosity of the culture medium, the rate of diffusion of the antibiotic, the concentration of the antibiotic on the filter disc, the sensitivity of the organism to the antibiotic, and the interaction between the antibiotic and the medium.

In addition, an agent that has been found to have a significant antibiotic effect may not be therapeutically useful because it may also have significant adverse effects in the system for which it is intended. The disk diffusion method represents a simple procedure for screening substances to determine if they have significant antibiotic activity.

The Minimum Inhibitory Concentration (MIC) Method-

The minimum inhibitory concentration (MIC), which is the lowest concentration that still inhibits the growth of a particular organism, can be determined using serial dilution methods. This procedure establishes the concentration of an antibiotic that is effective in preventing the growth of the pathogen and gives an indication of the dosage of that antibiotic that should be effective in controlling the infection in the patient.

A standardized microbial inoculum is added to the tubes containing serial dilutions of an antibiotic, and the growth of the microorganism is monitored as a change in turbidity. In this way, the break point, titer, or minimum inhibitory concentration (MIC) of the antibiotic that prevents growth of the microorganism at the site of infection can be determined.

By knowing the MIC and the theoretical levels of the antibiotics that may be achieved in body fluids, such as blood and urine, the physician can select an appropriate antibiotic, the dosage schedule, and the route of administration. Generally, a margin of safety of ten times the MIC is desirable to ensure successful treatment of the disease. The use of microtiter plates and automated inoculation and reading systems makes the determination of MIC feasible for use in the clinical laboratory. MIC can even be performed on normally sterile body fluids without isolating and identifying the pathogenic microorganisms. For example, blood or cerebrospinal fluid containing an infecting microorganism can be added to tubes containing various dilutions of an antibiotic and a suitable growth medium.

An increase in turbidity would indicate that the microorganism is growing and that the antibiotic at that concentration was ineffective in inhibiting microbial growth. Conversely, a lack of growth would indicate that the pathogenic microorganisms were susceptible to the antibiotic at the given concentration.

III. LABORATORY SUPPLIES

Kirby-Bauer:

Cultures, 4 ml/tt

Staph. aureus -1/table

E. coli 1/table

Jar of 95% Ethanol + forceps 2/table

BHI plates 2/group

Dispenser with antibiotic discs 1 of each kind/table

Sterile Swabs 2/group

MIC:

Cultures, diluted 100 times, 15 ml

Staph. aureus 1/group

E. coli 1/group

TSB (Tryptic Soy Broth), 30 ml/bottle 1/group

Gentamicin, 100 µg/ml, 3 ml 1/group

Tetracycline HCl, 100 µg/ml, 3 ml 1/group

Microwell plates (24 well) 2/group

PROCEDURE –

(Students at each side of a table will form a group. Strict aseptic technique should be followed!) The Kirby-Bauer Disc Method

1. Obtain 2 plates and the cultures of *E. coli* and *Staph. aureus*.
2. Obtain a swab and dip it into the *E. coli* broth culture. Roll the swab against the inside of the tube to remove excess liquid.
3. Streak one of the plates with the swab in even strokes to obtain a uniform growth pattern across the entire surface of the plate. Rotate the plate 90 degrees and using the same swab, streak the plate again. Rotate the plate 45 degrees and reswab. Replace the lid. Discard the swab. Label the plate.
4. Repeat the above procedure for *Staph. aureus* with a new plate.
5. Allow the plates to dry for 2-5 minutes.
6. Remove the forceps from the alcohol beaker and pass through the flame of a bunsen burner. When all the alcohol has burned off, use the sterile forceps to aseptically remove one

of each antibiotic disc from the dispenser and place it on each plate. You can draw pie lines on the back to divide each plate into 6 sections. The antibiotic discs used are: gentamicin, tetracycline, penicillin G, chloramphenicol, ampicillin and erythromycin.

7. Repeat the alcohol-flame sterilization of the forceps and tap each disc gently onto the plate.
8. Replace the lid, and invert the plate. Complete the label at the bottom of plates and incubate at 37°C for 2 days.
9. Record the results by measuring the diameters of the zone of inhibition (ZOI). The data is recorded and interpreted using tables supplied at the introduction section of this lab exercise.

Reading and Interpretation

After incubation, the plates are examined and the diameter of the zones of inhibition is measured to the nearest whole millimeter by use of sliding calipers, a ruler, or a template prepared for this purpose. When supplemented medium is used, the measuring device is held on the back of the petri plate, which is illuminated with reflected light. Zones on blood-containing media are measured at the agar surface. The end point by all reading systems is complete inhibition of growth as determined visually, ignoring faint growth or tiny colonies which can be detected by very close scrutiny. Large colonies growing within the clear zone of inhibition may represent resistant variants or a mixed inoculum and may require reidentification and retesting. The zone diameters for individual antibiotics are translated into prefixed susceptible, intermediate, or resistant .

The Minimum Inhibitory Concentration (MIC) Method

1. Label two titer plates, one for *Staph. aureus* and one for *E. coli*. In both plates, wells A1 to A6 and B1 to B6 are for Tetracycline (T), while wells C1 to C6 and D1 to D6 are for Gentamicin (G). Wells B6 and D6 are controls with no antibiotic.
2. Aseptically add 0.5 ml TSB to all wells except A1 and C1.
3. Aseptically add 0.5 ml tetracycline to wells A1 and A2 and 0.5 ml gentamicin to wells C1 and C2. Serial 2 fold dilutions are prepared in wells 3 through 6 in A and C and wells 1 through 5 in B and D (see the following table). A new pipette should be used for each mixing and transfer but for the sake of economy, you may do all your mixing and transfer with the same pipette.

4. Add 0.5 ml of 100 times diluted culture to each well. Your setup should be as shown in the following table.

5. Incubate 37°C for 2 days.

6. Calculate concentration of antibiotic per ml. The endpoint of the assay is the highest dilution of the antibiotic that is inhibitory for the microbe.

8.5 BACTERIOLOGICAL TESTING OF MILK-

Milk, being a good medium for growth and proliferation of a variety of microorganisms such as –bacteria moulds & yeast and their toxins, needs to be stringently screened before use in order to prevent transmission of these microbes to consumers through milk. The most commonly used tests recommended by FSSAI and the test recommended by this assessment for state and district laboratories are given below:

1 Total plate count or Standard plate count

Total plate count results reflect the number of colonies that can emerge under the given physical and chemical conditions (atmosphere, temperature, pH, available nutrients, and presence of growth inhibitory compounds). Colonies are aggregates of living microbial cells, and hence, the results cannot be compared with those from direct counts. Plate counts underestimate the presence of microorganisms, as quiescent, viable but not culturable, and non-culturable microorganisms are omitted from the count.

Materials Required

- Diluent: 0.1% Peptone or Phosphate buffer (90 or 99 ml, 9 ml)
- Media: Plate count agar (PCA) medium (pH 7.0 at 25° C); autoclaved at 121° C for 15 minutes
- Pestle & mortar, Petri dishes, pipettes, incubator (35° C) & Marker

Procedure

Sampling: Collect the sample randomly from entire lot. According to FSSAI sampling 5 sachets (500 ml) of samples will be collected from entire lot. Sample will be stored at refrigeration temperature (2-7o C) until analysis.

Preparation of the test sample: 100-150 ml of the sample will be poured into the sterile sample bottle from each sachet. Opened sachets will be sealed and kept at refrigeration temperature (2-7o C).

Serial dilution and plating

- 1-Mark the tubes and petri dishes for batch no., sample no., parameter, dilution etc.

- 2- Pipette out 10 or 11 mL of sample from sample bottle into 90 or 99 mL of diluent bottle (1:10 dilution)
- 3- Pipette out 1 mL of diluted sample from 1:10 dilution bottle into 9 mL of diluent tube
- 4- Subsequently go for further dilutions if required by pipetting out from previous dilution into 9 mL of diluent tube
- 5- Pipette out 1 mL from each dilution into respectively marked dilution plates
- 6- Pour the PCA (50°C) medium into the plates and allow it to solidify
- 7- Incubate the plates at $35 \pm 2^\circ\text{C}$ for 48–72 hrs

Counting & Calculation

After incubation, retain dishes containing not more than 300 colonies at two consecutive dilutions. It is necessary that one of these dishes contains at least 15 colonies. Calculate the number N of micro-organisms per millilitre or per gram of product, depending on the case, using the following equation:

$$N = \Sigma C / (n_1 + 0.1n_2)d$$

Where ΣC is the sum of colonies counted on all the dishes retained; n_1 is the number of dishes retained in the first dilution; n_2 is the number of dishes retained in the second dilution; d is the dilution 74 Standard Laboratory Protocol on Testing Milk Samples for Quality & Safety factor corresponding to the first dilution. Round the result calculated to two significant figures. Take as the result the number of micro-organisms per millilitre or per gram of product, expressed as a number between 1.0 and 9.9 multiplied by 10^x where x is the appropriate power of 10.

2-Coliform count-

Coliforms are a group of Gram-negative rod-shaped bacteria that have similar biochemical characteristics and are not a single species of microorganism. They are used to monitor the quality of milk being able to ferment lactose with the production of acid and gas within 48 hr at 35°C and grow with or without oxygen. These are usually present in small number in raw milk. It is a simple test and easy to conduct. Absence of coliforms in 1:100 dilutions in raw milk and in 1:10 dilution of pasteurized milk is accepted as a satisfactory quality. The presence of *E. coli* is a proof that contamination from excreta has occurred.

Materials required

A-1 Medium, EC medium, m-FC medium, Membrane filtration unit; Test tubes/ Sampling bottle; Incubator (37°C and 45°C)

Procedure-1: Single-step procedure

- 1- Dilutions of the sample are inoculated into fermentation tubes of A-1 medium

2- The tubes are first incubated for 3 hrs at 35°C and then transferred to a 44.5°C water bath for an additional 21 hrs of incubation

3- Tubes showing growth plus gas are considered positive for fecal coliforms

Procedure-2: Multiple Fermentation Tube (MFT) Technique

1- Cultures from positive tubes from the Presumptive (total) coliform test are inoculated into fermentation tubes of E. coli medium

2- Incubated at 44.5°C for 24 hrs

3- Tubes showing growth with gas production are considered confirmed positives

Procedure-3: Membrane Filtration (MF) technique

Samples are filtered onto membranes as in the total coliform test; the membranes are placed onto plates of m-FC medium, sealed in water-tight plastic bags, and submerged in a 44.5°C water bath incubator for 24 hrs. Colonies with a characteristic faecal coliform appearance are then counted and faecal coliform density is computed.

3-Escherichia coli (E. coli) count-

Conventional method for the enumeration of E. coli

Media and reagents :

- Lauryl tryptose (LST) broth
- Levine's eosin-methylene blue (L-EMB) agar
- MR-VP broth
- Butterfield's phosphate-buffered water
- Kovacs' reagent, Voges-Proskauer (VP) reagents
- Methyl red indicator ,Violet red bile agar (VRBA)
- Peptone Diluents, 0.1% & Brilliant Green Lactose Bile Broth

Materials

- Test sample
- 1% peptone
- MacConkey broth medium
- MacConkey agar medium
- Eosin methylene blue lactose agar

- Tergitol-7 agar
- Kovac's reagent
- Methyl red
- alpha-naphthol
- Potassium hydroxide
- Incubator
- Pipette

Procedure

- 1- Blend the sample in a sterile blender jar for 2 minutes or macerate with sterile sand in a sterile mortar using approximately 200 mL of diluting fluid per 25 g of the sample
- 2- The diluting fluid for preparing the homogenate should be at 1% peptone (ISO 6887 solution in water
- 3- Inoculate 1 mL of the blended or macerated sample into 10 mL of single strength MacConkey broth medium. If the numbers of organisms are assumed to be very small, inoculate 10 mL of double strength MacConkey broth medium
- 4- Also streak loop full on to MacConkey agar medium, eosin methylene blue lactose agar, and if available Tergitol-7 agar
- 5- Incubate all the inoculated media at 37°C overnight
- 6- If there is growth with fermentation of lactose in the MacConkey broth medium streak out a loop full on to each of the solid media, and incubate at 37°C overnight

Test for Identification:

Pick out and mark as many suspected colonies from the solid media as possible, but not less than 5, to investigate. The suspect colonies are smooth and are lactose fermenting on MacConkey agar and on eosin ethylene blue lactose agar, and are yellow colonies surrounded by yellow zones on Tergitol-7 agar medium.

(1) Test for Indole - Inoculate peptone water medium as in with a loopfull of 24 hour growth in nutrient broth and incubate at 37°C for 48 hours. Add 0.5 ml of Kovac's reagent, prepared by dissolving 10 g p-dimethyl-aminobenzaeldehyde in 150 ml amyl alcohol or isoamyl

alcohol and to which 50 ml of concentrated hydrochloric acid is slowly added. Prepare the reagent in small quantities and store in refrigerator. After adding Kovac's reagent, shake the tube gently, the appearance of a red colour indicates the presence of indole.

(2) Test with Methyl Red- Inoculate the glucose peptone water medium and incubate at 37°C for 2 days. Add 2 drops of methyl red solution prepared by dissolving 0.04 g of methyl red in 40 ml of absolute ethanol and diluting with water to make up to 100 ml. A positive reaction is indicated by red colour and a negative reaction by yellow colour.

(3) Test for Voges-Proskauer Reaction - Inoculate the glucose peptone water medium, and incubate at 37°C for 2 days. To 1 ml of the growth add 0.6 ml of alpha-naphthol solution prepared as 5 percent solution in ethanol. Shake and add 2 ml of 40 percent aqueous solution of potassium hydroxide. Shake and slope the tube and observe for up to 4 hours for the appearance of a pink colour which indicates a positive reaction.

(4) Test for Citrate Utilization- Inoculate the strain on to Simmion's Citrate Agar medium with a young nutrient agar slant culture using a straight wire. Incubate at 37°C for up to 4 days for growth of the organism

Procedure for enumeration:

Preparation of Sample

1- Take 25 to 50 g of the sample in a, sterile blender jar and to this add diluting fluid (0.1% Peptone) to have dilution of 10⁻¹

2- Blend at 8 000 to 10000 rev/min for 2 minutes. Alternatively macerate with the diluting fluid in a sterile mortar with sterile sand, Make serial ten-fold dilutions with the diluting fluid, in duplicate series, up to 10⁻⁶

Plate Count:

1- Spread out 0.1 mL from each dilution tube, evenly on to Tergitol-7 agar, and incubate at 37°C for 24 hours

2- Enumerate the colonies of E. coli, which are yellow in colour surrounded by a yellow zone, and confirm these as being Escherichia coli by IMViC tests

The number of viable colonies of *E. coli* per gram of sample shall be determined by multiplying by the dilution factor(s) and dividing by the mass of the sample. If Tergitol-7 agar is not in use, then MacConkey agar plates or eosin methylene blue lactose agar plates may be used.

8.6 SUMMARY

Microbial experimental evolution uses controlled laboratory populations to study the mechanisms of evolution. The molecular analysis of evolved populations enables empirical tests that can confirm the predictions of evolutionary theory, but can also lead to surprising discoveries. As with other fields in the life sciences, microbial experimental evolution has become a tool, deployed as part of the suite of techniques available to the molecular biologist. Microbial culture media preparation is a routine task in the regular monitoring of spoilage and pathogenic microbes in microbiological testing. Microbial culture media should provide optimal growth conditions for all or specific types of microorganisms.

Bacteria and fungi are grown on or in microbiological media of various types. The medium that is used to culture the microorganism depends on the microorganism that one is trying to isolate or identify. Different nutrients may be added to the medium, making it higher in protein or in sugar. Various pH indicators are often added for differentiation of microbes based on their biochemical reactions. Other added ingredients may be growth factors, NaCl, and pH buffers.

The Kirby-Bauer test for antibiotic susceptibility (also called the disc diffusion test) is a standard that has been used for years. It has been superseded by automated tests, but the K-B is still used in some labs, or used with certain bacteria that automation does not work well with. This test is used to determine the resistance or sensitivity of aerobes or facultative anaerobes to specific chemicals, which can then be used by the clinician for treatment of patients with bacterial infections.

The gram stain, originally developed in 1884 by Christian Gram, is probably the most important procedure in all of microbiology. It has to be one of the most repeated procedures done in any lab. Gram was actually using dyes on human cells, and found that bacteria preferentially bind some dyes. The Gram stain is a differential stain.

In addition to studying the natural history of microbes, it deals with every aspects of microbe-human and environmental interaction. These interactions include: ecology, genetics,

metabolism, infection, disease, chemotherapy, immunology, genetic engineering, industry and agriculture.

8.7 TERMINAL QUESTION AND ANSWER

Q1- writes to procedure of -

- a- Preparation of culture media for bacteria.
- b- Staining of microorganism
- c- Antibiotic sensitivity testing
- d- Bacteriological testing of milk.

REFERENCES-

- 1- Standard laboratory protocol on testing milk samples for quality and safety- Ram pratimlekha et al.
 - 2- www.sigmaaldrich.com
 - 3- www.cliffsnotes.com
 - 4- www.bio.libretext.org.
-



UTTARAKHAND OPEN UNIVERSITY

**Teenpani Bypass Road, Behind Transport Nagar,
Haldwani- 263139, Nainital (Uttarakhand)
Phone: 05946-261122, 261123; Fax No. 05946-264232
Website: www.uou.ac.in; e-mail: info@uou.ac.in
Toll Free No.: 1800 180 4025**